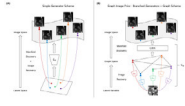


[Advanced Search](#) | [Annual Meeting Job Match](#)

Traditional Poster

AMPC Selected Abstracts

0015



Graph Image Prior for Unsupervised Dynamic MRI Reconstruction

Zhongsen Li¹, Wenxuan Chen¹, Chuyu Liu¹, Puguang Xie², Haozhong Sun¹, Haining Wei¹, Jiachen Ji¹, Jing Zou¹, and Rui Li¹

¹Tsinghua University, Beijing, China, ²School of Medicine, Chongqing University, Chongqing, China

Keywords: AI/ML Image Reconstruction, Machine Learning/Artificial Intelligence, Unsupervised Learning, Image Reconstruction, Dynamic MRI

Motivation: Current unsupervised dynamic-MRI reconstruction algorithms based on DIP uses very low-dimensional latent variables and a single generator for direct non-linear mapping, which may limit the performance.

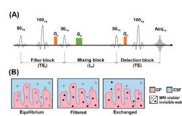
Goal(s): To propose a new model and algorithm for unsupervised dynamic MRI reconstruction.

Approach: We propose a novel Graph-Image-Prior(GIP) model, which uses branched CNN generators to recover the image structure, and use a Graph-Neural-Network(GNN) to discover the best spatio-temporal manifold. Besides, we devise an ADMM algorithm to alternately optimize the dynamic image and network.

Results: The proposed method achieves the state-of-art performance even compared with supervised deep-learning methods, without the need for any fully-sampled data.

Impact: The proposed Graph-Image-Prior(GIP) scheme is a new unsupervised image reconstruction model, which has a significant value for further research. Besides, GIP is promising to be used in other multi-frame MRI reconstruction applications where fully-sampled data is scarce or unavailable.

0030



Relaxation-exchange imaging (REXI) for the measurement of trans-barrier water exchange in choroid plexus

Xuetao Wu^{1,2}, Zejun Wang³, Yu Yin⁴, Qingping He⁵, Yi-Cheng Hsu⁶, Rong Xue^{1,2}, and Ruiliang Bai⁷

¹State Key Laboratory of Brain and Cognitive Science, Beijing MRI Center for Brain Research, Institute of Biophysics, Chinese Academy of Sciences, Beijing, China, ²University of Chinese Academy of Sciences, Beijing, China, ³Key Laboratory of Biomedical Engineering of Ministry of Education, College of Biomedical Engineering and Instrument Science, Zhejiang University, Hangzhou, China, ⁴Department of Chemistry, Zhejiang University, Hangzhou, China, ⁵School of Brain Science and Brain Medicine, Zhejiang University, Hangzhou, China, ⁶MR Collaboration, Siemens Healthcare, Shanghai, China, ⁷Interdisciplinary Institute of Neuroscience and Technology, Zhejiang University School of Medicine, Hangzhou, China

Keywords: Neurofluids, Neurofluids, choroid plexus, Blood-CSF barrier, relaxation exchange

Motivation: Scarcity of non-invasive imaging techniques of choroid plexus function hindered our knowledge of the blood-cerebrospinal fluid barrier (BCSFB).

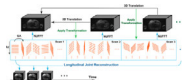
Goal(s): We aimed to measure the trans-barrier water exchange rate in choroid plexus.

Approach: We developed a new imaging method and contrast mechanism, named relaxation-exchange imaging (REXI), and validated its feasibility on both phantoms and rats.

Results: REXI successfully captured the changes in proton exchange rate of urea-water phantoms at varying pH. In-vivo experiments on rats showed the potential of REXI to measure the trans-barrier water exchange in choroid plexus.

Impact: Given the emerging importance of neurofluids and choroid plexus, our novel MRI method REXI provides a way to measure the trans-barrier water exchange in CP and a potential imaging tool to evaluate CP function in future studies.

0041



Accelerating Longitudinal Dynamic MRI by Exploiting Multi-Session Temporal Correlations

Jingjia Chen^{1,2}, Daniel K Sodickson^{1,2}, and Li Feng^{1,2}

¹Bernard and Irene Schwartz Center for Biomedical Imaging, Department of Radiology, New York University Grossman School of Medicine, New York, NY, United States, ²Center for Advanced Imaging Innovation and Research (CAI2R), Department of Radiology, New York University Grossman School of Medicine, New York, NY, United States

Keywords: Image Reconstruction, Image Reconstruction

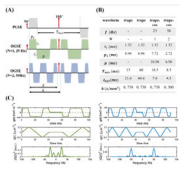
Motivation: Longitudinal MRI scans performed on the same patient offer valuable temporal redundancy that can be exploited for image reconstruction. However, this wealth of information is usually ignored in current clinical practice, with data from different sessions typically reconstructed separately.

Goal(s): This study introduces a longitudinal dynamic MRI framework that leverages temporal correlations across multiple imaging sessions to improve image reconstruction.

Approach: Our reconstruction approach aims to reconstruct multi-session data jointly as a dynamic image series employing a combination of low-rank subspace and spatiotemporal constraints.

Results: The initial results demonstrate that joint longitudinal reconstruction outperforms standard separate reconstructions, which may allow for additional acceleration.

Impact: By exploiting image correlations across multiple sessions, our longitudinal dynamic MRI framework can improve image reconstruction and enable higher acceleration compared to standard separate reconstruction.



Quantifying Cervical Spinal Cord Pathology of Multiple Sclerosis Using Oscillating Gradient Spin-echo DWI

Sisi Li¹, Fan Liu¹, Yi Xiao¹, Diwei Shi², Mangsuo Zhao³, Yuqi Zhang³, Xianchang Zhang⁴, Yishi Wang⁴, Junzhong Xu^{5,6,7}, and Hua Guo¹

¹Center for Biomedical Imaging Research, Department of Biomedical Engineering, Tsinghua University, Beijing, China, ²Center for Nano and Micro Mechanics, Department of Engineering Mechanics, Tsinghua University, Beijing, China, ³Department of Neurology, Yuquan Hospital, School of Clinical Medicine, Tsinghua University, Beijing, China, ⁴MR Research Collaboration Team, Siemens Healthineers Ltd., Beijing, China, ⁵Institute of Imaging Science, Vanderbilt University Medical Center, Nashville, TN, United States, ⁶Department of Radiology and Radiological Sciences, Vanderbilt University Medical Center, Nashville, TN, United States, ⁷Department of Physics and Astronomy, Vanderbilt University, Nashville, TN, United States

Keywords: Microstructure, Diffusion Tensor Imaging, oscillating gradient, diffusion time, spinal cord, multiple sclerosis

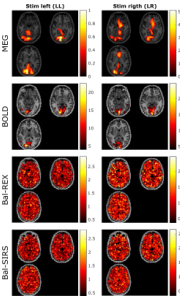
Motivation: Spinal cord MRI has both diagnostic and prognostic value for multiple sclerosis (MS) patients. Several quantitative MRI biomarkers show high sensitivity to characterize MS lesions but lack pathological specificity. Time-dependent DWI may reveal microstructural features and pathological variations in MS.

Goal(s): To explore diffusion time-dependence in the cervical spinal cord and its potential to quantify pathology of MS

Approach: Optimized oscillating gradient spin-echo (OGSE) DTI were performed for healthy volunteers (N=18) and MS patients (N=17).

Results: Diffusivities show time-dependence in the dorsal-columns and lateral-funiculus of healthy controls. The increase of RD in MS lesions is larger than healthy WM when diffusion time decreases.

Impact: The time-dependence of diffusivities in the cervical spinal cord of healthy volunteers and MS patients are observed using optimized OGSE DWI sequences on a clinical scanner. This may reveal further insight into the microstructural differences and pathological variations in MS.



Exploring the sensitivity limits of neuronal current imaging with MRI and MEG in the human brain

Milena Capiglioni¹, Davide Tabarelli², Federico Turco¹, Stefano Tambalo², Roland Wiest¹, and Jorge Jovicich²

¹Institute for Diagnostic and Interventional Neuroradiology, Support Center for Advanced Neuroimaging (SCAN), University of Bern, Bern, Switzerland, ²Center for Mind/Brain Sciences, University of Trento, Rovereto (Trento), Italy

Keywords: Bioeffects & Magnetic Fields, Multimodal, Spin-lock, Pulse sequence design, New Signal Preparation Schemes

Motivation: In-vivo use of Spin-lock (SL) rotary MR saturation contrast, despite encouraging phantom studies, raises questions about its sensitivity and practicality in neural magnetic field imaging.

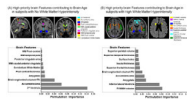
Goal(s): Determine if SL contrast effectively maps human neuronal activation, evaluating its sensitivity and localization against MEG and 3T BOLD-fMRI.

Approach: Thirteen volunteers underwent SL-based scanning during visual stimulation, alongside BOLD and magnetoencephalography, with phantom experiments validating the paradigm and processing pipelines.

Results: Preliminary analysis revealed significant activation in the expected visual region for three subjects in SL contrast maps. Low detection was attributed to sensitivity limits estimated in the phantom, falling below MEG-estimated neural fields.

Impact: We assess Spin-lock 3T MR contrast for human neuronal activation mapping. Promising initial results highlight the need for refinement due to sensitivity limitations in neural field detection, supported by phantom MRI and MEG measures.

0139



Quantitating Neuroanatomic Volumetry and White Matter Hyperintensity Lesion wrapped in AI Model in Aging Cohorts as a determinant of Brain Age

Neha Yadav¹, Niraj Kumar Gupta¹, and Vivek Tiwari¹

¹Department of Biological Sciences, Indian Institute of Science Education and Research Berhampur, Berhampur, India

Keywords: Aging, Aging, Brain Age, Volumetry, White Matter Hyperintensity

Motivation: In an aging population, a subset of individuals at any age group present with low white matter hyperintensity (WMH) volume in the brain, while another subset has intermediate to high WMH load.


Goal(s): To establish a Brain Age Estimation model involving WMH lesion quantification as a clinical indicator of Brain Health.

Approach: We have investigated the 'Brain Health' in terms of Brain Age using neuroanatomic volume, thickness together with WMH load across cognitively normal, impaired and Alzheimer's Disease subjects.

Results: An increased Brain Age gap is observed for the subjects with elevated WMH load compared to the brains with low WMH.

Impact: Brain health is a composite representation of structural, fiber and vascular health. For the first time, a MR based quantitative platform with WMH load and comprehensive neuroanatomic volumetry is established, which estimates 'Brain Age' as an indicator of Brain Health.

0151



Water/fat separated Echo Planar Time-resolved Imaging (EPTI) for efficient distortion-free multi-contrast imaging

Zhangxuan Hu^{1,2}, Zijing Dong^{1,2}, Timothy G. Reese^{1,2}, Lawrence L. Wald^{1,2,3}, Jonathan R. Polimeni^{1,2,3}, and Fuyixue Wang^{1,2}

¹Athinoula A. Martinos Center for Biomedical Imaging, Massachusetts General Hospital, Boston, MA, United States,

²Department of Radiology, Harvard Medical School, Boston, MA, United States, ³Harvard-MIT Division of Health Sciences and Technology, Massachusetts Institute of Technology, Cambridge, MA, United States

Keywords: Fat & Fat/Water Separation, Fat

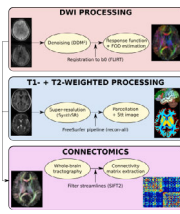
Motivation: Echo Planar Time-resolved Imaging (EPTI) can produce distortion- and blurring-free multi-echo images with high efficiency. For its broader application such as in body imaging, the challenge of fat suppression/separation needs to be addressed.

Goal(s): Achieving efficient water/fat separation using EPTI for high-quality fast multi-contrast/quantitative imaging in the presence of fat tissues.

Approach: In this study, water/fat separated EPTI (WFS-EPTI) was proposed to achieve this by: (1) designing a novel in-phase and out-of-phase EPTI acquisition and encoding scheme; and (2) adopting a k-space-based water/fat separation method.

Results: Experimental results demonstrated the efficacy of WFS-EPTI for water/fat separation and fat-robust distortion-free multi-contrast/quantitative imaging.

Impact: The proposed WFS-EPTI effectively separates water and fat signals, while providing efficient acquisition of high-resolution, distortion-free multi-contrast images and quantitative maps. It can extend EPTI to a broader range of applications.



Connectomics at 64 mT

Álvaro Planchuelo-Gómez^{1,2}, James Gholam¹, Joshua Ametepé¹, Francesco Padormo³, Leandro Beltrachini¹, Mara Cercignani¹, and Derek K Jones¹

¹CUBRIC, Cardiff University, Cardiff, United Kingdom, ²Imaging Processing Laboratory, Universidad de Valladolid, Valladolid, Spain, ³Hyperfine, Inc., Guildford, CT, United States

Keywords: Low-Field MRI, Brain Connectivity, Connectomics

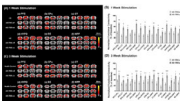
Motivation: Neuroscience MRI research, including assessment of structural connectomics, has been largely limited to high-resource settings.

Goal(s): To democratise assessment of brain connectivity by demonstrating the first ever diffusion-weighted imaging (DWI)-based connectomics at 64 mT.

Approach: 15-direction DWI data were acquired at 64 mT. Whole-brain tractograms were recovered after deep learning based denoising and constrained spherical deconvolution. Whole-brain adjacency matrices and graph-theory parameters were extracted, and their test-retest agreement and variability assessed. For one subject, results were compared to high-field MRI.

Results: Global graph-theory parameters (e.g., small-worldness) showed high test-retest agreement. However, inter-hemispheric connectivity was overestimated at 64 mT compared to high-field results.

Impact: Our unique combinations of low-field (64 mT) diffusion-weighted imaging, denoising, spherical deconvolution and connectomics opens up new research opportunities, allowing the assessment of structural connectivity and network neuroscience studies of under-served populations where this has never previously been possible.



Prolonged Central Thalamic Intermittent Theta-Burst Stimulation Rescued Memory Deficits in Alzheimer's Disease Mouse Model

Yi-Chen Lin¹, Ssu-Ju Li¹, Yu-Chun Lo², Yun-Ting Liu¹, Yi-Chun Lee³, Ting-Chieh Chen¹, Ching-Wen Chang¹, Yao-Wen Liang¹, Ching-Te Chen⁴, Sheng-Huang Lin^{5,6}, and You-Yin Chen^{1,2}

¹Department of Biomedical Engineering, National Yang Ming Chiao Tung University, Taipei, Taiwan, ²PhD Program in Medical Neuroscience, College of Medical Science and Technology, Taipei Medical University, Taipei, Taiwan, ³School of Medicine, College of Medicine, National Yang Ming Chiao Tung University, Taipei, Taiwan, ⁴Abbott Neuromodulation, Austin, TX, United States, ⁵Department of Neurology, Hualien Tzu Chi Hospital, Buddhist Tzu Chi Medical Foundation, Hualien, Taiwan, ⁶Department of Neurology, School of Medicine, Tzu Chi University, Hualien, Taiwan

Keywords: Alzheimer's Disease, Alzheimer's Disease, Intermittent theta-burst stimulation (iTBS)

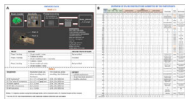Motivation: Addressing the global AD crisis by investigating CT-iTBS as a non-pharmacological treatment to enhance memory and cognition.

Goal(s): To explore the therapeutic efficacy and determine the optimal treatment protocol of CT-iTBS in AD while unveiling its potential underlying mechanism for enhancing memory and cognitive functions.

Approach: Utilized brain magnetic resonance imaging analysis, behavioral tests, and immunofluorescence staining for assessing the therapeutic effect of different durations of CT-iTBS treatment.

Results: Prolonged CT-iTBS significantly enhanced cognitive and memory behaviors, altered brain functional connectivity, promoted a neuroprotective effect, and reduced amyloid accumulation in AD mouse model. These findings present a promising therapeutic avenue for AD patients.

Impact: Our findings revealed a highly promising avenue for enhancing the quality of life for individuals with AD and provided insights into the potential underlying neuroprotective mechanisms of CT-iTBS in alleviating memory deficits.



The first MR Electrical Properties Tomography (MR-EPT) reconstruction challenge: preliminary results of simulated data

Stefano Mandija^{1,2}, Alessandro Arduino^{*3}, Cornelis A.T. van den Berg^{*1,2}, Patrick Fuchs^{*4}, Ilias Giannakopoulos^{*5}, Yusuf Ziya Ider^{*6}, Kyu-Jin Jung^{*7}, Ulrich Katscher^{*8}, Dong-Hyun Kim^{*7}, Riccardo Lattanzi^{*5,9}, Thierry G. Meerbothe^{*1,2}, Khin-Khin Tha^{*10}, and Luca Zilberti^{*3}

¹Department of Radiotherapy, University Medical Center Utrecht, Utrecht, Netherlands, ²Computational Imaging Group for MR Therapy and Diagnostics, University Medical Center Utrecht, Utrecht, Netherlands, ³Istituto Nazionale di Ricerca Metrologica (INRiM), Torino, Italy, ⁴Department of Medical Physics and Biomedical Engineering, University College London, London, United Kingdom, ⁵The Bernard and Irene Schwartz Center for Biomedical Imaging, Department of Radiology, New York University Grossman School of Medicine, New York, NY, United States, ⁶Department of Biomedical Engineering, Baskent University, Ankara, Turkey, ⁷Department of Electrical and Electronic Engineering, Yonsei University, Seoul, Korea, Republic of, ⁸Philips Research Hamburg, Hamburg, Germany, ⁹Center for Advanced Imaging Innovation and Research (CAI2R), Department of Radiology, New York University Grossman School of Medicine, New York, NY, United States, ¹⁰Hokkaido University Faculty of Medicine, Hokkaido, Japan

Keywords: Electromagnetic Tissue Properties, Electromagnetic Tissue Properties, Conductivity

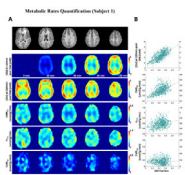
Motivation: To benchmark MR-Electrical Properties Tomography (MR-EPT) reconstruction methods.

Goal(s): To present an overview of the first MR-EPT reconstruction challenge participation and the results of its phase 1.

Approach: The challenge consisted of 3 phases:1) reconstructions from a simulated (blind) dataset (ground-truth EPs not provided);2) reconstructions from several simulated dataset (ground-truth EPs provided for few training dataset for tuning algorithm parameters);3) EPs reconstructions from measured data.

Results: 52 participants registered to the challenge; 39 submitted their results. For phase 1, all participants submitted a reconstructed conductivity map; 12 submitted a reconstructed permittivity map. The results show large variability in reconstruction accuracy and precision.

Impact: The results of phase 1 of the first MR-EPT reconstruction challenge show large variations in the estimated conductivity and permittivity maps demonstrating the need of benchmarking reconstruction methods on common datasets.



Mapping oxidative and non-oxidative glucose metabolic rates of entire human brain using quantitative dynamic deuterium MRS imaging at 7T

Xin Li¹, Xiao-Hong Zhu¹, and Wei Chen¹

¹Center for Magnetic Resonance Research, University of Minnesota, Minneapolis, MN, United States

Keywords: Deuterium, Deuterium, Glucose Metabolic Rates

Motivation: Cerebral glucose metabolism *via* non-oxidative and oxidative pathways is critical for brain function, however, methods capable of quantitatively imaging metabolic rates are lacking.

Goal(s): To develop a quantitative dynamic deuterium (²H) MRSI (DMRSI) method capable of mapping human brain glucose metabolic rates.

Approach: Combining novel hardware and advanced post-processing method with kinetic models, we established a high-resolution, high-quality dynamic DMRSI capable of quantifying and imaging three metabolic rates of glucose consumption (CMR_{Glc}), lactate generation (CMR_{Lac}) and TCA cycle (V_{TCA}) in human brain at 7T.

Results: We demonstrate consistent whole-brain maps of CMR_{Glc}, CMR_{Lac}, V_{TCA} in health subjects.

Impact: We developed a novel DMRSI platform on an FDA-approved clinical 7T scanner that enables simultaneous high-resolution imaging of CMR_{Glc}, CMR_{Lac} and V_{TCA} of entire human brain for the first time. This novel technology has potential for brain research and translation.



NeuroLibre: Living MRI preprints with built-in support for code review

Agah Karakuzu¹, Elizabeth DuPre², Patrick Bermudez³, Mathieu Boudreau¹, Rachel Harding⁴, Jean-Baptiste Poline³, Samir Das³, Pierre Bellec⁵, and Nikola Stikov¹

¹NeuroPoly Lab, Polytechnique Montreal, Montreal, QC, Canada, ²Department of Psychology, Stanford University, San Francisco, CA, United States, ³The Neuro, McGill Centre for Integrative Neurosciences MCIN, Montreal, QC, Canada, ⁴Structural Genomics Consortium, University of Toronto, Toronto, ON, Canada, ⁵CRIUGM, University of Montreal, Montreal, QC, Canada

Keywords: Software Tools, Software Tools


Motivation: The ISMRM community is swiftly adopting data sharing and code review. While the advantages are clear, challenges persist in ensuring the quality and functionality of these shared resources.

Goal(s): To establish a platform for simplifying technical (or code) reviews and generating open-source living preprints with interactive data apps (e.g., dashboards).

Approach: We created NeuroLibre.org, offering dedicated cloud resources for hosting living preprints that combine narrative and executable content.

Results: NeuroLibre has published 8 living preprints, covering a variety of MRI applications. Each preprint is registered as citable and online-executable content with DOI links to archived reproducibility objects (code, runtime, data).

Impact: Our living preprints showcase how NeuroLibre helps reviewers interactively assess the quality and functionality of reproducibility objects effortlessly, bolstering the reproducibility of MRI publications. The ISMRM 2020 reproducibility challenge is our flagship example: <https://doi.org/10.55458/neurolibre.00014>



Predicting Pathogenic DNA Damage Repair Gene Mutations in Prostate Cancer Patients: A Multi-Center MRI Radiomics Study

Enyu Yuan¹, Yuntian Chen¹, Lei Ye¹, Jin Yao¹, and Bin Song¹

¹Department of Radiology, West China hospital, Chengdu, China

Keywords: Prostate, Prostate

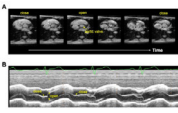
Motivation: Pathogenic DDR gene alterations are associated with aggressive disease and poor outcomes among prostate cancer (PCa) patients.

Goal(s): To develop a radiomics-based pre-testing model for identifying DDR mutation carriers among PCa patients.

Approach: A total of 225 patients from three centers with both multiparameter MRI and genetic DDR mutations testing were included. Radiomic models were established based on T2WI and ADC sequences of MRI images. The predictive values were validated in both internal and external validation cohorts.

Results: The radiomics-based model exhibited an AUC of 0.835 in the training dataset, 0.824 in the internal validation dataset, and 0.836 in the external validation dataset.

Impact: In the current study, we introduced a noninvasive radiomics feature-based tool designed to predict pDDRg mutations in prostate cancer patients. External validation of the novel tool by datasets from other medical centers revealed a high predictive accuracy for pDDRg mutations.



Accuracy of Measuring Opening and Closing Characteristics of the Aortic Valve with SPEEDI MRI

Qingfei Luo¹, Yosman Dhar^{1,2}, Alessandro Scotti¹, and Xiaohong Joe Zhou^{1,3}

¹Center for Magnetic Resonance Research, University of Illinois at Chicago, Chicago, IL, United States, ²College of Medicine, University of Illinois at Chicago, Chicago, IL, United States, ³Departments of Radiology, Neurosurgery, and Biomedical Engineering, University of Illinois at Chicago, Chicago, IL, United States

Keywords: Valves, Valves, SPEEDI, sub-millisecond, high temporal resolution

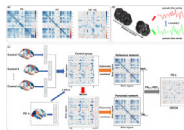
Motivation: get-SPEEDI, a recently published pulse sequence, offers a promising MRI technique for imaging the rapid dynamics of the aortic valve (AV) opening and closing with sub-millisecond temporal resolution.

Goal(s): This study aims to assess the accuracy of measuring the AV dynamics with get-SPEEDI by comparing its performance with transthoracic ultrasound, which is the gold standard clinically.

Approach: Ultrasound echocardiograms and get-SPEEDI MR images of AV were acquired in healthy human subjects with 0.6- and 0.8-ms temporal resolution, respectively.

Results: There were no statistically significant differences between get-SPEEDI and ultrasound in the measurements of AV opening and closing dynamics and the maximum AV area.

Impact: The dynamic characteristics of the aortic valve measured with get-SPEEDI MRI agree well with the ultrasound measurements. get-SPEEDI MRI provides a new imaging tool for diagnosis of aortic valve diseases.



Brain iron accumulation kinetics in Parkinson's disease revealed by relaxometry network and susceptibility-weighted imaging

Weizhao Lu¹, Tianbin Song¹, and Jie Lu²

¹Xuanwu Hospital, Capital Medical University, Beijing, China, ²Xuanwu Hospital Capital Medical University, Beijing, China

Keywords: Parkinson's Disease, Parkinson's Disease, susceptibility-weighted imaging; kinetics; iron accumulation; relaxometry covariance network; substantia nigra

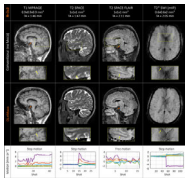
Motivation: Iron deposition is implicated in the pathogenesis of Parkinson's disease (PD). However, most of the previous studies failed to report progressive iron accumulation with disease progression.

Goal(s): This study aimed to explore the kinetics of iron accumulation in the PD brain using a novel relaxometry covariance network (RCN) approach.

Approach: The RCN approach consisted of three steps, the identification of brain regions as propagators of iron, construction of causal RCN and individual differential RCN.

Results: The left substantia nigra pars reticulata, left substantia nigra pars compacta, and lobule VII of cerebellum vermis were identified as propagators of iron.

Impact: The application of our novel relaxometry covariance network on susceptibility-weighted imaging revealed iron accumulation kinetics in Parkinson's disease, which were closely related to the pathophysiological aspects of the disease. The current findings deserved further exploration to elucidate the underlying mechanisms.



Integrating scout and guidance line-based retrospective motion correction into a 3D deep learning reconstruction for fast and robust brain MRI

Daniel Polak¹, Marcel Dominik Nickel¹, Daniel Nicolas Splitthoff¹, Jeanette Deck¹, Bryan Clifford², Yantu Huang³, Wei-Ching Lo², Susie Y. Huang⁴, John Conklin⁴, Lawrence L. Wald⁵, and Stephen F. Cauley²

¹Siemens Healthineers, Erlangen, Germany, ²Siemens Medical Solutions, Boston, MA, United States, ³Siemens Shenzhen Magnetic Resonance Ltd., Shenzhen, China, ⁴Massachusetts General Hospital, Boston, MA, United States, ⁵A. A. Martinos Center for Biomedical Imaging, Boston, MA, United States

Keywords: Alzheimer's Disease, MR Value

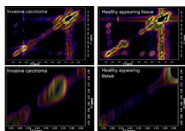
Motivation: Rising medical imaging utilization and increasing use of automated support systems demand high-quality, fast, and reproducible/robust MRI techniques. Despite rapid scanning afforded by deep learning, motion remains a common source of artifacts.

Goal(s): Integrate retrospective motion correction into a deep learning reconstruction to facilitate high-quality, fast, and motion-robust brain imaging.

Approach: Scout and guidance line-based motion correction was implemented into MPRAGE, SPACE and SWI to enable rapid motion trajectory estimation. A data-consistency driven neural network reconstruction was adapted to perform network regularized motion correction.

Results: Improved SNR and reduced motion artifacts are demonstrated *in vivo* using 4-6-fold accelerated scans with instructed subject motion.

Impact: Retrospective motion correction was integrated into a deep learning reconstruction to facilitate fast and motion-robust 3D brain imaging across T1, T2, T2 FLAIR and T2*/SWI. This should add clinical value to routine brain exams and emerging neuro-degenerative screening protocols (ARIA).



NORMAL APPEARING BREAST TISSUE ON BREAST MRI HAS ALTERED CHEMISTRY CONSISTENT WITH "SWITCHED-ON" STATES IN WOMEN WITH INVASIVE CARCINOMA

Carolyn Mountford^{1,2}, Darren Lukas^{1,2}, Natali Naude¹, Jeremy Khoo³, Gorane Santamaria Hormaechea^{1,4}, John Irvine^{1,2}, Thomas Lloyd³, Ian Bennett³, David Clark⁵, Randell Brown⁶, Lisa Rich¹, Laurie Kear¹, and Peter Malycha^{1,7}

¹Griffith University, Southport, Australia, ²Datchem Pty Ltd, Brisbane, Australia, ³Princess Alexandra Hospital, Woolloongabba, Australia, ⁴Radiology, Princess Alexandra Hospital, Woolloongabba, Australia, ⁵The Breast Centre, Gateshead, Australia, ⁶Jones Radiology, Adelaide, Australia, ⁷Datchem, Brisbane, Australia

Keywords: Breast, Spectroscopy, lipids, cholesterol

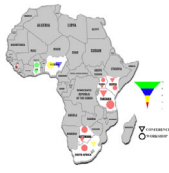Motivation: Adenoma-carcinoma cell models examined using 2D COSY recorded altered triglyceride, cholesterol and metabolites prior to malignant transformation.

Goal(s): Investigate if such chemical profiles are recorded *in vivo* in MRI apparently normal tissue in women with invasive cancer.

Approach: Nineteen women with invasive breast cancer were compared with healthy low risk controls.

Results: Compared to controls, MRI normal tissue in cancer patients with low-density breasts recorded increases in cross peak F (68%), cholesterol (127%), and tumor promotor UDP-GlcNAc (81%). For dense breasts, increases recorded in cross peak F (47%), decreases in cholesterol (12%), triglyceride (56%) and double bonds (40%) in "switched-on" tissue.

Impact: Altered chemistry states, consistent with mechanisms leading to development of invasive carcinoma, are recorded *in vivo* from breast tissue distant to the cancer compared to controls. These states are referred to as "switched-on" tissue and differ according to breast density.



MRI advancement and research in Africa: Report on the Inaugural ISMRM African Chapter conference

Johnes Obungoloch¹, Adesola Emmauel Adepoju², Petronella Samuels^{3,4}, Mary-Jane Orevaoghene Amadi⁵, Segun Joseph Ayilara⁶, Mary Kamuzora⁷, Klenam Dzefi-Tetty⁸, Anthonia A Ikpeme⁹, Frances Robertson³, Udunna Anazodo¹⁰, Chip Truwit¹¹, Farouk Dako¹², Andrew Webb¹³, Yaw B Mensah⁸, Iris Asllani^{14,15}, Ernesta Meintjes^{3,16}, and Godwin Ogbole²

¹Mbarara University of Science and Technology, Mbarara, Uganda, Mbarara, Uganda, ²Department of Radiology, College of Medicine, University of Ibadan, Ibadan, Nigeria, ³Biomedical Engineering Research Centre, Division of Biomedical Engineering, University of Cape Town, South Africa, Cape Town, South Africa, ⁴Department of Human Biology, Faculty of Health Sciences, University of Cape Town, South Africa, CapeTown, South Africa, ⁵Rivers State University Teaching Hospital, Port Harcourt, Nigeria, ⁶Department of Radiology, University College Hospital, Ibadan, Nigeria, ⁷Department of Radiology, Muhimbili National Hospital-Mloganzila, Dar-es-salaam, Tanzania, ⁸Department of Radiology, Korle Bu Teaching Hospital, Accra, Ghana, ⁹Department of Radiology, University of Calabar teaching Hospital, Calabar, Nigeria, ¹⁰Montreal Neurological Institute, McGill University, Montreal, QC, Canada, ¹¹Hyperfine Inc, St. Guilford, CT, United States, ¹²Perelman School of Medicine, University of Pennsylvania, Philadelphia, PA, United States, ¹³C. J. Gorter MRI Center, Department of Radiology, Leiden University Medical Center, Leiden, Netherlands, ¹⁴Clinical Imaging Science Centre, University of Sussex,, Sussex, United Kingdom, ¹⁵Department of Biomedical Engineering, Rochester Institute of Technology, Rochester, NY, United States, ¹⁶Cape Universities Body Imaging Centre, University of Cape Town, CapeTown, South Africa

Keywords: Low-Field MRI, Low-Field MRI, Networking, Innovation

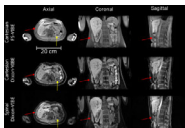
Motivation: Due to rising non-communicable diseases, limited MRI accessibility, and Africa's underrepresentation in ISMRM, the African Chapter (AC) was founded in 2023. An inaugural conference in Ghana focused on emerging MRI technology for improved accessibility.

Goal(s): To provide the inaugural conference report of AC-ISMRM, with the identification of challenges and barriers to MRI access and propose solutions toward democratization of MRI across Africa.

Approach: A white paper approach was adopted

Results: Over 100 scientists from 12 African countries met to identify challenges and propose solutions for advancing MRI access and value in Africa. Low-field MRI was identified as a breakthrough innovation toward this goal.

Impact: The AC-ISMRM conference marks a pioneer event, convening African scientists and clinicians, aimed at establishing a network dedicated to rectify Africa's underrepresentation in MRI research, seeking solutions to challenges on the continent and promoting collaboration and MRI advancements



Spiral T1w-Dixon-VIBE for high resolution abdominal imaging at 0.55T

Bilal Tasdelen¹, Nam G. Lee¹, Sophia X. Cui², and Krishna S Nayak¹

¹Electrical and Computer Engineering, University of Southern California, Los Angeles, CA, United States, ²Siemens Medical Solutions USA, Los Angeles, CA, United States

Keywords: Liver, Low-Field MRI, Spiral, Dixon, abdomen

Motivation: Breath-held abdominal fat-suppressed imaging is challenging at mid- and low-field strengths (<1.5T). Fat saturation often fails due to the short T1 of lipid; and Cartesian Dixon imaging provides poor spatial resolution due to the need for long ΔTE, due to the smaller Δf between water and lipid.

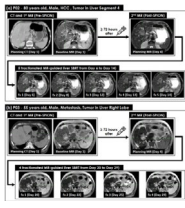
Goal(s): Breath-held fat-suppressed high-resolution volumetric abdominal imaging with T1 contrast.

Approach: Stack-of-Spirals Dixon imaging, with estimation and compensation for phase due to concomitant fields

Results: We demonstrate that spiral Dixon imaging at 0.55T makes excellent use of the required ΔTE, improving SNR efficiency and spatial resolution (1.7x1.7x5.0mm³) compared Cartesian Dixon (3.5x3.5x5.0mm³), within a 17-second breath-hold.

Impact: We demonstrate that spiral Dixon single breath-hold volumetric imaging is an attractive alternative to existing Cartesian-based methods for volumetric single breath-hold fat-suppressed imaging at 0.55T, as it simultaneously provides high-resolution and excellent fat-suppression.

0447



Super-paramagnetic iron oxide nanoparticles improve liver tumor visualization throughout online MRI-guided liver stereotactic radiotherapy

Danny Lee¹, Seungjong Oh¹, and Alexander Kirichenko¹

¹Radiation Oncology, Allegheny Health Network, Pittsburgh, PA, United States

Keywords: MR-Guided Radiotherapy, Radiotherapy, MRI-guided radiotherapy;

Motivation: Can we provide superior liver tumor visualization for online adaptive planning? MRI enables direct visualization of tumor and organs-at-risk (OAR). However, MRI contrast agents are often required to differentiate primary and metastatic liver malignant lesions from functional hepatic parenchyma.

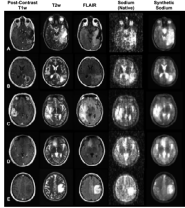
Goal(s): We employed super-paramagnetic iron oxide nanoparticles (SPION) as an MRI contrast agent.

Approach: SPION enhanced the liver-to-tumor contrast ration for rapid and accurate delineation of tumors and functional hepatic parenchyma throughout the entire treatment course.

Results: This study is the first to report the efficiency of a single SPION injection for multi-fractionated MRI-guided liver stereotactic body radiotherapy on a 1.5T Elekta MR-Linac.

Impact: A single SPION injection significantly improved the tumor-to-liver contrast, and it was maintained throughout multi-fraction MRI-guided liver SBRT to provide rapid and accurate contouring tumor lesions from functional liver parenchyma for online adaptive planning.

0504



High-Resolution Sodium MRI of Human Gliomas at 3T Using Physics-Based Generative AI

Catalina Raymond¹, Thorsten Feiweier², Bryan Clifford³, Heiko Meyer², Xiaodong Zhong⁴, Fei Han³, Alfredo L. Lopez Kolkovsky¹, Nicholas S. Cho¹, Francesco Sanvito¹, Sonoko Oshima¹, Noriko Salamon⁵, Richard Everson⁶, Timothy F. Cloughesy⁷, and Benjamin M. Ellingson^{1,4,6}

¹Radiological Sciences, UCLA Brain Tumor Imaging Laboratory, Los Angeles, CA, United States, ²Siemens Healthcare GmbH, Erlangen, Germany, ³Siemens Medical Solutions USA, Boston, MA, United States, ⁴Radiological Sciences, Magnetic Resonance Research Laboratories, David Geffen School of Medicine, University of California Los Angeles, Los Angeles, CA, United States, ⁵Radiological Sciences, David Geffen School of Medicine, University of California, Los Angeles, CA, United States, ⁶Neurosurgery, David Geffen School of Medicine, University of California, Los Angeles, CA, United States, ⁷Neurology, David Geffen School of Medicine, University of California, Los Angeles, CA, United States

Keywords: Tumors (Post-Treatment), Non-Proton, Sodium

Motivation: Sodium MRI is a promising technique for understanding the brain tumor microenvironment. However, sodium MRI at 3T suffers from extremely low SNR, resulting in compromised resolution and long acquisition times.

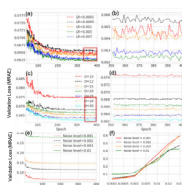
Goal(s): Our goal is to create a high-resolution sodium MRI at 3T using generative AI to improve biological characterization, treatment monitoring, and surgical planning for brain tumor patients.

Approach: We developed a physics-informed synthetic dataset to train an anatomically-constrained GAN for high-resolution neuroimaging of brain tumors.

Results: When applied to brain tumor patients' images, the synthetic-sodium MRI improved resolution, SNR, and correlated with expression of sodium-proton exchanger (NHE1) on image-guided biopsy.

Impact: High-resolution sodium neuroimaging at 3T using physics-informed anatomically-constrained GAN has the potential to make multinuclear MRI feasible in the clinical environment, leading to conceivable improvements in diagnosis, monitoring, treatment, and our understanding of the biology of brain tumors.

0516



Fine-Tuning Deep Learning Model For Quantitative Knee Joint Mapping with MR Fingerprinting

Xiaoxia Zhang^{1,2}, Marcelo V.W. Zibetti^{1,2}, Hector L.de Moura^{1,2}, Anmol Monga^{1,2}, and Ravinder R. Regatte^{1,2}

¹Bernard and Irene Schwartz Center for Biomedical Imaging, Department of Radiology, New York University Grossman School of Medicine, New York, NY, United States, ²Center for Advanced Imaging Innovation and Research (CAI2R), Department of Radiology, New York University Grossman School of Medicine, New York, NY, United States

Keywords: Cartilage, MR Fingerprinting, Knee cartilage, Deep learning

Motivation: Estimating MRF quantitative parameters with neural networks (NNs) is faster than dictionary-matching methods (DMs), and it has the advantage of providing continuously distributed parameters.

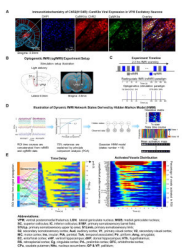
Goal(s): We investigate different aspects of NN training and evaluate its quantitative MRF performance and compare them with DMs.

Approach: We exploit how training data sizes, noise levels, and SVD compression sizes affect the MRF performance of the NNs and compare them with DMs.

Results: The NN provides a faster way of multi-parametric mapping from NIST/ISMRM phantom and knee joint MRF data sets with comparable performance to DMs.

Impact: Well-tuned NN is much more efficient for quantitative MRF, particularly for the knee joint. Besides computational speed, fine-tuning can also increase the performance and robustness to noise.

0530



Single-pulse optogenetic perturbation of thalamo-cortical networks reveals functional architecture of rsfMRI networks

Linshan Xie^{1,2}, Xunda Wang^{1,2}, Xuehong Lin^{1,2}, Teng Ma^{1,2,3}, Junjian Wen^{1,2}, Peng Cao³, Alex T L Leong^{1,2}, and Ed X Wu^{1,2,4}

¹Laboratory of Biomedical Imaging and Signal Processing, The University of Hong Kong, Hong Kong SAR, China, ²Department of Electrical and Electronic Engineering, The University of Hong Kong, Hong Kong SAR, China, ³Department of Diagnostic Radiology, The University of Hong Kong, Hong Kong SAR, China, ⁴School of Biomedical Sciences, The University of Hong Kong, Hong Kong SAR, China

Keywords: Functional Connectivity, fMRI (resting state), functional connectivity, neuroscience, brain connectivity

Motivation: A current overarching challenge in neuroscience is to establish an integrated understanding of brain circuits and networks, particularly the interactions of neural populations across various spatiotemporal scales that give rise to functions and behavior.

Goal(s): We posit that dissecting rsfMRI dynamics under direct single-pulse optogenetic modulation of thalamo-cortical networks will reveal critical insights into the functional architecture of rsfMRI networks.

Approach: We deployed a computational approach (i.e., Gaussian PCA-HMM) to examine the organization of rsfMRI networks before and upon single-pulse stimulation of thalamus.

Results: We demonstrated a significant role of the basal forebrain and hypothalamus in regulating the transient dynamics of rsfMRI networks.

Impact: The ability to directly perturb and model dynamics of rsfMRI networks present an unprecedented opportunity to understand brain-wide and higher-order circuits/networks, and their functions, which are difficult to probe using traditional behavioral and/or cognitive tasks and other neuroimaging approaches.


```

ID:
ImageName:
Study:
DICOMQC version:
DICOMQC status:
DICOMQC error:
DICOMQC warning:
DICOMQC info:
DICOMQC debug:
DICOMQC trace:
DICOMQC log:
DICOMQC output:
DICOMQC input:
DICOMQC path:
DICOMQC url:
DICOMQC user:
DICOMQC password:
DICOMQC host:
DICOMQC port:
DICOMQC timeout:
DICOMQC retries:
DICOMQC verbose:
DICOMQC quiet:
DICOMQC help:
DICOMQC version:
DICOMQC status:
DICOMQC error:
DICOMQC warning:
DICOMQC info:
DICOMQC debug:
DICOMQC trace:
DICOMQC log:
DICOMQC output:
DICOMQC input:
DICOMQC path:
DICOMQC url:
DICOMQC user:
DICOMQC password:
DICOMQC host:
DICOMQC port:
DICOMQC timeout:
DICOMQC retries:
DICOMQC verbose:
DICOMQC quiet:
DICOMQC help:

```

Automated Quality Control for Multi-Vendor, Multi-Centre Renal Imaging Studies

Alexander J Daniel¹, Martin Craig^{1,2}, David L Thomas^{3,4,5}, Iosif Mendichovszky^{6,7}, Steven Sourbron⁸, David M Morris⁹, Andrew N Priest^{6,7}, Charlotte E Buchanan¹, and Susan T Francis^{1,2}

¹Sir Peter Mansfield Imaging Centre, University of Nottingham, Nottingham, United Kingdom, ²NIHR Nottingham Biomedical Research Centre, Nottingham University Hospitals NHS Trust and the University of Nottingham, Nottingham, United Kingdom, ³Neuroradiological Academic Unit, UCL Queen Square Institute of Neurology, University College London, London, United Kingdom, ⁴Dementia Research Centre, UCL Queen Square Institute of Neurology, University College London, London, United Kingdom, ⁵Wellcome Centre for Human Neuroimaging, UCL Queen Square Institute of Neurology, University College London, London, United Kingdom, ⁶Department of Radiology, Addenbrooke's Hospital, Cambridge, United Kingdom, ⁷Department of Radiology, University of Cambridge, Cambridge, United Kingdom, ⁸Department of Infection, Immunity and Cardiovascular Disease, University of Sheffield, Sheffield, United Kingdom, ⁹Centre for Cardiovascular Science, University of Edinburgh, Edinburgh, United Kingdom

Keywords: Software Tools, Software Tools, Standardisation, Quality Control

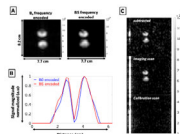
Motivation: It is critical that MRI data acquired in multi-site, multi-vendor studies conforms to a standardised acquisition protocol.

Goal(s): To develop XNAT tools to highlight scans that do not conform to a specified protocol or are of insufficient quality, enabling rapid correction of errors before future scans.

Approach: Multi-site DICOM data is uploaded to XNAT after acquisition, by integrating software tools with this database, investigators are informed if data does not conform.

Results: DICOM-QC, a tool to automatically compare DICOM metadata to predefined values, and ImageSNR-QC to calculate image SNR, applied here to a multi-site kidney study.

Impact: This work outlines two tools that integrate with XNAT, DICOM-QC and ImageSNR-QC, which can be used by any investigators running large studies to ensure uploaded data conforms to the study protocol, ensuring consistency over sites, vendors, and repeated longitudinal scans.



Gradient-Free Frequency Encoded MRI

Sai Abitha Srinivas¹, Antonio D Glenn², Christopher E Vaughn³, Mark A Griswold⁴, and William A Grissom¹

¹Biomedical Engineering, Case Western Reserve University, Cleveland, OH, United States, ²Computer Science, University of Washington, Seattle, WA, United States, ³Biomedical Engineering, Vanderbilt University, Nashville, TN, United States, ⁴Radiology, Case Western Reserve University, Cleveland, OH, United States

Keywords: New Trajectories & Spatial Encoding Methods, Data Acquisition, low-field MRI, RF encoding, New spatial encoding, Bloch Siegert shift, STAR

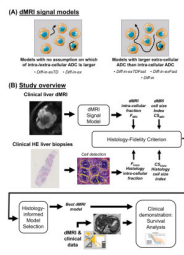
Motivation: Eliminating conventional gradients can help miniaturize and lower costs of MRI significantly. No method using RF-gradients has been able to achieve frequency encoding, the fastest encoding mechanism in MRI.

Goal(s): Develop a Simultaneous-Transmit-and-Receive (STAR) system and perform RF Frequency encoding using the Bloch Siegert shift.

Approach: A novel injection transformer, 2MHz/47.5mT RF coil setup and pulse sequence was developed to enable STAR to prevent the RF encoding signal from overwhelming the receiver while frequency encoding MR signal without conventional gradients.

Results: The novel STAR system achieved 99.75% cancellation of RF encoding signal, enabling the first-ever acquisition of frequency encoded MR images using RF-gradients.

Impact: We have demonstrated, for the first time ever, frequency encoded MRI using RF field gradients in place of conventional B_0 gradients. This is a fundamental requirement to make RF encoded-MR imaging as fast as conventional gradient encoding.



Histology-informed biophysical diffusion MRI model selection for enhanced liver cancer immunotherapy assessment

Francesco Grussu¹, Kinga Bernatowicz¹, Marco Palombo^{2,3}, Caterina Tozzi¹, Sara Simonetti^{4,5}, Garazi Serna⁴, Athanasios Grigoriou^{1,6}, Anna Voronova^{1,6}, Valezka Garay⁷, Juan Francisco Corral^{8,9}, Marta Vidorreta¹⁰, Pablo García-Polo García¹¹, Xavier Merino^{8,9}, Richard Mast^{8,9}, Núria Roson^{8,9}, Manuel Escobar^{8,9}, Maria Vieito^{12,13}, Rodrigo Toledo¹⁴, Paolo Nuciforo⁴, Elena Garralda¹⁵, and Raquel Perez-Lopez¹

¹Radiomics Group, Vall d'Hebron Institute of Oncology, Vall d'Hebron Barcelona Hospital Campus, Barcelona, Spain, ²Cardiff University Brain Research Imaging Centre (CUBRIC), School of Psychology, Cardiff University, Cardiff, United Kingdom, ³School of Computer Science and Informatics, Cardiff University, Cardiff, United Kingdom, ⁴Molecular Oncology Group, Vall d'Hebron Institute of Oncology, Vall d'Hebron Barcelona Hospital Campus, Barcelona, Spain, ⁵Prostate Cancer Translational Research Group, Vall d'Hebron Institute of Oncology, Vall d'Hebron Barcelona Hospital Campus, Barcelona, Spain, ⁶Department of Biomedicine, Faculty of Medicine and Health Sciences, University of Barcelona, Barcelona, Spain, ⁷PET/MR Unit, CETIR-Aspires, Barcelona, Spain, ⁸Department of Radiology, Hospital Universitari Vall d'Hebron, Barcelona, Spain, ⁹Institut de Diagnòstic per la Imatge (IDI), Barcelona, Spain, ¹⁰Siemens Healthineers, Madrid, Spain, ¹¹GE HealthCare, Madrid, Spain, ¹²GU, Sarcoma and Neuroncology Unit, Hospital Universitari Vall d'Hebron, Barcelona, Spain, ¹³Drug Development Unit, Vall d'Hebron Institute of Oncology, Vall d'Hebron Barcelona Hospital Campus, Barcelona, Spain, ¹⁴Biomarkers and Clonal Dynamics Group, Vall d'Hebron Institute of Oncology, Vall d'Hebron Barcelona Hospital Campus, Barcelona, Spain, ¹⁵Early Clinical Drug Development Group, Vall d'Hebron Institute of Oncology, Vall d'Hebron Barcelona Hospital Campus, Barcelona, Spain

Keywords: Microstructure, Modelling, Immunotherapy, Liver, Tumours, Histology

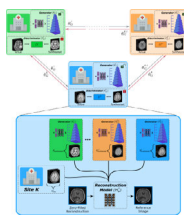
Motivation: Multi-compartment liver diffusion MRI (dMRI) provides innovative markers of intra-cellular fraction (F) and cell size (CS). However, practical implementations for histologically-meaningful F and CS computation in the clinic are still sought.

Goal(s): To deliver a compact approach for F and CS estimation, informing model design with histology.

Approach: We compared 5 implementations of a standard two-compartment model for their ability to provide F and CS estimates that agree with reference biopsies in liver tumours.

Results: The best approach consisted of fitting a single-compartment model of intra-cellular diffusion to high b-value images. This provides promising metrics that stratify the risk of progression in immunotherapy.

Impact: We deliver a clinically-feasible liver diffusion MRI approach for intra-cellular fraction, cell size and density estimation. It consists of fitting a single-compartment model of restricted diffusion to high b-value images, and provides metrics that may inform on cancer immunotherapy response.



Peer-to-Peer Generative Learning for Architecture-Agnostic Federated MRI Reconstruction

Valiyeh Ansarian Nezhad^{1,2}, Gökberk Elmas^{1,2}, and Tolga Çukur^{1,2,3}

¹Department of Electrical and Electronics Engineering, Bilkent University, Ankara, Turkey, ²National Magnetic Resonance Research Center (UMRAM), Bilkent University, Ankara, Turkey, ³Neuroscience Program, Bilkent University, Ankara, Turkey

Keywords: AI/ML Image Reconstruction, Machine Learning/Artificial Intelligence, Federated learning, multi-institutional, collaborative learning, image reconstruction

Motivation: Federated learning (FL) enables privacy-preserving training of deep reconstruction models across multiple sites to improve generalization at the expense of lower within-site performance. Yet, existing methods require a common model architecture across sites, limiting flexibility.

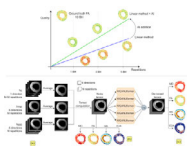
Goal(s): Our goal was to devise an architecture-agnostic method for collaborative training of heterogeneous models across sites.

Approach: We introduced a novel peer-to-peer generative learning method (PGL-FedMR), where individual sites share a generative prior for their MRI data with remaining sites, and prior-driven synthetic data are used to train reconstruction models at each site.

Results: PGL-FedMR improves across-site generalization over local models, and within-site performance over conventional FL.

Impact: Improvements in within-site and across-site performance for MRI reconstruction through PGL-FedMR, coupled with the ability to handle heterogeneous architectures, may facilitate privacy-preserving multi-institutional collaborations to build reliable reconstruction models for many applications where data are scarce including rare diseases.

0655



Accelerating DT-CMR with Deep Learning-based Tensor De-noising and Breath Hold Reduction

Michael Tanzer^{1,2}, Andrew Scott^{1,2}, Zohya Khaliq^{1,2}, Maria Dwornik^{1,2}, Ramyah Rajakulasingam^{1,2}, Ranil De Silva^{1,2}, Dudley Pennell^{1,2}, Pedro Ferreira^{1,2}, Guang Yang^{1,2}, Daniel Rueckert^{1,3}, and Sonia Nilles-Vallespin^{1,2}

¹Imperial College London, London, United Kingdom, ²Royal Brompton Hospital, London, United Kingdom, ³Technische Universität München, Munich, Germany

Keywords: Analysis/Processing, Machine Learning/Artificial Intelligence

Motivation: DT-CMR can revolutionise diagnosis and treatment of heart conditions by non-invasively imaging cardiomyocyte microstructure, but currently long acquisition times prevent clinical use.

Goal(s): Reduce the number of breath-holds required for in-vivo DT-CMR acquisitions, resulting in significantly reduced scan times with minimal image quality loss.

Approach: We developed a deep learning model based on Generative Adversarial Networks, Vision Transformers, and Ensemble Learning to de-noise diffusion tensors computed from reduced-repetition DT-CMR data. We compared model performance to conventional linear fitting methods and a baseline deep learning approach.

Results: Our model reduced noise over 20% compared to previous state-of-the-art approaches while retaining known clinically-relevant myocardial properties.

Impact: This breakthrough in DT-CMR acquisition efficiency could enable rapid microstructural phenotyping of the myocardium in the clinic for the first time, revolutionising personalised diagnosis and treatment by unlocking DT-CMR's ability to non-invasively characterise heart muscle organisation at the cellular level.

0670



Development of a Compact Head-only Scanner with a Window and Shoulders Outside its Vertical Bore.

Taylor Froelich¹, Sebastian Theilenberg², Joseph Bailey³, Lance DelaBarre¹, Steve Suddarth¹, Daniel Cosmo Pizetta⁴, Mateus José Martins⁴, Edson Luiz Géa Vidoto⁴, Yun Shang², Russell Lagore¹, Terence W Nixon⁵, John P Strupp¹, Jamal Olatunji³, Mathieu Szmigiel⁶, Mark Hunter⁷, Edgar Rodríguez Ramírez⁸, Mailin Lemke⁹, Chathura Kumaragamage⁵, Huub Weijers³, R Gilberto Gonzalez¹⁰, J. Thomas Vaughan^{2,11}, Robin A. de Graaf⁵, Christoph Juchem^{2,11}, Alberto Tannús⁴, Ben Parkinson³, and Michael Garwood^{1,12}

¹Center for Magnetic Resonance Research, Department of Radiology, University of Minnesota, Minneapolis, MN, United States, ²Department of Biomedical Engineering, Columbia University, New York, NY, United States, ³Robinson Research Institute, Victoria University of Wellington, Wellington, New Zealand, ⁴Centro de Imagens e Espectroscopia por Ressonância Magnética - CIERMag - São Carlos Physics Institute, University of São Paulo - IFSC-USP, São Carlos, Brazil, ⁵Department of Radiology and Biomedical Imaging, Magnetic Resonance Research Center, Yale University School of Medicine, New Haven, CT, United States, ⁶Air Liquide, Paris, France, ⁷Tranzpower Limited, Wellington, New Zealand, ⁸Victoria University of Wellington, Wellington, New Zealand, ⁹Dreifform GmbH, Hürth, Germany, ¹⁰Division of Neuroradiology, Massachusetts General Hospital, Boston, MA, United States, ¹¹Department of Radiology, Columbia University Medical Center, New York, NY, United States, ¹²Department of Biomedical Engineering, University of Minnesota, Minneapolis, MN, United States

Keywords: Hybrid & Novel Systems Technology, Hybrid & Novel Systems Technology, New Devices, Gradients, Magnets, Head-Only


Motivation: MRI has evolved into an indispensable tool, but remains inaccessible to much of the world's population.

Goal(s): To build a compact, low-cost, mid- to high-field MRI system capable of producing diagnostic-quality images.

Approach: A complete redesign of MR scanner architecture and key technologies; including a compact high temperature superconducting magnet, multi-coil gradient array, and digital spectrometer. The system required extensive testing prior to integration and initial imaging.

Results: Initial experiments produced high-resolution images despite using an extremely inhomogeneous magnetic field from the compact 0.7 tesla magnet.

Impact: This work represents a significant milestone within the MRI community to address the problems in accessibility and under-utilization facing MRI today. By focusing on ways to develop portable, low-cost systems, the accessibility of this imaging modality can increase substantially.



Are we validating enough our MRI markers? Cell-specific challenges to dissect the neurobiology of microstructural MRI

Antonio Cerdán Cerdá¹, Raquel Garcia-Hernandez¹, Mara Cercignani², Santiago Canals¹, and Silvia De Santis¹

¹Instituto de Neurociencias, CSIC-UMH, Alicante, Spain, ²CUBRIC, Cardiff, United Kingdom

Keywords: Biology, Models, Methods, Diffusion/other diffusion imaging techniques, inflammation, brain, degeneration, demyelination

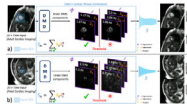
Motivation: Validation of MRI-extracted biomarkers is seldom performed, and when available, is normally underpowered and based on correlation.

Goal(s): Here we present an innovative framework for validating microstructural MRI biomarkers by eliciting cell-specific responses.

Approach: The framework is based on injection of neurotoxins in rats, followed by MRI exploration and histology.

Results: We successfully isolated conditions associated to neurodegenerative, demyelinating and inflammatory pathologies and demonstrated sensitivity and specificity of MRI-derived biomarkers.

Impact: This framework impulse a much-needed change in paradigm for MRI validation by challenging the biological content of MRI derived biomarkers, refine and test new models for microstructural imaging and bridge the gap between advances in MRI physics and clinical applications.



Dynamic Mode Decomposition (DMD) Cardiac Phase Estimation for adult and fetal real-time MRI

Ecrin Yagiz¹, Bilal Tasdelen¹, Ibrahim K. Ozaslan¹, Mihailo R. Jovanovic¹, Ye Tian¹, and Krishna S Nayak¹

¹Electrical and Computer Engineering, University of Southern California, Los Angeles, CA, United States

Keywords: Motion Correction, Fetus, retrospective-gating

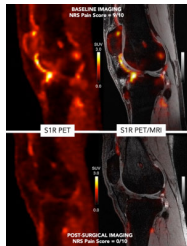
Motivation: Cardiac synchronization in adult and fetal imaging requires external devices (electrocardiogram, Doppler-ultrasound), which may compromise image quality and increase scan time. Self-gating with real-time imaging can mitigate this but may be less reliable for irregular motions and limited in fetal applications.

Goal(s): To develop a fast image-based cardiac phase estimation method with no assumption on the heart rate and minimal user input.

Approach: Dynamic Mode Decomposition is used to estimate cardiac motion signal for retrospective-gating.

Results: DMD cardiac phase estimation captures cardiac motion despite the irregularities and other bulk motions, as demonstrated in real-time adult and fetal cardiac imaging, including a twin gestation.

Impact: The proposed technique, Dynamic Mode Decomposition cardiac phase estimation, constructs cardiac signal with no assumption on periodicity, no iterations, and only minimal user input. This may be valuable in fetal cardiac imaging, where the cardiac signal is not readily available.



Sigma-1 receptor changes in chronic knee pain using PET/MRI: Preliminary results of fifteen patients

Rianne A van der Heijden¹, Luke Yoon², Paul Yoon², Guido Davidson², and Sandip Biswal¹

¹University of Wisconsin-Madison, Madison, WI, United States, ²Radiology, Stanford University School of Medicine, Stanford, CA, United States

Keywords: Whole Joint, Molecular Imaging, Knee, Pain

Motivation: Diagnosis of chronic knee pain remains a challenge with conventional diagnostic methods leading to unsatisfactory treatment in a large group of patients.


Goal(s): To investigate the use of sigma-1 receptor (S1R) radioligand, [¹⁸F] FTC-146 in conjunction with positron emission tomography/magnetic resonance imaging (PET/MRI) for identifying the pain generator in chronic knee pain.

Approach: Comparison of [¹⁸F] FTC-146 PET-MRI imaging findings in patients with unresolved chronic knee pain to healthy volunteers.

Results: All 15 patients showed statistically significant increased uptake of S1R compared to healthy control subjects in a variety of locations. At sites of abnormal PET uptake, MRI often did not demonstrate abnormalities.

Impact: Future clinical implementation of S1R-PET/MR can potentially help reveal previously unidentified pain generator in patients with chronic knee pain that have exhausted standard clinical care leading to better-targeted treatment.

0786



Built-in RF safety for active implants: Harnessing impedance measurements from a commercial deep brain stimulator

Berk Silemek¹, Mevlüt Yalaz², Frank Seifert¹, Reiner Montag¹, Michael Höft², Bernd Ittermann¹, and Lukas Winter¹

¹Physikalisch-Technische Bundesanstalt (PTB), Braunschweig and Berlin, Germany, ²Chair of Microwave Engineering, Christian-Albrechts-Universität zu Kiel, Kiel, Germany

Keywords: Safety, Safety, Deep brain stimulation, Active implantable medical devices, RF safety

Motivation: MRI of neurostimulators is severely constrained due to RF safety concerns.


Goal(s): Demonstrate that built-in sensors in commercial devices, such as a deep brain stimulator, can provide all necessary information to detect and improve RF safety.

Approach: We investigated and utilized built-in impedance measurements of two commercial DBS systems for the detection and mitigation of RF-induced currents on the electrodes of a DBS lead.

Results: Impedance measurements were correlated at various RF power levels. Temperature rise at the tip of DBS electrodes could be reduced to 0.02 K from 17.14 K at the same total powers (16.85±0.45 W).

Impact: Our demonstration of mitigation of RF-induced heating in active implants through built-in sensor measurements from a commercial DBS system indicated up to ~850× improvement in temperature rise proving the unmet value of sensors for MR imaging patients with active implants.

0806



Diffusion Modeling with Unrolled Transformers for Self-Supervised MRI Reconstruction

Yilmaz Korkmaz^{1,2,3}, Vishal M. Patel¹, and Tolga Cukur^{2,3}

¹Dept. of Electrical and Computer Engineering, Johns Hopkins University, Baltimore, MD, United States, ²Dept. of Electrical and Electronics Engineering, Bilkent University, Ankara, Turkey, ³National Magnetic Resonance Research Center (UMRAM), Bilkent University, Ankara, Turkey

Keywords: AI/ML Image Reconstruction, Machine Learning/Artificial Intelligence, Image reconstruction, diffusion models, deep learning


Motivation: Diffusion models can reconstruct high-quality MR images, but their training neglects physical constraints and requires supervision via ground-truth images derived from fully-sampled acquisitions.

Goal(s): Our goal was to devise a diffusion-based method that incorporates physical constraints and that can be trained using undersampled acquisitions.

Approach: We introduced a novel diffusion model (SSDiffRecon) based on a physics-driven unrolled transformer architecture; and self-supervised training was achieved by predicting held-out subsets of acquired k-space data from remaining subsets.

Results: SSDiffRecon achieved superior reconstructions to alternative self-supervised methods, and performed on par with a supervised benchmark trained on fully-sampled acquisitions.

Impact: The improvement in image quality and acquisition speed through SSDiffRecon, combined with the ability to train on undersampled acquisitions, may facilitate adoption of AI-based reconstruction for comprehensive MRI exams in many applications, particularly in pediatric and elderly populations.



Retrospective Motion Correction for Fetal 4D Flow MRI

Reagan M. Tompkins¹, Takashi Fujiwara², Eric M. Schrauben¹, Lorna P. Browne², Joost van Schuppen¹, Sally-Ann Clur³, Richard M. Friesen⁴, Erin K. Englund², Pim van Ooij¹, and Alex J. Barker^{2,5}

¹Department of Radiology & Nuclear Medicine, Amsterdam University Medical Center, location University of Amsterdam, Netherlands, ²Department of Radiology, Section of Pediatric Radiology, Children's Hospital Colorado, University of Colorado Anschutz Medical Campus, Denver, CO, United States, ³Department of Pediatric Cardiology, Emma's Children's Hospital, Amsterdam University Medical Center, location University of Amsterdam, Netherlands, ⁴Department of Pediatrics, Section of Cardiology, Children's Hospital Colorado, University of Colorado Anschutz Medical Campus, Denver, CO, United States, ⁵Department of Bioengineering, University of Colorado Anschutz Medical Campus, Denver, CO, United States

Keywords: Fetal, Motion Correction

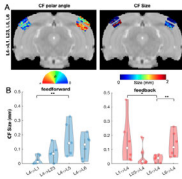
Motivation: Maternal breathing and fetal bulk motion frequently limit the utility of fetal 4D flow MRI.

Goal(s): To demonstrate the effects of maternal respiratory and fetal bulk motion correction on 4D flow MRI

Approach: Prospective undersampled fetal 4D flow data were acquired in two subjects, followed by compressed sensing reconstruction that included maternal respiratory gating and bulk motion correction. Standard SENSE-accelerated 4D flow acquisitions without motion correction (N=22) provided reference for the ability to quantify flow.

Results: Comparisons of the motion corrected data to normative performance illustrate the technique's potential for mitigating motion in fetal 4D flow, with equivalence to standard SENSE accelerated scans.

Impact: The proposed sequence and flexible reconstruction workflow provide motion robustness for fetal 4D flow MRI. Further exploration of motion correction techniques has potential to enhance spatial and temporal resolution and to mitigate motion-related errors over extended scanning durations.



Decoding directionality of information in cortical networks using layer-based connective field model

Joana Carvalho¹, Francisca Fernandes¹, Koen Haak², and Noam Shemesh¹

¹Laboratory of Preclinical MRI, Champalimaud Experimental Clinical Research Programme, Champalimaud Foundation, Lisboa, Portugal, ²Donders Institute for Brain Cognition and Behaviour, Nijmegen, Netherlands

Keywords: Functional Connectivity, Brain Connectivity, BOLD, diffusion fMRI, visual system, connective field model

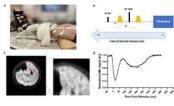
Motivation: To disentangle feedback and feedforward signals in cortical circuits.

Goal(s): To unravel the intricate neural connections within cortical layers.

Approach: We implemented a layer connective field (ICF) model and applied it to ultrafast RS data and RS dfMRI data.

Results: 1. Intracortical ICF shows two ICF size profiles: **feedforward** with inverse U shape with the larger ICF sizes at layer 5 and **feedback** with U shape and larger CF sizes at superficial and deeper layers. 2. In the absence of visual input the functional connectivity reflects visuotopic organization. 3. ICF estimates obtained from dfMRI(ADC) are more layer specific than the ones estimated from BOLD.

Impact: This study showcases the ability of high spatio-temporal resolution MRI techniques (ultrafast BOLD and dfMRI) when coupled with biologically grounded connectivity models (ICF) to unveil the intricacies of information directionality within topographically organized cortices.



Motor unit magnetic resonance imaging to assess muscle twitch dynamics in mitochondrial disease after an exercise programme.

Matthew Birkbeck^{1,2}, Mathew Elameer^{1,3}, Linda Heskamp¹, Jane Newman^{1,4,5,6}, Renae Stefanetti^{1,4,5,6}, Isabel Barrow^{1,4,5,6}, Gráinne Gorman^{1,4,5,6}, Ian Schofield¹, Julie Hall³, Andrew Blamire¹, and Roger Whittaker¹

¹Translational and Clinical Research Institute, Newcastle University, Newcastle upon Tyne, United Kingdom, ²Northern Medical Physics and Clinical Engineering, Newcastle upon Tyne NHS Foundation Trust, Newcastle upon Tyne, United Kingdom, ³Department of Neuroradiology, Newcastle upon Tyne NHS Foundation Trust, Newcastle upon Tyne, United Kingdom, ⁴Wellcome Centre for Mitochondrial Research, Newcastle University, Newcastle upon Tyne, United Kingdom, ⁵National Institute for Health and Care Research Newcastle Biomedical Research Centre, Newcastle University, Newcastle upon Tyne, United Kingdom, ⁶NHS Highly Specialised Service for Rare Mitochondrial Disorders, Newcastle upon Tyne NHS Foundation Trust, Newcastle upon Tyne, United Kingdom

Keywords: Functional/Dynamic, Muscle, Genetic Diseases


Motivation: Changes to muscle twitch dynamics are overlooked in trials assessing resistance exercise in primary mitochondrial myopathies (PMM).

Goal(s): Motor unit MRI to measure twitch dynamics in PMM participants before and after a 12-week exercise programme.

Approach: Voxel-wise measurements of rise time (T_{rise}), contraction time (T_{contract}) and half-relaxation time ($T_{\text{half-relax}}$) in the tibialis anterior in 10 controls and 9 PMM participants. PMM participants scanned twice, before and after a 12-week exercise programme.

Results: T_{contract} of the tibialis anterior was significantly longer in PMM participants post exercise; T_{rise} , $T_{\text{half-relax}}$ demonstrated no change. In participants who had the highest adherence to exercise T_{contract} increased the most.

Impact: Motor unit MRI (MUMRI) detected slower muscle contraction times in primary mitochondrial myopathies post resistance exercise programme. This may evidence increased numbers of type-I fibres post-exercise. MUMRI could be used to measure changes in muscle twitch dynamics in neuromuscular diseases.



Connectome 2.0: Performance evaluation and initial in vivo human brain diffusion MRI results

Gabriel Ramos-Llordén¹, Peter Dietz², Mathias Davids¹, Hong-Hsi Lee¹, Yixin Ma¹, Mirsad Mahmutovic³, Alina Scholz³, Hansol Lee¹, Chiara Maffei¹, Anastasia Yendiki¹, Berkin Bilgic¹, John E. Kirsch¹, Daniel J. Park¹, Bryan Clifford⁴, Wei-Ching Lo⁴, Stefan Stocker², Jasmine Fischer², Elmar Rummert², Andreas Krug², Andreas Potthast², Thomas Benner², Rebecca Ramb², Peter J. Basser⁵, Thomas Witzel⁶, Lawrence L. Wald¹, Bruce R. Rosen¹, Boris Keil^{3,7}, and Susie Y. Huang¹

¹Athinoula A. Martinos Center for Biomedical Imaging, Massachusetts General Hospital and Harvard Medical School, Charlestown, MA, United States, ²Siemens Healthineers, Erlangen, Germany, ³Institute of Medical Physics and Radiation Protection, Mittelhessen University of Applied Sciences, Giessen, Germany, ⁴Siemens Medical Solutions USA, Boston, MA, United States, ⁵Eunice Kennedy Shriver National Institute of Child Health and Human Development, National Institutes of Health, Bethesda, MD, United States, ⁶Q Bio Inc, San Carlos, CA, United States, ⁷Department of Diagnostic and Interventional Radiology, University Hospital Marburg, Philipps University of Marburg, Marburg, Germany

Keywords: Gradients, Gradients, Diffusion Acquisition, Neuro

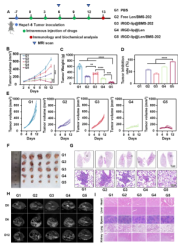
Motivation: Current human MR scanners cannot resolve the full range of length scales needed to study the brain's microscopic and mesoscopic structure.

Goal(s): To construct and validate the next-generation human connectomics and microstructure MRI scanner known as Connectome 2.0.

Approach: The 3T Connectome 2.0 scanner incorporates a peripheral nerve stimulation-optimized asymmetric head gradient driven by dual gradient power amplifiers. Custom-built high-sensitivity 72-channel (in vivo imaging) and 64-channel (ex vivo imaging) receive coils were integrated.

Results: The Connectome 2.0 scanner achieves $G_{\text{max}}=500$ mT/m and $SR_{\text{max}}=600$ T/m/s, demonstrates 2x improved SNR for diffusion MRI over Connectome 1.0, and enables high-resolution tractography.

Impact: The Connectome 2.0 scanner will allow the exploration of new microstructure properties and connective anatomy in the living human brain with unprecedented spatial and diffusion resolution.



Improved Hepatocellular Carcinoma Targeted Combination Immunotherapy Using a Nanocarrier: Monitoring Tumor Response via Functional MRI

Jiamin Li¹, Ruili Wei¹, Ruimeng Yang¹, Xinqing Jiang¹, and Yongzhou Xu²

¹Department of Radiology, The Second Affiliated Hospital, School of Medicine, South China University of Technology, Guangzhou, China, ²Philips Healthcare, Guangzhou, China

Keywords: Liver, fMRI, Hepatocellular Carcinoma; Immunotherapy; Nanocarrier; IVIM-MRI; Tumor Microenvironment

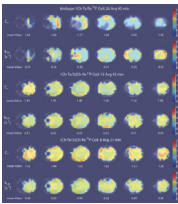
Motivation: To enhance the efficacy of hepatocellular carcinoma immunotherapy using a nanocarrier and to explore IVIM-MRI for monitoring the tumor immune microenvironment.

Goal(s): To synthesize iRGD-targeted liposomes to enhance the treatment efficacy of hepatocellular carcinoma and to develop effective biomarkers for the tumor microenvironment.

Approach: We synthesized iRGD-modified liposomal co-encapsulating Lenvatinib and BMS-202. IVIM-MRI was performed before and at 6 and 12 days after treatments, followed by pathological examination after the final scan.

Results: iRGD-lip@Len/BMS-202 promotes tumor vascular normalization and effectively activates an anti-tumor immune response. Importantly, the derived parameters D^* and f are significantly correlated with tumor vascular normalization and immune activation.

Impact: The iRGD-targeted dual-drug liposomal nanoparticles exhibited potent synergistic anti-tumor effects. Additionally, IVIM-MRI facilitated the monitoring of changes in the tumor microenvironment, with the D^* and f parameters serving as valuable indicators for evaluating tumor vascular network and immune microenvironment modulation.



3D whole brain mapping of creatine kinase metabolic rate using ³¹P-MR fingerprinting.

Mark Stephan Widmaier^{1,2}, Antonia Kaiser¹, Ying Xiao^{1,3}, Zhiwei Huang^{1,4}, Yun Jiang⁵, Song-I Lim⁶, Daniel Wenz⁶, and Lijing Xin⁶

¹Animal imaging and technology core, CIBM Center for Biomedical Imaging, École polytechnique fédérale de Lausanne (EPFL), Lausanne, Switzerland, ²Laboratory for Functional and Metabolic Imaging, Ecole Polytechnique Fédérale de Lausanne (EPFL), Lausanne, Switzerland, ³Laboratory for Functional and Metabolic Imaging, Ecole Polytechnique Fédérale de Lausanne (EPFL), Lausanne, Switzerland, ⁴Laboratory for Functional and Metabolic Imaging, École Polytechnique Fédérale de Lausanne (EPFL), Lausanne, Switzerland, ⁵Department of Radiology, Case Western Reserve University, Cleveland, Cleveland, OH, United States, ⁶Animal imaging and technology core, CIBM Center for Biomedical Imaging, École Polytechnique Fédérale de Lausanne (EPFL), Lausanne, Switzerland

Keywords: MR Fingerprinting, MR Fingerprinting, ³¹P, MRF, creatine kinase rate, k_{CK} , MRSI, 7T

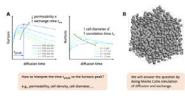
Motivation: Using ³¹P MRS combined with magnetization transfer (MT) experiments including saturation transfer or inversion transfer to assess chemical exchange rate of creatine kinase (k_{CK}) in the human brain are time-consuming and limited to 1D-acquisitions.

Goal(s): Acquiring a 3D whole brain k_{CK} map.

Approach: In this abstract, we introduce an advanced, fast 3D-³¹P-MRF sequence for the human brain at 7T.

Results: The novel 3D-³¹P-MRF approach is feasible for whole brain mapping of k_{CK} , enabling the investigation of region-specific energy metabolism under various pathological conditions.

Impact: Using the novel 3D-³¹P-MR Fingerprinting approach for whole brain mapping of k_{CK} enables us to investigate region-specific energy metabolism under various pathological conditions and may enhance our understanding of the underlying molecular and metabolic processes.



Revealing membrane integrity and cell size from diffusion kurtosis time-dependence

Hong-Hsi Lee¹, Dmitry S Novikov², Els Fieremans², and Susie Y Huang¹

¹Radiology, Massachusetts General Hospital, Charlestown, MA, United States, ²New York University School of Medicine, New York, NY, United States

Keywords: Simulation/Validation, Microstructure, simulations, validation

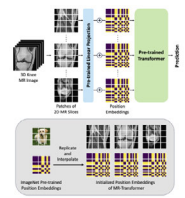
Motivation: The non-monotonic dependence of the diffusion kurtosis on diffusion time has been observed in tissue, yet its relation to membrane integrity and tissue geometry remains unknown.

Goal(s): We investigate the relation between the characteristic time t_{peak} and the tissue parameters, such as cell size, volume fraction and permeability.

Approach: We perform Monte Carlo simulations of diffusion and exchange in randomly, densely packed spheres with varying permeability, cell fractions and sizes, and identify the value of t_{peak} .

Results: We obtain an empirical, albeit highly accurate relation of t_{peak} to tissue parameters in a broad parameter range.

Impact: Diffusion-kurtosis time-dependence is sensitive to pathological changes in membrane integrity and cellular structure in diseases, such as ischemic stroke and tumors. Numerical simulations suggest an empirical interpretation of kurtosis time-dependence, offering a novel biomarker for in vivo evaluation of pathology.



MR-Transformer: Vision Transformers for Total Knee Replacement Prediction using Magnetic Resonance Imaging

Chaojie Zhang¹, Shengjia Chen¹, Haresh Rengaraj Rajamohan², Kyunghyun Cho², Richard Kijowski³, and Cem M. Deniz^{1,3}

¹Bernard and Irene Schwartz Center for Biomedical Imaging, Department of Radiology, New York University Grossman School of Medicine, New York, NY, United States, ²Center for Data Science, New York University, New York, NY, United States, ³Department of Radiology, New York University Langone Health, New York, NY, United States

Keywords: Diagnosis/Prediction, Data Analysis, Deep Learning

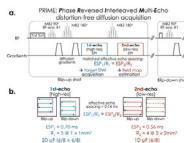
Motivation: Current deep learning methods for assessing knee osteoarthritis have limitations in learning long-range spatial information from magnetic resonance imaging (MRI).

Goal(s): This study aims to develop a new deep learning model for total knee replacement (TKR) prediction using MRI.

Approach: We proposed a novel transformer-based model, MR-Transformer, adapted from the ImageNet pre-trained vision transformer DeiT-Ti. The model can capture long-range spatial information from MR images with transformer architecture. We evaluated our model on TKR prediction using MR images with different tissue contrasts.

Results: The experimental results demonstrated an improved performance of MR-Transformer compared to conventional deep learning models.

Impact: Our proposed MR-Transformer enhances computer-aided diagnosis accuracy in total knee replacement prediction using MRI. It has the potential to provide rapid and quality diagnostic outcomes, assisting physicians in making timely and informed treatment decisions.



PRIME: Phase Reversed Interleaved Multi-Echo acquisition enables highly accelerated distortion-free diffusion MRI

Yohan Jun^{1,2}, Qiang Liu^{2,3}, Jaejin Cho^{1,2,4}, Xingwang Yong^{1,2,5}, Shohei Fujita^{1,2}, Susie Y Huang^{1,2,6}, Yogesh Rathi^{2,3,7}, and Berkin Bilgic^{1,2,6}

¹Athinoula A. Martinos Center for Biomedical Imaging, Massachusetts General Hospital, Boston, MA, United States, ²Department of Radiology, Harvard Medical School, Boston, MA, United States, ³Department of Psychiatry, Brigham and Women's Hospital, Boston, MA, United States, ⁴Pediatric Imaging Research Center, Massachusetts General Hospital, Boston, MA, United States, ⁵Zhejiang University, Hangzhou, China, ⁶Harvard/MIT Health Sciences and Technology, Cambridge, MA, United States, ⁷Department of Radiology, Brigham and Women's Hospital, Boston, MA, United States

Keywords: Diffusion Acquisition, Diffusion/other diffusion imaging techniques

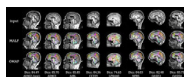
Motivation: Current distortion-free multishot diffusion MRI (dMRI) techniques rely on interim reconstructions to estimate a fieldmap, whose quality deteriorates at high accelerations, thus precluding high-resolution imaging.

Goal(s): To develop a distortion-free acquisition that reaches high accelerations with high fidelity.

Approach: We propose PRIME, which incorporates a second echo acquired at lower resolution and acceleration, but with matching echo spacing as the first echo. This yields high-fidelity fieldmaps to be used in 10-fold accelerated scans.

Results: PRIME enables high-quality distortion-free dMRI at $R_{\text{inplane}} \times \text{SMS} = 5 \times 2$ and 1 mm^3 resolution without prolonging the scan thanks to utilizing the dead time in gSlider RF-encoded acquisitions.

Impact: We propose a distortion-free dMRI sequence, PRIME, that reaches $R_{\text{inplane}} \times \text{SMS} = 5 \times 2$ at 1 mm^3 resolution with high fidelity owing to its ability to estimate a high-quality fieldmap from a second echo inserted without prolonging the TR in gSlider RF-encoded acquisitions.



A Rapid Deep Learning Approach to Parcellate 280 Anatomical Regions to Cover the Whole Brain

Kei Nishimaki^{1,2}, Kengo Onda¹, Kumpei Ikuta², Jill Chotiyononta¹, Yuto Uchida¹, Susumu Mori¹, Hitoshi Iyatomi², and Kenichi Oishi^{1,3}

¹The Russell H. Morgan Department of Radiology and Radiological Science, The Johns Hopkins University School of Medicine, Baltimore, MD, United States, ²Department of Applied Informatics, Hosei University Graduate School of Science and Engineering, Tokyo, Japan, ³The Richman Family Precision Medicine Center of Excellence in Alzheimer's Disease, Johns Hopkins University School of Medicine, Baltimore, MD, United States

Keywords: Segmentation, Segmentation

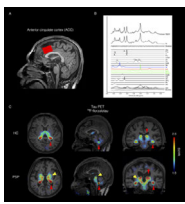
Motivation: Whole-brain MRI parcellation serves as a feature extraction technique, allowing for the condensation of over a million pixels of information into a few hundred neuroanatomically defined elements.

Goal(s): The multi-atlas label-fusion (MALF) method is known for accurate parcellation but typically necessitates several hours to process a single image. Our goal was to develop a faster parcellation tool with an accuracy comparable to that of MALF.

Approach: We introduce open-source multiple anatomical parcellation T1 (OpenMAP-T1), based on deep learning and multi-processing.

Results: The OpenMAP achieves an equivalent parcellation performance to MALF and is 40 times faster.

Impact: OpenMAP significantly accelerates processing speed, allowing for large-scale data analysis using volumetric information derived from detailed parcellation of the whole brain, including both gray and white matter regions.



In vivo assessment of astrocyte reactivity in patients with progressive supranuclear palsy.

Kosei Hirata^{1,2}, Kiwamu Matsuoka¹, Kenji Tagai¹, Hironobu Endo¹, Harutsugu Tatebe¹, Maiko Ono¹, Naomi Kokubo¹, Yuko Kataoka¹, Asaka Oyama¹, Hitoshi Shinoto¹, Keisuke Takahata¹, Takayuki Obata¹, Masoumeh Dehghani³, Jamie Near^{3,4}, Kazunari Kawamura¹, Ming-Rong Zhang¹, Hitoshi Shimada^{1,5}, Hiroshi Shimizu⁵, Hiroshi Shimizu⁵, Takanori Yokota², Takahiko Tokuda¹, Makoto Higuchi¹, and Yuhei Takado¹

¹National Institutes for Quantum Science and Technology, Chiba, Japan, ²Tokyo Medical and Dental University, Tokyo, Japan, ³Sunnybrook Research Institute, Tronto, ON, Canada, ⁴University of Toronto, Tronto, ON, Canada, ⁵Niigata University, Niigata, Japan

Keywords: Dementia, Neuro, magnetic resonance spectroscopy, progressive supranuclear palsy, astrocyte reactivity

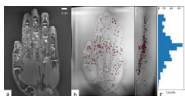
Motivation: Although astrocytic pathology is a pathological hallmark of progressive supranuclear palsy (PSP), the role of astrocytes in the pathophysiology of PSP is not fully understood.

Goal(s): This study aimed to evaluate astrocyte reactivity *in vivo* in patients with PSP.

Approach: Astrocyte reactivity was assessed by magnetic resonance spectroscopy and plasma biomarkers, which were verified via tau-PET and histopathological analysis.

Results: Our results suggest that, in the anterior cingulate cortex, astrocyte reactivity precedes pronounced tau deposition and neurodegenerative processes and modulates brain function in PSP. Elevated myo-inositol was associated with high lactate levels, suggesting a link between reactive astrocytes and brain energy metabolism changes.

Impact: This study assessed astrocyte reactivity *in vivo* using magnetic resonance spectroscopy and plasma biomarkers, providing insights into the involvement of astrocytes in the pathogenesis of progressive supranuclear palsy.



High-resolution mapping of hand innervation: novel approaches at 7T MRI

Pauline Coralie Guillemin¹, David Ferreira Branco², Yacine M'Rad¹, Loan Mattera³, Orane Lorton¹, Pierre-Alexandre Poletti², Gian-Franco Piredda^{4,5}, Antoine Klausser^{4,5}, Roberto Martuzzi³, Rares Salomir², and Sana Boudabbous²

¹Image guided Interventions Laboratory (949), Faculty of Medicine, University of Geneva, Geneva, Switzerland, ²Radiology Department, University Hospitals of Geneva, Geneva, Switzerland, ³Fondation Campus Biotech Geneva, Geneva, Switzerland, ⁴Advanced Clinical Imaging Technology, Siemens Healthineers International AG, Lausanne, Switzerland, ⁵CIBM Centre for Biomedical Imaging, Geneva, Switzerland

Keywords: Peripheral Nerves, Nerves, Pacinian corpuscles

Motivation: Exploit the high resolution provided by the 7T MRI technology to detect fine structures in the hand.

Goal(s): To create an atlas of hand structures, with a specific focus on nerves and Pacinian corpuscles. This atlas is intended to serve both diagnostic purposes and to support reconstructive surgical procedures.

Approach: An ethics committee was obtained to scan volunteers using 7T MRI. Post-processing was carried out to delineate the nerve fiber network and mechanoreceptors.

Results: We successfully reconstruct and describe the anatomy of all nerve fibers from the carpus to the digital nerve division, as well as the Pacinian corpuscles, for three healthy volunteers.

Impact: A visual interactive "Hand Nerves Atlas" matching morphology and fiber tracking of hand nerves on high-field will be delivered to the scientific community for fundamental research, to clinicians for microscopic surgery of nerves, and for educational purposes in medical schools.

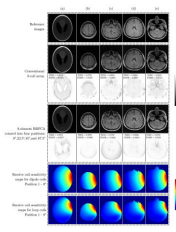


Image reconstruction for an 8-element loop-dipole rotating RF coil array (RRFCA) using a novel calibration-free GRAPPA-based method

Lachlan West¹, Andrew Phair^{2,3}, Mingyan Li¹, Michael Brideson³, Andrew P Bassom³, and Feng Liu¹

¹University of Queensland, Brisbane, Australia, ²King's College London, London, United Kingdom, ³University of Tasmania, Hobart, Australia

Keywords: Image Reconstruction, Image Reconstruction

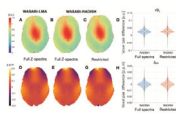
Motivation: SENSE-based reconstruction is challenging for clinical imaging when rotating the RRFCA into multiple positions; therefore, a novel calibration-free GRAPPA-based method was developed.

Goal(s): To effectively reconstruct k-space data acquired from the RRFCA, enhancing image quality compared to a conventional stationary array without a scan time penalty.

Approach: Conventional GRAPPA was extended by uncovering a subset of the radial grid to cope with the rotation of the RRFCA. Numerical and human brain images were used for validation.

Results: Image quality was improved using the proposed method. Up to 58% reduction in RMSE and 2.5% increase in SSIM was achieved while maintaining scan time.

Impact: The RRFCA utilising our novel calibration-free, GRAPPA-based, radial image reconstruction method provides a clinically relevant parallel imaging technique. In the future, our approach may incorporate compressed sensing to further reduce motion artifacts, particularly in applications like cardiac and dynamic MRI.



Rapid and simplified post-processing for B₀ and B₁ mapping with WASABI-RADISH in the application of CEST at 7T

Mara Quach^{1,2}, Myrte Strik^{2,3,4}, Rebecca Glarin², Bradford A Moffat², David K Wright⁵, and Leigh A Johnston^{1,2}

¹Department of Biomedical Engineering, University of Melbourne, Parkville, Australia, ²Melbourne Brain Centre Imaging Unit, University of Melbourne, Parkville, Australia, ³Spinoza Centre for Neuroimaging, Royal Netherlands Academy of Sciences, Amsterdam, Netherlands, ⁴Department of Computational Cognitive Neuroscience & Neuroimaging, Netherlands Institute for Neuroscience, Royal Netherlands Academy of Arts and Sciences, Amsterdam, Netherlands, ⁵Central Clinical School, Department of Neuroscience, Monash University, Melbourne, Australia

Keywords: CEST / APT / NOE, CEST & MT, B₁, B₀, WASABI, data processing, UHF, 7T, tools

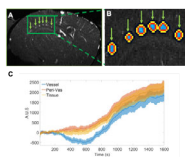
Motivation: WASABI provides high fidelity B₀ and B₁ maps necessary for CEST correction yet suffers from prolonged post-processing incompatible with clinical use.

Goal(s): Our goal was to design an optimisation-free method to expedite map estimations.

Approach: A direct relationship was derived between B₀ and B₁ and information in WASABI Z-spectra.

Results: The proposed approach accelerated post-processing by a factor of 80, with improved estimation in brain regions that are noisy and/or have unpredictable initial magnetisation.

Impact: Improvement in speed and accuracy provided by RADISH has the ability to make WASABI, and quantitative CEST at ultra-high-field in general, more reliable and clinically feasible.



Mapping glymphatic solute transportation through the perivascular space of hippocampal arterioles with 14 Tesla MRI

Xiaoqing Alice Zhou^{1,2}, Weitao Man^{1,2}, Xiaochen Liu^{1,2}, Yuanyuan Jiang^{1,2}, David Hike^{1,2}, Lidia Gomez Cid^{1,2}, Sangcheon Choi^{1,2}, Changrun Lin^{1,2}, and Xin Yu^{1,2}

¹A.A. Martinos Center for Biomedical Imaging, Massachusetts General Hospital, Boston, MA, United States, ²Harvard Medical School, Boston, MA, United States

Keywords: Small Animals, Vessels, Glymphatic

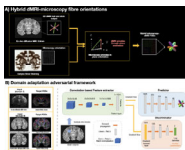
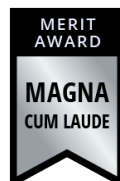Motivation: The perivascular space (PVS) plays a crucial role in facilitating the clearance of waste products and the exchange of cerebrospinal fluid and interstitial fluid in the central nervous system.

Goal(s): However, the limited depth penetration of current imaging methods impedes the study of glymphatic dynamics in deep brain regions.

Approach: In this study, we introduced an ultra-high-resolution dynamic contrast-enhanced MRI mapping approach based on single-vessel multi-gradient-echo methods.

Results: This technique allowed the differentiation of penetrating arterioles and venules from adjacent parenchymal tissue voxels and enabled the detection of Gd-enhanced signals coupled to PVS of penetrating arterioles in the deep cortex and hippocampus.

Impact: The study revealed significant PVS-specific Gd signal enhancements, shedding light on glymphatic function in deep brain regions. These findings advance our understanding of brain-wide glymphatic dynamics and impaired waste clearance, warranting further exploration of their clinical relevance and therapeutic applications.



Estimating microscopy-informed fibre orientations from in-vivo dMRI using a domain adaptation adversarial network

Silei Zhu¹, Nicola K. Dinsdale², Saad Jbabdi¹, Karla L. Miller^{*1}, and Amy F.D. Howard^{*1}

¹Wellcome Centre for Integrative Neuroimaging, FMRIB Centre, Nuffield Department of Clinical Neurosciences, University of Oxford, Oxford, United Kingdom, ²Oxford Machine Learning in Neuroimaging Lab (OMNI), Department of Computer Science, University of Oxford, Oxford, United Kingdom

Keywords: Tractography, Tractography & Fibre Modelling, Multimodal, Microscopy, structural connectivity, diffusion, machine learning

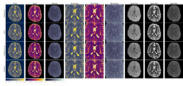
Motivation: Joint modelling of diffusion MRI and microscopy can leverage their complementary strengths to improve the estimation of fibre orientations. Ideally, these benefits would extend beyond the few datasets where dMRI and microscopy are acquired in the same brain to improve orientation estimates in *in-vivo* data.

Goal(s): To translate the unique properties of joint dMRI-microscopy data modelling to benefit *in-vivo* dMRI datasets.

Approach: We construct a domain adaptation adversarial network that can estimate microscopy-informed FODs from single-shell *in-vivo* dMRI.

Results: Tractography performed using network-derived FODs show improved tracking in grey matter, bottleneck regions, superficial white matter fibres, and long-range structural connectivity.

Impact: Our microscopy-informed neural network improves fibre orientation estimation from *in-vivo* single-shell dMRI datasets. We demonstrate improvements in fibre tracking that may enable more precise and detailed detection of connectivity, with a broad range of applications in basic and clinical neuroscience.



MRI2Qmap: compressed-sampled multiparametric quantitative MRI reconstruction using learned spatial priors from multimodal MRI datasets

Mohammad Golbabaee¹, Matteo Cencini², Carolin M Pirkl³, Marion I Menzel³, Michela Tosetti⁴, and Bjoern H Menze⁵

¹University of Bristol, Bristol, United Kingdom, ²INFN Pisa division, Pisa, Italy, ³GE Healthcare, Munich, Germany, ⁴IRCCS Stella Maris, Pisa, Italy, ⁵University of Zurich, Zurich, Switzerland

Keywords: MR Fingerprinting, Quantitative Imaging, MR Fingerprinting, Compressed sensing, Image reconstruction, AI/ML Image Reconstruction


Motivation: Deep learning excels at compressed-sensing image reconstruction given large training datasets. Applying this paradigm to accelerated quantitative MRI, including magnetic resonance fingerprinting (MRF), is challenging because quantitative imaging datasets for training are scarce.

Goal(s): Can we overcome this limitation using new sources of training data from routine, largely available weighted-MRI images?

Approach: We introduce MRI2Qmap, a plug-and-play quantitative image reconstruction algorithm based on deep image denoising models pretrained on large multimodal weighted-MRI datasets.

Results: We showed, for the first time, that spatial/structural priors learned from independently-acquired datasets of routine weighted-MRI images can be effectively used for quantitative MRI image reconstruction.

Impact: Thanks to the widespread use of MRIs, our approach could enable much larger datasets to be used for training potentially enhanced AI models for fast quantitative MRI/MRF image reconstruction.



Cellular signatures of microstructural development in the human cerebral cortex

Sila Genc^{1,2,3}, Gareth Ball³, Maxime Chamberland^{2,4}, Erika P Raven^{2,5}, Chantal MW Tax^{2,6}, Joseph YM Yang^{1,3}, Marco Palombo², and Derek K Jones²

¹Neuroscience Advanced Clinical Imaging Service (NACIS), Department of Neurosurgery, The Royal Children's Hospital, Melbourne, Australia, ²Cardiff University Brain Research Imaging Centre (CUBRIC), Cardiff University, Cardiff, United Kingdom, ³Developmental Imaging, Murdoch Children's Research Institute, Melbourne, Australia, ⁴Department of Mathematics and Computer Science, Eindhoven University of Technology, Eindhoven, Netherlands, ⁵Department of Radiology, New York University Grossman School of Medicine, New York, NY, United States, ⁶Image Sciences Institute, University Medical Center Utrecht, Utrecht, Netherlands

Keywords: Normal Development, Microstructure, Development, cortex, childhood, adolescence

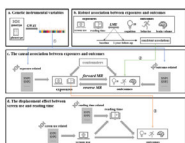
Motivation: The adolescent brain has been well described using MRI, revealing ongoing cortical thinning and volume loss. But which underlying cellular properties drive these changes?

Goal(s): To model developmental patterns of soma and neurite architecture in the human cerebral cortex.

Approach: We quantified in vivo cortical neurite and soma microstructure in a sample of children and adolescents aged 8-18 years. We then analysed two human gene expression databases to determine cell-type specific profiles underlying these MR-based changes.

Results: Developmental increases in neurite density and reductions in soma radius suggest increasing cortical oligodendrocyte density, supporting the model of protracted intra-cortical myelination throughout the adolescent period.

Impact: Our novel study suggests that ongoing intracortical myelination underpins developmental patterns of cortical neurite and soma microstructure. Once thought to be driven by synaptic pruning, increasing cortical oligodendrocyte density may underlie previously reported patterns of cortical volume loss in adolescence.



The causal effect of screen uses versus reading on the brain development in early adolescents

Mingyang Li¹, Ruoke Zhao¹, Xixi Dang², Xinyi Xu¹, Ruike Chen¹, Yiwei Chen¹, Yuqi Zhang¹, Zhiyong Zhao¹, and Dan Wu¹

¹Department of Biomedical Engineering, Zhejiang University, Hangzhou, China, ²Department of Psychology, Hangzhou Normal University, Hangzhou, China

Keywords: Adolescents, Adolescents, screen use, reading, brain volume, brain development


Motivation: The causal relationships between screen use and mental health were not clear.

Goal(s): We used genetic, imaging, and questionnaire data from ABCD study to investigate the causal relationships between screen use and mental health in early adolescents.

Approach: One-sample Mendelian randomization analysis.

Results: We found a direct causal relationship between screen use and behavior problems and an indirect effect between screen use and brain volume by the changes in reading habits.

Impact: These findings provide new evidence for a causal influence of screen use and reading habits on brain development and highlight the importance of monitoring media use and related habits change in children.



Multi-Omics Integration of MRI Habitat, Pathology, and Clinical Parameters for Predicting Platinum Resistance of HGSOc

Qiu Bi¹, Jinwei Qiang², Yang Song³, and Yunzhu Wu³

¹the First People's Hospital of Yunnan Province, Kunming, China, ²Jinshan Hospital, Fudan University, Shanghai, China, ³MR Research Collaboration Team, Siemens Healthineers Ltd., Shanghai, China

Keywords: Cancer, Cancer

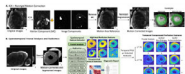
Motivation: Platinum resistance of high-grade serous ovarian carcinoma (HGSOc) is related to tumor heterogeneity. Multi-omics integration can complement tumor heterogeneity at multiple scales and enhance the predictive power of single models.

Goal(s): We aimed to explore a range of diverse multi-omics models to predict platinum resistance of HGSOc.

Approach: Multi-omics models were developed and validated using MRI-based habitat radiomics, pathomics based on haematoxylin and eosin (H&E)-stained whole slide images (WSIs), and clinical parameters.

Results: Among the array of single and composite models, the Clinic_Habitat model exhibited the most promising predictive performance, with the Clinic_Habitat_Pathology model ranking as the second-best performer.

Impact: This study carries the potential to equip clinicians with treatment strategies aimed at enhancing the efficacy of individualized therapy.



Phase-Specific Spatiotemporal Fractal Analysis and Radiomics of Free-breathing Stress Myocardial Perfusion

Changyu Sun^{1,2}, Senthil Kumar³, and Talissa Altes²

¹Chemical and Biomedical Engineering, University of Missouri Columbia, Columbia, MO, United States, ²Radiology, University of Missouri Columbia, Columbia, MO, United States, ³Medicine-Cardiology, University of Missouri Columbia, Columbia, MO, United States

Keywords: Myocardium, Perfusion

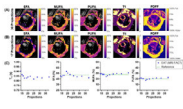
Motivation: This research advances quantitative analysis of myocardial perfusion MRI, potentially enhancing the precision of coronary microvascular disease diagnosis.

Goal(s): To establish a novel spatiotemporal radiomics and fractal analysis approach, assessing myocardial perfusion patterns and complexity throughout all temporal frames of stress MRI.

Approach: Employing free-breathing stress myocardial perfusion MRI, we utilized a comprehensive pixel-by-pixel spatiotemporal feature extraction, alongside phase-specific analysis, to derive global and segmental perfusion insights.

Results: Preliminary results indicate our method's efficacy in motion correction and feature extraction, offering a new quantitative perspective on myocardial perfusion, potentially relevant for CMD assessment.

Impact: The study introduces a framework that quantitatively captures myocardial perfusion patterns, potentially paving the way for enhanced diagnostic methods in coronary microvascular disease and facilitating a more precise approach to patient assessment.



Accelerated Method for Joint Fatty Acid Composition and T1 (FACT) Mapping of Epicardial Adipose Tissue in Mice at 9.4 T

Julia E. Bresticker¹, John T. Echols¹, and Frederick H. Epstein¹

¹Biomedical Engineering, University of Virginia, Charlottesville, VA, United States

Keywords: Heart Failure, Fat, T1 Mapping

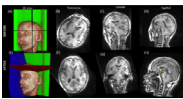
Motivation: Proinflammatory epicardial adipose tissue (EAT) contributes to heart failure (HF). MRI fatty acid composition (FAC) and T₁ of EAT may distinguish proinflammatory vs. healthy EAT. Applying separate FAC and T₁ mapping sequences is time consuming, motivating the development of accelerated methods.

Goal(s): Our goal was to create an accelerated joint EAT FAC and T₁-mapping method (FACT) for use in mice at 9.4 T.

Approach: An inversion-recovery multi-echo sequence and model-based mapping method was developed with acceleration along orthogonal time dimensions.

Results: Results demonstrate feasibility of the FACT method with approximately rate 12 acceleration.

Impact: The FACT method efficiently and accurately determines both EAT fat composition and T₁ and could be used in-vivo to investigate mechanisms and efficacy of novel therapies targeting proinflammatory EAT in the context of metabolic heart disease.



Deep learning-based automated scan planning for brain MRI

Gaojie Zhu^{1,2}, Xiongjie Shen², and Hua Guo¹

¹Department of Biomedical Engineering, School of Medicine, Tsinghua University, Center for Biomedical Imaging Research, Beijing, China, ²Anke High-tech Co., Ltd, Shenzhen, China

Keywords: Analysis/Processing, Brain, automatic scan planning

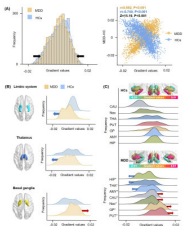
Motivation: Manual scan planning in clinical MRI is inaccurate, inconsistent and time-consuming.

Goal(s): A deep learning-based end-to-end automated scan planning framework has been developed for MRI head scans.

Approach: We propose a two-stage end-to-end 3D cascaded convolutional network framework, called 3D CFP-UNet, which localizes the positions of five key anatomical landmarks and achieves a coarse-to-fine result. We also propose loss functions PRL and DRL with physical meaning in automatic scan planning.

Results: Our approach yields satisfactory scan planning results on 229 test subjects, with PAE and PRE reaching 0.872mm and 0.10%, respectively.

Impact: MRI automated scan planning can help improve scan efficiency. Also, it improves scan consistency for follow-up comparisons.



Cognition-related connectome gradient dysfunctions of thalamus and basal ganglia in drug-naïve first-episode major depressive disorder

Qian Zhang¹, Youjin Zhao¹, Aoxiang Zhang¹, Lizhou Chen¹, and Qiyong Gong¹

¹Huaxi MR Research Center (HMRR), Department of Radiology, West China Hospital of Sichuan University, Chengdu, China

Keywords: Psychiatric Disorders, Psychiatric Disorders, major depressive disorder, fMRI, functional gradient, subcortical structure, cognition

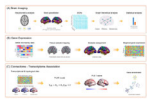
Motivation: The continuous spatial patterns of inter-region connectivity within the subcortical network still remain less well-understood in MDD.

Goal(s): Using functional gradient mapping, a novel approach to identify hierarchical organization of functional networks, we aim to evaluate multiscale subcortical gradients in MDD and their association with cognition.

Approach: Subcortical gradient alterations at the global-, system-, and subregion-levels and their relation to neuropsychological functioning were assessed in MDD patients relative to healthy controls.

Results: Principal gradient values were lower in thalamic and limbic systems but higher in basal ganglia in MDD. Interactions between thalamic and basal ganglia gradient alterations were implicated in MDD-related memory impairments.

Impact: Multiscale subcortical gradient alterations can enhance our understanding of MDD-related hierarchical disturbances in subcortical function and may provide useful clinical biomarkers for cognitive impairments in MDD.



Brain connectomic and transcriptional signatures of suicidal thoughts and behaviors in major depressive disorder

Kun Qin^{1,2}, Huiru Li³, Rui Hu¹, Lisha Zhang², Cunqing Kong¹, Wen Chen¹, Qiyong Gong², and Zhiyun Jia²

¹Department of Radiology, Taihe Hospital, Hubei University of Medicine, Shiyan, China, ²West China Hospital of Sichuan University, Chengdu, China, ³The First Affiliated Hospital of Kunming Medical University, Kunming, China

Keywords: Psychiatric Disorders, Brain

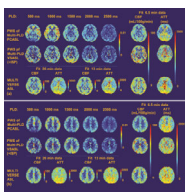
Motivation: Suicide-related connectomic signatures in depression and underlying transcriptional patterns have been poorly understood, most previous findings were limited by small-sample and single-site design.

Goal(s): To identify robust brain structural network deficits associated with suicidal thoughts and behaviors (STB) in major depressive disorder (MDD) and to determine related transcriptional profiles.

Approach: Based on multicenter MRI data of over 700 individuals, group-level connectomic comparisons and connectome-transcriptome association were analyzed.

Results: Robust structural connectomic alterations associated with STB in MDD were distributed in the prefrontal, limbic and temporal areas. STB-related connectomic alterations were spatially correlated with genes enriched for cellular metabolism and synaptic signaling.

Impact: These findings reveal a robust pattern of brain structural deficits at network level and demonstrate its linkage to gene expression patterns, which provides novel insights into the neurobiological underpinnings and potential markers for prediction and prevention of STB.



MULTi-TImepoint VELOCITY-selective Reconciled with Spatially-sElective (MULTIVERSE) ASL: Pushing the Limit of Arterial Transit Time

Feng Xu^{1,2}, Dapeng Liu^{1,2}, Dan Zhu^{1,2}, Anja Soldan³, Marilyn Albert³, Martin Lindquist⁴, Doris D. M. Lin¹, and Qin Qin^{1,2}

¹The Russell H. Morgan Department of Radiology and Radiological Science, Johns Hopkins University, Baltimore, MD, United States, ²F.M. Kirby Research Center for Functional Brain Imaging, Kennedy Krieger Institute, Baltimore, MD, United States, ³Department of Neurology, Johns Hopkins University, Baltimore, MD, United States, ⁴Department of Biostatistics, Johns Hopkins University, Baltimore, MD, United States

Keywords: Arterial Spin Labelling, Perfusion, Cerebral blood flow, arterial transit time, multi time point, arterial spin labeling

Motivation: Existing multi-timepoint arterial spin labeling (ASL) methods can only estimate cerebral blood flow (CBF) and arterial transit time (ATT) with a limited range of ATT (<2000ms).

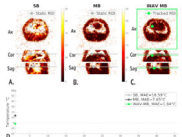
Goal(s): Improve quantification of CBF and ATT for a wide range of ATT.

Approach: MULTIVERSE ASL applies combined fitting of multi-PLD pseudo-continuous (PC) ASL and multi-PLD velocity-selective (VS) ASL to measure CBF and ATT.

Results: With the same scan time, MULTIVERSE ASL improved the accuracy and precision and reduced uncertainty in CBF and ATT quantification across an extended range of ATT (500-4000ms).

Impact: This novel and straightforward approach improves perfusion measurement over the extended range of arterial transit time which was not possible with existing ASL methods. It highlights the clinical potential of ASL-based perfusion mapping in various altered physiological and pathological conditions.

1277



Dynamic 3D Thermometry in Moving Tissue using Accelerated Stack-of-Radial MRI and an Image-Navigated Multi-Baseline PRF Method

Qing Dai¹, Shu-Fu Shih¹, Omar Z. Curiel², Jason Chiang¹, David S. K. Lu¹, Tsu-Chin Tsao², and Holden H. Wu¹

¹Radiology, University of California, Los Angeles, Los Angeles, CA, United States, ²Mechanical And Aerospace Engineering, University of California, Los Angeles, Los Angeles, CA, United States

Keywords: Thermometry/Thermotherapy, MR-Guided Interventions, Liver, Motion Correction, Radial MRI, Focused Ultrasound

Motivation: MRI thermometry faces challenges in moving tissues: intra- and inter-scan motion, limited spatio-temporal resolution, and constrained spatial coverage. These obstacles result in temperature mis-calculations, compromising treatment safety and efficacy.

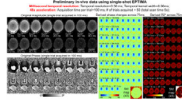
Goal(s): To develop an image-navigated 3D thermometry method to simultaneously track respiratory motion and temperature in moving tissue.

Approach: A stack-of-radial sequence was combined with compressed sensing reconstruction to obtain dynamic 3D images. An image-navigated multi-baseline proton resonance frequency shift (PRF) method was developed to generate motion-resolved temperature maps with tissue tracking.

Results: The proposed method achieved 24-30 slice coverage with a temporal resolution <1 second/volume and mean absolute error <2 degrees during motion.

Impact: The proposed method could improve the safety and efficacy of MRI-guided thermal therapies through reliable temperature monitoring in moving tissues. The capability to simultaneously track motion and temperature evolution enables feedback control, including focused ultrasound beam steering in moving organs.

1289



EPTIMA: Echo Planar Time-resolved Imaging derived Millisecond-scale temporal resolution Acquisition

Zijing Dong^{1,2}, Abbas Sohrabpour^{1,2}, Lawrence L. Wald^{1,2,3}, Jonathan R. Polimeni^{1,2,3}, Padmavathi Sundaram^{1,2}, and Fuyixue Wang^{1,2}

¹Athinoula A. Martinos Center for Biomedical Imaging, Massachusetts General Hospital, Charlestown, MA, United States, ²Department of Radiology, Harvard Medical School, Boston, MA, United States, ³Harvard-MIT Division of Health Sciences and Technology, Massachusetts Institute of Technology, Cambridge, MA, United States

Keywords: fMRI Acquisition, Data Acquisition, fMRI

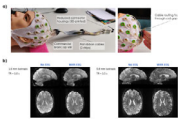
Motivation: Achieving millisecond-scale temporal resolution MRI has the potential to provide exciting insights into fast functional/physiological processes of the brain.

Goal(s): Develop a new acquisition method, EPTIMA, that can achieve millisecond-scale temporal resolution, while improving efficiency by acquiring a time-series trial of 2D-images in a single excitation for high robustness to physiological-noise/motion.

Approach: EPTIMA captures fast temporal dynamics occurring within the readout by measuring the rate at which the baseline signal evolution is changing, and employs spatiotemporal encodings to acquire a complete time-series trial in a single-excitation.

Results: EPTIMA can image rapid electric current changes in a phantom and resolve stable phase/magnitude changes in-vivo.

Impact: A new acquisition, EPTIMA, was developed to achieve millisecond-scale temporal resolution and to image ultra-fast dynamic processes of human brain. It improves efficiency by acquiring a time-series trial of 2D-images in a single excitation with high robustness to motion/physiological noises.



Simultaneous EEG-fMRI at 7T with adapted EEG leads and reference sensors for high-quality, high-resolution imaging: human evaluation

Cristina Sainz Martinez^{1,2}, Jonathan Wirsich³, Serge Vulliémot³, Mathieu Lemay¹, Jessica Bastiaansen^{4,5}, Roland Wiest⁶, and João Jorge¹

¹CSEM - Swiss Center for Electronics and Microtechnology, Bern, Switzerland, ²CIBM Center for Biomedical Imaging, Lausanne, Switzerland, ³EEG and Epilepsy Unit, Department of Clinical Neurosciences, University Hospitals and University of Geneva, Geneva, Switzerland, ⁴Department of Diagnostic, Interventional and Pediatric Radiology, Bern University Hospital, University of Bern, Bern, Switzerland, ⁵Translational Imaging Center (TIC), Swiss Institute for Translational and Entrepreneurial Medicine, Bern, Switzerland, ⁶Institute of Diagnostic and Interventional Neuroradiology, Bern University Hospital, University of Bern, Bern, Switzerland

Keywords: Multimodal, High-Field MRI, EEG, fMRI, EEG-fMRI, 7T, laminar


Motivation: The combination of BOLD-fMRI at 7T with EEG could bring novel insights to neuroscience. However, the combination has remained challenging due to accentuated artifacts and RF-coil constraints.

Goal(s): To implement a first-of-its-kind 7T EEG-fMRI framework combining key developments from recent studies, and assess its safety, data quality and functional sensitivity in humans.

Approach: Extensive tests in phantom and humans(N=8) including field mapping, structural MRI and fMRI (1.6 and 0.8mm-resolution) acquired with+without EEG. Comparisons of data quality and functional sensitivity.

Results: The framework proved safe and feasible with fMRI down to sub-mm resolution, with moderate quality losses and potentially negligible impact on functional sensitivity.

Impact: This study characterizes the feasibility of 7T-EEG-fMRI with high sensitivity and acceleration capabilities, which could bring valuable insights to research in e.g. laminar functional connectivity, or localization of epileptogenic sources and their propagation pathways, for clinical diagnostic and pre-surgical planning.



A Positive and Negative Learning based Image Decomposition Network for Phase Unwrapping and Background Removal

Lijun Bao¹ and Zijun Zhao¹

¹Department of Electronic Science, Xiamen University, Xiamen, China

Keywords: Quantitative Imaging, Quantitative Imaging, phase processing, background removal, deep learning, image decomposition, phase unwrapping

Motivation: Phase images contain important information useful in many fields. However, the phase data is often wrapped into a specific range, while background or noise signal in imaging scene may bring significant interference.


Goal(s): To obtain the exact information, phase images need an accurate processing that includes the unwrapping and the background removal.

Approach: In this paper, we propose a positive and negative learning based image decomposition network (PNnet) to accomplish the phase processing by a single network.

Results: Experimental results demonstrate that PNnet can achieve excellent performance and efficient generalization, even for complex wrapping and inhomogeneous background.

Impact: Except magnitude images, phase data in MRI also contain important information that is useful in many fields and scenarios. This work proposed a SOTA method for phase processing with high accuracy and excellent performance.

1376



A quantitative 2D time-of-flight (qTOF) MR angiography technique for measuring single-vessel blood flow and diameter

Yuhan Ma¹, Jacob D. Horne², and Avery J. L. Berman^{1,3}

¹Department of Physics, Carleton University, Ottawa, ON, Canada, ²Department of Mechanical & Aerospace Engineering, Carleton University, Ottawa, ON, Canada, ³University of Ottawa Institute of Mental Health Research, Royal Ottawa Mental Health Centre, Ottawa, ON, Canada

Keywords: Blood Vessels, Blood vessels, Velocity & flow; Vessel size

Motivation: To address the gap in MRI techniques for assessing cerebral small vessels with slow flow non-invasively.

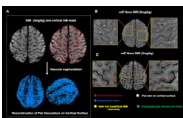
Goal(s): To develop a quantitative 2D time-of-flight (qTOF) technique for measuring blood velocity and the size of cerebral small vessels.

Approach: We developed an analytic qTOF framework to generate realistic TOF model images, which are optimized to match the acquired TOF images for extracting blood velocity and vessel size.

Results: The proposed qTOF framework was validated in simulation and phantom studies, and demonstrated *in vivo*. Incorporating a second acquisition improved blood velocity and vessel size estimation. Flow velocities were comparable to those measured by phase-contrast MRI.

Impact: A quantitative Time-of-Flight technique was developed to provide insights into blood flow and the size of cerebral small vessels, and dynamically in response to changing brain activity, helping to elucidate the role of cerebral small vessels in healthy brain function.

1383



In vivo mapping of the intra-cortical vasculature and layer-specific changes in $\Delta\chi$ and $\Delta R2^*$ of human cerebral cortex using USPIO-MRI at 7T

Chenyang Li^{1,2,3}, Yongsheng Chen⁴, Sagar Buch⁴, Zhe Sun^{1,2,3}, Li Jiang^{1,2}, Marco Muccio^{1,2}, E. Mark Haacke^{4,5}, and Yulin Ge^{1,2}

¹Bernard and Irene Schwartz Center for Biomedical Imaging, Department of Radiology, New York University Grossman School of Medicine, New York, NY, United States, ²Center for Advanced Imaging Innovation and Research (CAI2R), Department of Radiology, New York University Grossman School of Medicine, New York, NY, United States, ³Vilcek Institute of Graduate Biomedical Sciences, New York University Grossman School of Medicine, New York, NY, United States, ⁴Department of Neurology, Wayne State University School of Medicine, Detroit, MI, United States, ⁵Department of Radiology, Wayne State University School of Medicine, Detroit, MI, United States

Keywords: Blood Vessels, Blood vessels

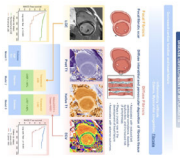
Motivation: In vivo imaging of intra-cortical vessels of human brain, including penetrating arteries, veins and capillary density are still scarce.

Goal(s): To reconstruct the in vivo intra-cortical vessels of the human brain and estimate the cortical layer-specific changes in susceptibility (χ) in the presence of superparamagnetic iron oxides.

Approach: With aid of Ferumoxytol at 7T, high resolution gradient echo imaging was implemented to reconstruct pre-/post-SWI, $R2^*$ and χ maps.

Results: Intra-cortical penetrating arteries and veins can be differentiated by pre- and post-contrast SWI. Changes in $R2^*$ and χ revealed variations reflective of capillary density across different layers, which is in agreement with histological findings.

Impact: This study provides in vivo imaging characterization of intra-cortical vessels of human brain using high-resolution Ferumoxytol-enhanced SWI at 7T. Utilizing changes in $R2^*$ and χ enables us delve deeper into the laminar distribution of capillary density across various cortical layers.



T1 Mapping and Extracellular Volume Fraction in Patients with Suspected Acute Myocarditis: A Prognosis Study

Yining Wang^{1,2}, Kelvin Chow³, Jing An⁴, Shihua Zhao¹, and Minjie Lu^{1,5}

¹Fuwai Hospital, Peking Union Medical College, Chinese Academy of Medical Sciences, Beijing, China, ²Chinese Academy of Medical Sciences (CAMS) and Peking Union Medical College (PUMC), Beijing, China, ³Siemens Healthineers, Los Angeles, CA, United States, ⁴Siemens Shenzhen Magnetic Resonance Ltd., Shenzhen, China, ⁵Key Laboratory of Cardiovascular Imaging (Cultivation), Chinese Academy of Medical Sciences, Beijing, China

Keywords: Inflammation, Infiltration, Heart

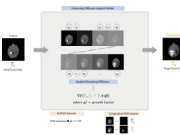
Motivation: The prognostic value of T1 mapping and extracellular volume fraction (ECV) in acute myocarditis has not yet been supported by high-quality, evidence-based medicine.

Goal(s): To investigate the prognostic value of T1 mapping and ECV in patients with acute suspected myocarditis.

Approach: Patients meeting the recommended clinical criteria for suspected myocarditis were enrolled. The potential value for predicting MACE was explored using Cox proportional hazards models.

Results: Patients with MACE showed higher global native T1 and ECV z scores and were more likely to have tissue changes in interventricular septum. Quantitative mapping parameters have incremental prognostic value beyond clinical variables and conventional CMR parameters.

Impact: Our study reveals the prognostic predictive ability of native T1 and ECV in myocarditis. The application of mapping techniques will further contribute to the understanding of the pathophysiology of heart disease and will guide the development of effective therapeutic approaches.



Predicting Anatomical Tumor Growth in Pediatric High-grade Gliomas via Denoising Diffusion Models

Daria Laslo¹, Maria Monzon¹, Divya Ramakrishnan², Marc von Reppert², Schuyler Stoller³, Ana Sofia Guerreiro Stücklin⁴, Nicolas U. Gerber⁴, Andreas Rauschecker⁵, Javad Nazarian⁴, Sabine Mueller⁵, Catherine Jutzeler¹, and Sarah Brueningk¹

¹ETH Zurich, Zurich, Switzerland, ²Yale University, New Haven, CT, United States, ³École Polytechnique Fédérale de Lausanne, Lausanne, Switzerland, ⁴Kinderspital Zurich, Zurich, Switzerland, ⁵University of California San Francisco, San Francisco, CA, United States

Keywords: AI Diffusion Models, Machine Learning/Artificial Intelligence, Oncology, Cancer, DMG, Diffuse Midline Glioma

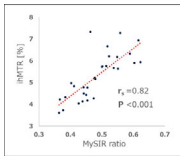
Motivation: Pediatric diffuse midline gliomas are associated with a poor prognosis, leaving radiotherapy as standard of palliative care. Personalized radiation regimes could maximize the benefit for the patient, and consequently improve clinical outcomes.

Goal(s): This study explores a state-of-the-art computer vision method to predict the anatomical growth of tumors which could inform tailored radiotherapy treatments.

Approach: A denoising diffusion implicit model is employed to generate realistic, high-quality magnetic resonance imaging scans of enlarged tumor sizes starting from a baseline image.

Results: Our proof-of-concept study demonstrates promising results on an external longitudinal pediatric dataset, highlighting the method's potential to realistically predict visual tumor growth.

Impact: We demonstrate realistic predictions of anatomical (pediatric) brain tumor growth using a generative denoising diffusion implicit model. This enables personalized predictions of tumor growth trajectories to guide localized therapies such as geometric dose shaping for radiotherapy delivery.



Myelin-sensitive inversion recovery (MySIR) for quantification of myelin in the peripheral nerve

Takayuki Sada¹, Hajime Yokota², Keisuke Nitta¹, Ryuna Kurosawa¹, Hirotaka Sato¹, Koji Matsumoto¹, Takashi Namiki³, Masami Yoneyama³, Guillaume Gilbert⁴, Yoshitada Masuda¹, and Takashi Uno²

¹Department of Radiology, Chiba University Hospital, Chiba, Japan, ²Diagnostic Radiology and Radiation Oncology, Graduate School of Medicine, Chiba University, Chiba, Japan, ³Philips Japan, Tokyo, Japan, ⁴Philips Canada, Mississauga, ON, Canada

Keywords: Peripheral Nerves, Neurography

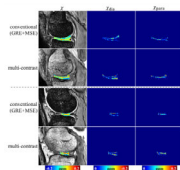
Motivation: Quantification of myelin in peripheral nerves remains challenging.

Goal(s): To evaluate new imaging techniques that quantify myelin in the peripheral nerve.

Approach: Myelin-sensitive inversion recovery (MySIR) was compared with inhomogeneous magnetization transfer (ihMT) for its ability to reflect myelin value and spatial resolution in the peripheral nerve.

Results: Myelin values of MySIR and ihMT were strongly correlated. MySIR had a better ability to visualize nerve fascicles than ihMT.

Impact: MySIR could quantify myelin while maintaining high spacial resolution in peripheral nerves.



Subvoxel QSM of human knee cartilage: a preliminary study

Ming Zhang¹, Guoyan Lao¹, and Hongjiang Wei^{1,2}

¹School of Biomedical Engineering, Shanghai Jiao Tong University, Shanghai, China, ²The National Engineering Research Center of Advanced Magnetic Resonance Technologies for Diagnosis and Therapy (NERC-AMRT), Shanghai Jiao Tong University, Shanghai, China

Keywords: Susceptibility/QSM, Quantitative Susceptibility mapping, subvoxel QSM


Motivation: Subvoxel QSM could be beneficial for assessing the knee cartilage but requires two separate sequences for reconstruction by using APART-QSM.

Goal(s): To achieve subvoxel QSM reconstruction of knee cartilage in a single scan.

Approach: A multi-contrast framework was used to simultaneously estimate T_1 , T_2 and T_2^* mapping in one scan. The magnitude and phase images were generated based on the signal equation. The preprocessed phase and $R_2^* = \frac{1}{T_2^*} - \frac{1}{T_2}$ were used for subvoxel QSM reconstruction. The results were compared with conventional approach using two sequences (GRE+MSE).

Results: The subvoxel QSM results using the multi-contrast framework have good agreement with the conventional condition.

Impact: The diamagnetic and paramagnetic susceptibility source separation of the knee cartilage could be achieved in a single scan using a multi-contrast framework. This technique can provide specific information to assess the tissue magnetic properties of the knee cartilage.



Phase-Resolved Functional Lung MRI Reveals Perfusion Abnormalities in Postacute COVID-19 Syndrome

Tao Ouyang¹, Andreas Voskrebenez², Jens Vogel-Claussen², Chen Zhang³, and Qi Yang¹

¹Department of Radiology, Beijing Chaoyang Hospital, Capital Medical University, Beijing 100020, China, Beijing, China, ²Institute for Diagnostic and Interventional Radiology, Hannover Medical School, Hannover, Germany, Hannover, Germany, ³MR Research Collaboration, Siemens Healthineers, Beijing, China, Beijing, China

Keywords: Visualization, Lung

Motivation: The Pulmonary perfusion defects were unknown in post-acute COVID-19 syndrome (PACS).

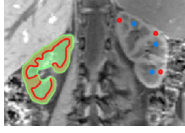Goal(s): To investigate the utility of phase-resolved functional lung (PREFUL) MRI in detecting pulmonary perfusion disturbances in PACS.

Approach: Participants diagnosed with PACS were recruited, along with healthy (NCT05933317). The quantified parameter QDP derived from PREFUL MRI represents abnormal pulmonary blood flow.

Results: 44 participants with PACS, and 43 healthy were assessed. QDP significantly exceeded healthy controls in PACS ($39.81\% \pm 15.0\%$ vs $8.2\% \pm 3.3\%$) and was notably higher in inpatients ($46.8\% \pm 17.0\%$ vs $34.5\% \pm 10.8\%$). Moreover, males exhibited higher QDP than females ($43.9\% \pm 16.8\%$ vs $34.4\% \pm 10.2\%$).

Impact: PREFUL MRI demonstrates notable perfusion defects in participants with PACS.

4815



Test-retest repeatability of renal MRI parameters in healthy volunteers comparing ROI-based and tissue segmentation based image analysis

Cecilia Liang¹, Isabelle Loster², Thomas Küstner^{1,3}, Brigitte Gückel¹, Bernd Kühn⁴, Fritz Schick³, Ferdinand Seith¹, and Petros Martirosian³

¹Department of Diagnostic and Interventional Radiology, University Hospital Tuebingen, Tuebingen, Germany, ²University Tuebingen, Tuebingen, Germany, ³Section on Experimental Radiology, University Hospital Tuebingen, Tuebingen, Germany, ⁴Siemens Healthineers, Erlangen, Germany

Keywords: Kidney, Kidney

Motivation: Multiparametric MRI of the kidneys is a promising technique for renal diagnostics, but the diversity of imaging protocols and analysis strategies hinders clinical translation.

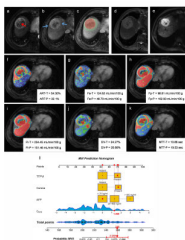
Goal(s): Our goal was to assess the repeatability of a multiparametric MRI protocol comparing ROI-based and tissue segmentation based analysis.

Approach: Ten volunteers were examined with a multiparametric MRI protocol including ASL, IVIM, BOLD, T1 and T2 mapping twice with one week between visits.

Results: Good repeatability of the multiparametric protocol could be achieved. T1 and T2 values showed less variability compared to perfusion and diffusion related functional parameters. Tissue segmentation showed better repeatability compared to ROI-based analysis.

Impact: Our study demonstrates relatively high repeatability of multiparametric functional MRI of the kidneys. The results of the image analysis methods suggest, that manual segmentation is to be preferred over ROI-based analysis, if automated segmentation is not available.

4816



Bi-regional quantitative DCE-MRI for prediction of microvascular invasion in hepatocellular carcinoma and its significance for treatment

Yongjian Zhu¹, Peng Wang¹, Wei Cai¹, Bingzhi Wang², Xuan Meng³, Sicong Wang⁴, and Xiaohong Ma¹

¹Department of Diagnostic Radiology, National Cancer Center/National Clinical Research Center for Cancer/Cancer Hospital, Chinese Academy of Medical Sciences and Peking Union Medical College, Beijing, China, ²Department of Pathology, National Cancer Center/National Clinical Research Center for Cancer/Cancer Hospital, Chinese Academy of Medical Sciences and Peking Union Medical College, Beijing, China, ³Department of Hepatobiliary Surgery, National Cancer Center/National Clinical Research Center for Cancer/Cancer Hospital, Chinese Academy of Medical Sciences and Peking Union Medical College, Beijing, China, ⁴GE Healthcare, MR Research China, Beijing, China

Keywords: Liver, Liver

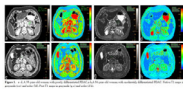
Motivation: Accurately predicting microvascular invasion (MVI) risk in hepatocellular carcinoma before surgery could aid clinicians in selecting appropriate surgical approaches to improve the patient's prognosis.

Goal(s): To construct DCE-MRI based nomogram for predicting MVI, and to assess its ability for stratifying the risk of recurrence after hepatectomy and guiding surgical approaches.

Approach: Quantitative DCE-MRI parameters from both intra-tumoral region (ITR) and peritumoral region (PTR), along with clinical-radiological (CR) features, were utilized to establish the nomogram.

Results: The nomogram presented AUC values of 0.966 in the training and 0.937 in the validation set for predicting MVI. High-risk patients could obtain survival benefit from anatomical resection.

Impact: We constructed and evaluated the performance of the bi-regional quantitative DCE-MRI based nomogram for predicting MVI risk in HCC. Our predictive model effectively predicts MVI risk and assists clinicians in selecting appropriate therapeutic strategies for patients.



The value of Native T1 mapping in identifying pancreatic ductal adenocarcinomas with different degree of pathological differentiation

Kai Li¹, HaiYan Chen¹, Lei Shi¹, Rong Li Tang¹, and Shan Huang²

¹Zhejiang Cancer Hospital, Hangzhou City, Zhejiang Province, China, ²Philips Healthcare, Shanghai, China

Keywords: Cancer, Relaxometry, T1-mapping

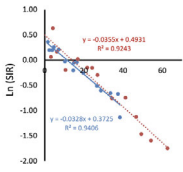
Motivation: MRI quantitative technique T1 mapping can reflect the change of intrinsic information of tissues

Goal(s): To explore the value of T1 mapping in PDCA with different degrees of differentiation

Approach: Comparison of PDCA with different degrees of differentiation, the T1 relaxation time before and after enhancement

Results: by comparing the T1 mapping values before and after enhancement of PDAC with different degrees of differentiation, it was found that as the degree of differentiation of PDAC was getting higher, the Native T1 value showed a tendency to increase. The Native T1 was moderately positively correlated with the degree of pathological differentiation

Impact: T1 mapping may serve as a noninvasive means of predicting the degree of pathologic differentiation of PDAC before surgery. Give clinicians earlier information.



Field and TE independent liver iron concentration estimation using signal intensity ratios

Eamon C Doyle¹ and John C Wood²

¹Radiology, Children's Hospital of Los Angeles-USC KSOM, Los Angeles, CA, United States, ²Pediatrics and Radiology, Children's Hospital of Los Angeles-USC KSOM, Los Angeles, CA, United States

Keywords: Liver, Relaxometry, Iron Overload

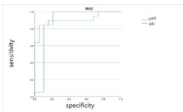
Motivation: Estimation of liver iron concentration by R2* relaxation (LIC_{R2*}) is a powerful and widely used technique, however, it may fail from signal loss at high liver iron concentration.

Goal(s): To estimate LIC from a single-TE liver-muscle signal intensity ratio (LIC_{SIR}) and validate at 1.5 and 3.0 Tesla.

Approach: Using LIC_{R2*} estimates collected at 1.5T as a reference, we compared LIC_{SIR} estimates in 15 subjects who had undergone MRI examination at both 1.5T and 3.0T.

Results: We were able to derive field-independent scaling constants that allow LIC_{SIR} estimation at 1.5 and 3.0T, more than doubling the effective dynamic range of LIC_{R2*} estimation.

Impact: This generalized framework for LIC_{SIR} estimation allows reasonable LIC values to be reported (and trended) in patients for whom traditional relaxometry has failed. It also allows approximate LIC calculation from commonly used single and dual echo gradient echo acquisitions.



Value of placental stiffness using virtual magnetic resonance elastography in pregnancies complicated by pre-eclampsia

Jialu Xu¹ and Jiejun Cheng¹

¹Department of Radiology, Shanghai First Maternity and Infant Hospital, Tongji University, Shanghai, China

Keywords: Placenta, Placenta

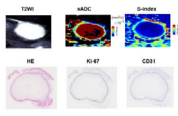
Motivation: To evaluate virtual magnetic resonance elastography in healthy and preeclamptic(PE) pregnancies.

Goal(s): To compare the stiffness value (μ_{diff}) and apparent diffusion coefficient (ADC) in healthy and PE pregnancies.

Approach: DWI(b-value of 50, 200 and 800 s/mm²) were performed on all pregnant women using a 1.5 T MRI scanner. The value of μ_{diff} and ADC were calculated and compared between groups.

Results: The mean ADC value of the control and PE groups were $1.414 \pm 0.228 \times 10^{-3}$ mm²/s and $1.737 \pm 0.107 \times 10^{-3}$ mm²/s, respectively. The mean μ_{diff} value of PE were 5.901 ± 1.757 and 4.618 ± 2.055 kPa, respectively. The area under the curve for μ_{diff} was 0.903 and ADC was 0.796, respectively.

Impact: Placental μ_{diff} value was found to be more reliable than ADC in differentiating between normal and preeclampsia placentas.



DWI Parameters Correlated with Ki-67 Expression, a Prognostic Biomarker, in a Triple-Negative Breast Cancer PDX Mouse Model

Mami Iima^{1,2}, Marino Akamatsu³, Hirohiko Imai⁴, Hana Suzuki³, Noriko Gotoh⁵, Yasuto Takeuchi⁵, Maya Honda¹, Tomomi Nobashi¹, Masako Kataoka¹, Akihiko Yoshizawa⁶, Hiroaki Ito⁷, Tomoe Nakagawa⁸, Minsoo Kim⁹, Denis Le Bihan^{10,11}, and Yuji Nakamoto¹

¹Diagnostic Imaging and Nuclear Medicine, Kyoto University Graduate School of Medicine, Kyoto, Japan, ²Institute for Advancement of Clinical and Translational Science (iACT), Kyoto University Hospital, Kyoto, Japan, ³Faculty of Medicine, Kyoto University, Kyoto, Japan, ⁴Department of Systems science, Graduate School of Informatics, Kyoto University, Kyoto, Japan, ⁵Cancer Research Institute, Kanazawa University, Kanazawa, Japan, ⁶Diagnostic Pathology, Nara Medical University, Nara, Japan, ⁷Diagnostic Pathology, Kyoto University Graduate School of Medicine, Kyoto, Japan, ⁸Department of Pathology and Tumor Biology, Kyoto University Graduate School of Medicine, Kyoto, Japan, ⁹Laboratory of Integrative Molecular Medicine, Kyoto University Graduate School of Medicine, Kyoto, Japan, ¹⁰Human Brain Research Center, Kyoto University Graduate School of Medicine, Kyoto, Japan, ¹¹CEA-Saclay, Paris-Saclay University, NeuroSpin, Gif/Yvette, France

Keywords: Cancer, Breast


Motivation: The lack of reliable biomarkers for assessing tumor characteristics and the limitations of histological analysis due to tumor heterogeneity led to the exploration of diffusion-weighted parameters.

Goal(s): To investigate the association between DW parameters and Ki-67 expression in triple-negative breast cancer, with a focus on whether they can serve as prognostic biomarkers.

Approach: Seventeen triple-negative breast cancer mice with a PDX model underwent 7T MRI scans, yielding DW images. Advanced analysis evaluated ADC and non-Gaussian diffusion parameters, validated through histological Ki-67 staining.

Results: DWI parameters (S-index, sADC, and ADC₀) show strong correlations with Ki67 levels, at short and long diffusion times (9, 27.6ms).

Impact: Promising prognostic biomarkers for triple-negative breast cancer, DWI parameters (S-index, sADC, and ADC₀) displayed strong correlations with Ki-67 expression, at short and long diffusion times. This validation through accurate DWI-pathology comparison highlights imaging's pivotal role in advancing breast cancer diagnosis.



The value of IVIM-DWI and DCE-MRI in predicting molecular subtypes of breast cancer

Ting-ting Lin¹

¹The First Affiliated Hospital of USTC (Anhui Provincial Cancer Hospital), Hefei, China

Keywords: Breast, Cancer, molecular subtypes


Motivation: To analyze the value of imaging examination in accurate diagnosis of breast cancer.

Goal(s): Provide a non-invasive examination for the prediction of molecular subtypes of breast cancer before treatment.

Approach: The quantitative parameters of IVIM-DWI and DCE-MRI in patients with breast cancer without any invasive examination and treatment were compared with pathological molecular subtypes, so as to analyze their diagnostic value in the prediction of molecular subtypes.

Results: DCE-MRI and IVIM-DWI were correlated with immune prognostic factors of breast cancer and had differential diagnostic value for different molecular subtypes.

Impact: DCE-MRI and IVIM-DWI could provide a non-invasive diagnostic method for predicting molecular subtypes of breast cancer and provide a reference for further development of personalized treatment plans.



Quantitative Imaging Habitat Risk Score (HRS) Combined with PI-RADSv2 Improves Predictive Value of Prostate Lesion Identification on mpMRI

Veronica Wallaengen¹, Adrian L Breto¹, Isabella M Kimbel¹, Evangelia I Zacharaki¹, Ahmad Algohary¹, Nachiketh Soodana Prakash², Sandra M Gaston¹, Rosa P Castillo Acosta³, Oleksandr N Kryvenko⁴, Bruno Nahar², Dipen J Parekh², Alan Pollack¹, Sanoj Punnen², and Radka Stoyanova¹

¹Department of Radiation Oncology, University of Miami Miller School of Medicine, Miami, FL, United States, ²Department of Urology, University of Miami Miller School of Medicine, Miami, FL, United States, ³Department of Radiology, University of Miami Miller School of Medicine, Miami, FL, United States, ⁴Department of Pathology, University of Miami Miller School of Medicine, Miami, FL, United States

Keywords: Software Tools, Cancer

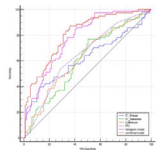
Motivation: Discrimination between true and false positive targets identified using PI-RADSv2 is needed to avoid unnecessary biopsies.

Goal(s): To investigate how quantitative analysis of prostate mpMRI through Habitat Risk Scoring (HRS) combined with PI-RADS can improve prostate lesion identification compared to using PI-RADS alone.

Approach: In prospective clinical trials lesions identified by PI-RADS and/or HRS were targeted through MRI/ultrasound fusion biopsies.

Results: Using HRS yields 100% NPV in the PI-RADS 3 cohort and increases PPV by 7.4% in the PI-RADS 4-5 cohort with respect to clinically significant cancer. Overall, the NPV and PPV increased by 21.4% and 13.2% respectively.

Impact: We present a quantitative imaging approach to complement the current standard for assessing prostate cancer risk in mpMRI data and demonstrate that the use of HRS strengthens fidelity in both positive and negative detections.



Intravoxel incoherent motion diffusion-weighted imaging in diagnosing perineural invasion status of rectal cancer: a histogram analysis study

Rong He¹, Gesheng Song¹, Junyi Fu¹, Weiqiang Dou², Aiyin Li¹, and Jingbo Chen³

¹Department of Radiology, The First Affiliated Hospital of Shandong First Medical University & Shandong Provincial Qianfoshan Hospital, Jinan, China, ²GE Healthcare, MR Research, Beijing, China, ³Department of General Surgery, The First Affiliated Hospital of Shandong First Medical University & Shandong Provincial Qianfoshan Hospital, Jinan, China

Keywords: fMRI Analysis, Diffusion/other diffusion imaging techniques, histogram analysis

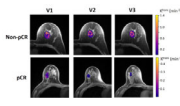
Motivation: Currently, perineural invasion (PNI) of rectal cancer (RC) can only be confirmed by pathological examination of postoperative specimens.

Goal(s): It aimed to investigate the intravoxel incoherent motion (IVIM) diffusion-weighted imaging (DWI) in diagnosing the PNI status of RC by histogram analysis.

Approach: We extracted histogram features from 7 parametric maps derived from IVIM-DWI. The independent predictive histogram features of rectal cancer PNI were combined with the percentage of rectal wall enclosure (PCI) reported by MRI to construct a combined model for preoperative diagnosis of PNI.

Results: The AUC of the combined model is higher than that of each single-parameter model and histogram model.

Impact: This study demonstrated that full-volume histogram parameters basing on IVIM-DWI can be used to assess PNI status in rectal cancer. Histogram analysis, as a non-invasive tool, may be more valuable not only in rectal cancer research in the future.



Multi-Center and Multi-Vendor Platform DCE-MRI Prediction of Breast Cancer Therapy Response: A Preliminary Comparison of Imaging Biomarkers

Brendan Moloney¹, Xin Li¹, Michael Hirano², Assim Saad Eddin³, Jeong Youn Lim¹, Debosmita Biswas², Anum S. Kazerouni², Alina Tudorica¹, Isabella Li², Mary Lynn Bryant², Courtney Wille³, Chelsea Pyle¹, Habib Rahbar², Su Kim Hsieh³, Travis Rice-Stitt¹, Suzanne Dintzis², Amani Bashir³, Evthokia Hobbs¹, Alexandra Zimmer¹, Jennifer Specht², Sneha Phadke³, Nicole Fleege³, James Holmes³, Savannah C. Partridge², and Wei Huang¹

¹Oregon Health & Science University, Portland, OR, United States, ²University of Washington, Seattle, WA, United States, ³University of Iowa, Iowa City, IA, United States

Keywords: Treatment Response, Cancer, Multi-Center and Multi-Vendor platform, DCE-MRI, Therapy Response, Ktrans

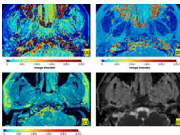
Motivation: Validate Shutter-Speed model (SSM) DCE-MRI as a robust predictor of breast cancer (BC) response to neoadjuvant chemotherapy (NAC) in a multi-center and multi-vendor platform setting.

Goal(s): Compare tumor size, semi-quantitative, and quantitative DCE-MRI for early prediction of NAC response.

Approach: BC patients treated with NAC underwent longitudinal high spatiotemporal resolution DCE-MRI at three sites using a 3T Siemens, GE, or Philips system. Semi-quantitative signal-enhancement-ratio (SER) and quantitative Tofts model (TM) and SSM pharmacokinetic (PK) parameters were derived from DCE time-course data.

Results: PK parameters outperformed size and SER while SSM was superior to TM in early prediction of pathologic response.

Impact: It is feasible to implement quantitative high spatiotemporal resolution SSM DCE-MRI in trials with multi-center and multi-vendor platform settings for robust assessment of BC response to NAC.



Synthetic MRI for the quantitative Assessment of efficacy of Immunotherapy in nasopharyngeal carcinoma.

Yu Huang¹ and Chen ZHAO²

¹Radiology, The First Clinical Medical College of Guangxi Medical University, Nanning, China, ²MR Research Collaboration, Siemens Healthineers., Nanning, China

Keywords: Other Interventional, Quantitative Imaging

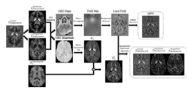
Motivation: Due to the internal heterogeneity of the nasopharyngeal carcinoma, conventional treatment fails to enhance the tumor microenvironment, ultimately leading to recurrence or metastasis.

Goal(s): To investigate whether quantitative values derived from T1, T2, and PD maps can serve as an assessment index for combined immunotherapy with chemotherapy in patients with newly diagnosed locally advanced NPC.

Approach: Synthetic MRI, non-invasive technique, can generate quantitative values for intrinsic tissue features.

Results: The study indicate the potential of PD and T2 values in distinguishing between two treatment. A larger sample size is required to further validate the value of SyMRI in evaluating immunotherapy for NPC.

Impact: Synthetic MRI can generate longitudinal relaxation time (T1), transverse relaxation time (T2), and proton density (PD).



A realistic in-silico brain phantom for magnetic susceptibility-separation algorithm validation

Daniel Ridani¹, Benjamin De-Leener^{1,2,3}, and Eva Alonso-Ortiz^{1,3,4}

¹NeuroPoly Lab, Institute of Biomedical Engineering, Polytechnique Montreal, Montreal, QC, Canada, ²Department of Computer and Software Engineering, Polytechnique Montreal, Montreal, QC, Canada, ³CHU Sainte-Justine Research Center, Montreal, QC, Canada, ⁴Department of Electrical Engineering, Polytechnique Montreal, Montreal, QC, Canada

Keywords: Susceptibility/QSM, Quantitative Imaging, Phantoms, QSM, Simulation, Susceptibility, Anisotropy

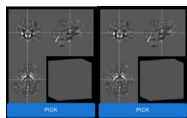Motivation: Positive and negative susceptibility mapping is an emerging method that can benefit from the availability of validation tools.

Goal(s): To create an *in-silico* brain phantom for positive and negative susceptibility and to assess the impact of white matter's anisotropic susceptibility on susceptibility-separation techniques.

Approach: Simulate positive and negative susceptibility maps and gradient-echo data with/without anisotropy. Process simulated data with different susceptibility-separation algorithms. Compare the results with the ground truth.

Results: The error associated with negative susceptibility measurements is ~9% greater when anisotropy effects are present in the phantom, suggesting that a new susceptibility-separation algorithm that considers myelin's anisotropic susceptibility may be warranted.

Impact: Researchers developing novel magnetic susceptibility-separation methods can use our proposed phantom to test different aspects of their technique, ranging from the biophysical model to image processing methods and imaging protocol parameters.



QSM-CI: An automated continuous QSM challenge

Ashley Wilton Stewart¹, Korbinian Eckstein², Thuy Thanh Dao¹, and Steffen Bollmann^{2,3}

¹School of Electrical Engineering and Computer Science, The University of Queensland, Brisbane, Australia, ²School of Electrical Engineering and Computer Science, The University of Queensland, St Lucia, Australia, ³Queensland Digital Health Centre, The University of Queensland, Brisbane, Australia

Keywords: Electromagnetic Tissue Properties, Challenges, Quantitative Susceptibility Mapping


Motivation: Reconstruction challenges for Quantitative Susceptibility Mapping (QSM) offer a common evaluation but are challenging to run and offer only a single snapshot of algorithm performance in time.

Goal(s): To develop a QSM challenge with continuous integration (QSM-CI), enabling automatic, transparent evaluation of community-submitted algorithms across diverse datasets and metrics.

Approach: QSM-CI was implemented using GitHub Actions and a user interface for displaying metrics and collecting community visual ratings, which inform a qualitative Elo metric alongside quantitative assessments.

Results: The QSM-CI prototype implementation is publicly available and has been tested using a range of QSM algorithms.

Impact: QSM-CI will facilitate a QSM challenge that allows for continuous evaluations using current and future datasets, algorithms, and metrics. This ensures the continued accessibility of the challenge and continued relevance as new methods, metrics and test data are made available.



Improved QSM Pipeline to Investigate the Effect of Sickle Cell Anaemia on Brain Magnetic Susceptibility in Tanzanian Children at 1.5 Tesla

Mitchel Lee¹, Russell Murdoch¹, Mboka Jakob², Fenella Kirkham³, and Karin Shmueli¹

¹Department of Medical Physics and Biomedical Engineering, University College London, London, United Kingdom,

²Department of Radiology & Imaging, Muhimbili University of Health and Allied Sciences, Dar Es Salaam, Tanzania,

³Imaging and Biophysics, Developmental Neurosciences, UCL Great Ormond Street Institute of Child Health, London, United Kingdom

Keywords: Gray Matter, Gray Matter


Motivation: Sickle cell anaemia (SCA) is a major global health burden, but disease mechanisms in the brain are not well understood.

Goal(s): To improve a quantitative susceptibility mapping (QSM) pipeline and apply it to updated data to investigate brain susceptibility differences between SCA patients and controls. To investigate correlations between blood haemoglobin and brain magnetic susceptibility.

Approach: QSM was optimised using denoising/masking approaches. Linear regressions of susceptibility against log(age) were used to compare age-corrected susceptibility in grey matter structures across the age range and correlate with haemoglobin.

Results: Susceptibility increases with age differently for SCA vs controls. Haemoglobin was not significantly correlated with susceptibility.

Impact: This work provides novel insight into the relationship between grey matter magnetic susceptibility and sickle cell anaemia, demonstrating differential trajectories with age between SCA patients and healthy controls. This may support the view of SCA as an accelerated aging syndrome.



Open-Source Algorithm for Automatic Magnetic Susceptibility Determination from Field Maps

Niklas Wehkamp¹, Philipp Rovedo¹, Jochen Leupold¹, Sebastien Bär¹, and Maxim Zaitsev¹

¹Division of Medical Physics, Department of Diagnostic and Interventional Radiology, University Medical Center Freiburg, Faculty of Medicine, University of Freiburg, Freiburg, Germany

Keywords: Software Tools, Susceptibility

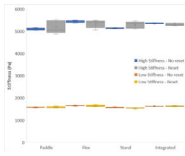
Motivation: The magnetic susceptibility is a fundamental material property for MR and NMR equipment engineering. The literature provides several theoretical solutions to measure the magnetic susceptibility. However, an openly available implementation that allows to determine the magnetic susceptibility automatically is missing.

Goal(s): Develop a non-proprietary approach to determine the magnetic susceptibility from measured field maps.

Approach: Measure the field map of a cylindrical sample. Develop a Python program to extract the magnetic susceptibility of the sample.

Results: The measured reference samples reflect the magnetic susceptibility of the literature. Code for data processing is available through the open access repository.

Impact: Our research provides a programmatic solution to automatically determine the magnetic susceptibility of cylindrical samples from field map measurements in MRI systems. This will aid MR and NMR equipment engineers to measure the magnetic susceptibility of any material of interest.



Comparison of Stiffness Measurement Variability in MRE Phantoms using Different Passive Drivers

Raphael do Vale Souza¹, Jeff Kammerman², David Rutkowski², Jitka Starekova¹, Phillip J. Rossman³, Kay Pepin⁴, Diego Hernando⁵, Jean H. Brittain², and Scott B. Reeder¹

¹Department of Radiology, University of Wisconsin-Madison, Madison, WI, United States, ²Calimetrix, Madison, WI, United States, ³Mayo Clinic, Rochester, MN, United States, ⁴Resoundant, Rochester, MN, United States, ⁵University of Wisconsin-Madison, Madison, WI, United States

Keywords: Phantoms, Phantoms, Elastography, Stiffness

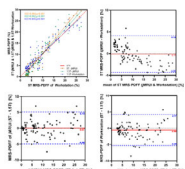
Motivation: Quantitative quality assurance (QA) methods for magnetic resonance elastography (MRE) are needed for clinical care but are currently unavailable.

Goal(s): Evaluate stiffness measurement variability from two phantoms of different stiffness using four types of passive drivers: two commercial drivers, a custom stand-style driver, and a novel driver integrated into the phantom housing.

Approach: Stiffness measurements were quantified in ten acquisitions in two phantoms of differing stiffness by four passive drivers. Measurement variability was compared by standard deviations and Whisker-and-Box plots.

Results: The integrated driver achieved the best performance with the highest repeatability, ie: lowest variability, compared to the other drivers.

Impact: An MRE phantom equipped with an integrated passive driver could improve repeatability in MRE quality assurance, potentially enhancing the reliability of QA processes in both clinical trials and patient care.



An In-Depth Analysis of Liver Fat Quantification Using 5T MRI: A Comparative Study with 1.5T MRI MRS-PDFF

Jianxian Liu¹, Zhensong Wang¹, Dan Yu², Yanxing Yang³, Chao Zou⁴, Chuanli Cheng⁴, Xiangsen Jiang¹, Peng Chen¹, and Jie Gan¹

¹Shandong Provincial Third Hospital, Jinan, China, ²United Imaging Research Institute of Intelligent Imaging, Beijing, China, ³Shanghai United Imaging Healthcare Co., Shanghai, China, ⁴Shenzhen Institutes of Advanced Technology, Chinese Academy of Sciences, Shenzhen, China

Keywords: High-Field MRI, High-Field MRI, Fat & Fat/Water Separation

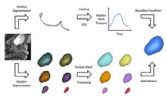
Motivation: Nonalcoholic fatty liver disease (NAFLD) is an escalating health issue, necessitating precise noninvasive measurement of hepatic steatosis.

Goal(s): To evaluate the feasibility and accuracy of 5T magnetic resonance spectroscopy (MRS) for in vivo liver fat quantification.

Approach: The study utilized phantoms with controlled fat content and 20 volunteers, comparing proton density fat fraction (PDFF) values measured by 5T MRS against those from 1.5T MRS.

Results: The 5T MRS demonstrated strong consistency with 1.5T measurements, validating its potential in clinical diagnostics despite technical challenges associated with ultra-high-field MRI applications.

Impact: The study's validation of 5T MRS for liver fat quantification could enhance diagnostic precision for liver conditions, influencing clinical practices and guiding future technological advancements in MRI diagnostics.



Computational Fluid Dynamics Of Bladder Voiding Using 3D Dynamic MRI

Labib Shahid¹, Juan Pablo Gonzalez-Pereira¹, Cody Johnson¹, Wade Bushman¹, and Alejandro Roldan-Alzate¹

¹University of Wisconsin-Madison, Madison, WI, United States

Keywords: In Silico, In Silico, MRI-based CFD, Urodynamics

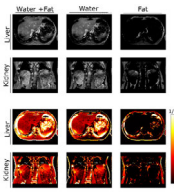
Motivation: Catheter-based urodynamic studies to assess bladder dysfunction are invasive and provide inadequate biomechanical information. MRI-based computational fluid dynamics (CFD) has demonstrated potential to uncover these features not evident from catheterization.

Goal(s): Develop and implement a computational methodology to non-invasively assess urodynamics.

Approach: Acquire 3D dynamic MRI of bladder voiding. Use the images to execute subject-specific CFD simulations of the bladder and urethra. Calculate existing urological nomograms and energy expended to quantify bladder function using the MRI and CFD results.

Results: The healthy subject showed unobstructed bladder outlet and normal contractility. We calculated the energy expended to void bladder for the first time.

Impact: A method using MRI-based computational fluid dynamics was developed to simulate bladder voiding. Results show successful quantification of urine flow dynamics. This method shows potential to overcome limitations of current invasive catheter-based urodynamic studies.



Simultaneous R₂* Relaxometry and Dixon Imaging of Liver and Kidney at 3T Using Bilateral Orthogonality Generative Acquisitions Method

Çelik Boğa¹ and Anke Henning¹

¹UT Southwestern Medical Center, Dallas, TX, United States

Keywords: Whole Body, Body, liver, kidney, parallel transmission, Dixon imaging

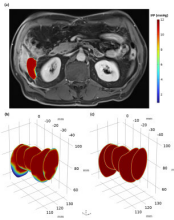
Motivation: Improving the quality of body R₂* (T₂*) images by removing transmit field inhomogeneity while utilizing Dixon imaging in body at 3T.

Goal(s): Implementation of Bilateral Orthogonality Generative Acquisitions method for simultaneously obtaining homogeneous R₂* (T₂*) and Dixon imaging from kidney and liver at 3T.

Approach: Bilateral Orthogonality Generative Acquisitions method was improved to include phase effect that enables the use of Dixon Imaging. Multi-echo acquisitions are utilized for R₂* estimation.

Results: Implementation of Bilateral Orthogonality Generative Acquisitions method enables the simultaneous R₂* (T₂*) and Dixon imaging and eliminates the central brightening effect.

Impact: Simultaneous homogeneous R₂* (T₂*) and Dixon imaging is implemented within same scan time required for Dixon imaging while removing the central brightening effect in body imaging at 3T.



Creating Digital Twins of Solid Tumors: Insights from Dynamic Contrast-Enhanced MRI

Hooman Salavati^{1,2}, Wim Ceelen¹, Charlotte Debbaut², and Pim Pullens³

¹Department of Human Structure and Repair, Ghent University, Ghent, Belgium, ²IBiTech – BioMMeda, Ghent University, Ghent, Belgium, ³Department of Radiology, Ghent University Hospital, Ghent, Belgium

Keywords: In Silico, Quantitative Imaging, Digital twin


Motivation: Prediction of cancer therapy outcomes is a paramount objective in oncology, closely tied to the integration of novel biomarkers into clinical practice.

Goal(s): The goal of creating digital twins of solid tumors is to equip oncologists with a comprehensive replica of the tumor, allowing them to make well-informed decisions.

Approach: In the development of digital twins for solid tumors, we introduce a multidisciplinary approach that essentially combines quantitative MRI and computational modeling.

Results: The image-based model yields a comprehensive representation of tumor perfusion, providing a map of elevated interstitial fluid pressure, which holds significant potential as a biomarker in oncology.

Impact: Cancer therapy's success is not guaranteed, with potential serious side effects. Our aim is to offer a robust digital tumor replica for evaluating numerous treatment options, identifying the optimal plan while minimizing adverse effects.



Elastic modulus of acetabular labrum correlates with UTE apparent spin-spin (T_2^*) and spin-lattice (T_1) magnetic resonance relaxation times

Dina Moazamian¹, Takehito Hananouchi^{2,3}, Hamidreza Shaterian Mohammadi¹, Arya Suprana¹, Alireza Tayarani⁴, Erik W Dorthe³, Darryl W D'Lima³, Yajun Ma⁵, and Saeed Jerban⁵

¹Radiology, University of California San Diego, San Diego, CA, United States, ²Academia-Government-Industry Collaboration, Office of Research and Academia-Government-Community Collaboration Hiroshima University, Hiroshima, Japan, ³Orthopedic, Shiley Center for Orthopedic Research and Education at Scripps Clinic, San Diego, CA, United States, ⁴Pathology, University of California San Diego, San Diego, CA, United States, ⁵Radiology, Radiology, University of California San Diego, San Diego, CA, United States, San Diego, CA, United States

Keywords: High-Field MRI, Cartilage, Acetabular Labrum, UTE

Motivation: The acetabulum labrum plays a critical role in the hip function. Medical imaging techniques for detecting labral degeneration may help improve our knowledge of its role in hip osteoarthritis (OA).

Goal(s): This study aimed to explore the correlation between the mechanical properties of the acetabulum labrum and MRI properties.

Approach: The correlations of UTE- T_2^* and - T_1 sequences with the tensile elastic modulus of human acetabular labrum specimens have been investigated.

Results: There was a significant correlation between quantitative UTE- T_2^* , and UTE- T_1 techniques and the mechanical properties of the labrum.

Impact: UTE- T_2^* and - T_1 sequences showed the potential to evaluate acetabulum labrum mechanical assessment, which is needed to improve labrum degeneration detection and monitoring, a primary unmet need in areas where hip osteoarthritis is common and conventional MRI is being implemented.

Index	Value	Unit	Index	Value	Unit
1	71.9	ms	1	13.6	ms
2	183	ms	2	17.7	ms
3	0.118		3	0.177	
4	1479	ms	4	1919	ms
5	0.053		5	0.109	

Multi-parametric Quantitative Magnetic Resonance Imaging Phantom

Hannah E Alderson^{1,2}, Scott D Swanson³, William Reichert^{1,2}, Daniel F Gochberg^{2,4}, and Mark D Does^{1,2,4}

¹Biomedical Engineering, Vanderbilt University, Nashville, TN, United States, ²Vanderbilt University Institute of Imaging Science, Nashville, TN, United States, ³Radiology, University of Michigan, Ann Arbor, MI, United States, ⁴Radiology and Radiological Sciences, Vanderbilt University Medical Center, Nashville, TN, United States

Keywords: Phantoms, Phantoms, multiparametric


Motivation: Currently there is no qMRI phantom that simultaneously reproduces the many contrasts that are present in white matter.

Goal(s): The goal of this work is to characterize a single multiparametric qMRI phantom that exhibits diffusion, magnetization transfer and MET_2 properties.

Approach: Aqueous MTF and PVP were combined in varying concentrations and evaluated with both NMR and MRI.

Results: A homogenous, multiparametric qMRI phantom was created with an array of tissue relevant parameters: T_{2L} ranging from 71.9-183 ms, T_{2s} ranging from 13.6-17.7 ms, f_s ranging from 0.118-0.177, T_{1free} ranging from 1479-1919 ms and f_m ranging from 0.053-0.109.

Impact: A multiparametric phantom allows for improved quality assurance analysis, as well as sequence development by allowing for multiple contrasts to be evaluated simultaneously. Ultimately providing a sample that is controlled, yet more akin to what occurs in biological samples.



Does the stability assessment of an MRI scanner depend on the phantom used?

Negar Amirafshari¹, Anestis Passalis², Frank Bolton³, Tom Hampshire³, Antonio Ricciardi², Aaron Oliver-Taylor³, Xavier Golay^{1,3}, and Marios C Yiannakas²

¹Brain Repair and Rehabilitation, UCL Queen Square Institute of Neurology, London, United Kingdom, ²NMR Research Unit, UCL Queen Square Institute of Neurology, London, United Kingdom, ³Gold Standard Phantoms, Sheffield, United Kingdom

Keywords: Phantoms, Phantoms, Reproducibility, Test-Retest

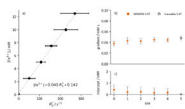
Motivation: The demonstration of the independence of fBIRN QA metrics on the phantom used would enable an easy cross-scanner comparison of scanner stability, thus improving such QA for clinical use (e.g., presurgical mapping).

Goal(s): The goal of this study was to assess the variance measured using such metrics across phantoms.

Approach: Nine identical phantoms were scanned on a single 3T scanner. Relaxometry and fBIRN scanning was performed on all phantoms and compared to those measured on a single phantom scanned 15 times.

Results: No significant difference was found between phantoms on either their relaxivities, or their QA fBIRN parameters.

Impact: The independence of fBIRN QA metrics on the phantom used found in this work enables the use of generalised QA across MRI scanners to assess their capacity at providing high quality fMRI for presurgical mapping, thereby ensuring optimal patient outcomes.



Enabling reproducible measurements of Fat Fraction and Iron content using an SI traceable reference phantom

Matt Cashmore¹, Cailean Clarkson², Ben P Tatman¹, Katie Obee¹, Jack Clarke¹, Nadia Smith¹, Frederic Brochu¹, Elizabeth Cooke¹, Asha Ford-Scille¹, Jessica Goldring¹, Robert Hanson¹, Asante Ntata¹, Susan Rhodes¹, Simone Busoni³, Aaron McCann⁴, Cormac McGrath⁴, Riccardo Ferrero⁵, Alessandra Manzin⁵, Adriano Troia⁵, Sarah Hill², Sumiksha Rai⁶, Stanislav Strepokytov², Christian Ward-Deitrich⁶, Alen Bosnjakovic⁷, Paul Tofts⁸, Tugba Dispinar⁹, Ilker Un¹⁰, Amy McDowell¹¹, Stephen Wastling¹¹, John Thornton¹¹, Nick Zafeiropoulos¹¹, Sian Curtis¹², Richard Scott¹², Holly Elbert¹², Jonathon Delve¹², Cameron Ingham¹², Amar Deumić¹³, Lejla Gurbeta Pokvić¹³, Merima Smajlhodžić-Deljo¹³, and Matt Hall¹

¹National Physical Laboratory, Teddington, United Kingdom, ²National Measurement Laboratory, LGC, Teddington, United Kingdom, ³AOU Careggi, Firenze, Italy, ⁴Belfast Health and Social Care Trust, Belfast, United Kingdom, ⁵Istituto Nazionale di Ricerca Metrologica, Torino, Italy, ⁶National Measurement Laboratory, Teddington, United Kingdom, ⁷Institute of Metrology of Bosnia and Herzegovina, Sarajevo, Bosnia and Herzegovina, ⁸Brighton and Sussex Medical School, Brighton, United Kingdom, ⁹TÜBİTAK, Ankara, Turkey, ¹⁰TÜBİTAK, Ankara, United Kingdom, ¹¹University College London, London, United Kingdom, ¹²University Hospitals Bristol and Weston NHS Foundation Trust, Bristol, United Kingdom, ¹³VERLAB, Sarajevo, Bosnia and Herzegovina

Keywords: Phantoms, Phantoms, Metrology, Traceability


Motivation: Quantitative MRI is a powerful tool for measuring a variety of biological parameters, with two common biomarkers of interest being fat fraction and Iron content.

Goal(s): We present here a test object for these parameters which is supported by fundamental metrology and traceable to the SI system.

Approach: Initial scan data taken at 1.5T is compared with traceable measurements of phantom properties

Results: We see significant variation seen in clinical results of the same phantom even with standardised protocols, outside the range of phantom validation.

Impact: We demonstrate a new gold standard and verified phantom for fat and iron measurement, traceable to primary standards. We present results using standardised MRI protocols which is vital for understanding and improving standards and best practice guidelines in the future.



A Generalized Real-time Frequency Adjustment Approach for MRSI

Marcus J. Couch¹, Lumeng Cui¹, and Sinyeob Ahn²

¹Siemens Healthcare Limited, Oakville, ON, Canada, ²Siemens Medical Solutions, Malvern, PA, United States

Keywords: System Imperfections, Spectroscopy


Motivation: Spectroscopy is sensitive to frequency drift. After running sequences that have a high gradient duty-cycle, frequency continues to drift due to gradient cooling.

Goal(s): To propose a generalized prospective real-time frequency correction that can be applied to imaging and spectroscopic sequences, where TR-variant and -invariant events are separable in time.

Approach: Real-time frequency adjustment was implemented for CSI, using a navigator placed where the spin phase is consistent across TR cycles prior to the CSI readout.

Results: Phantom measurements with the generalized navigator provide accurate estimates of the frequency drift, thereby minimizing spectral distortion and providing an improved baseline in the final spectra.

Impact: Prospective real-time frequency adjustment using a generalized navigator approach, where the spin phase is consistent across TR cycles, can be applied to spectroscopic imaging to correct for frequency drift caused by gradient heating and cooling.



Measuring CSF net velocity using DENSE at 7T with improved correction for involuntary motion and eddy currents.

Elisabeth van der Voort¹, Merlijn van der Plas¹, and Jacobus Zwanenburg¹

¹Center for Image Sciences, University Medical Center Utrecht, Utrecht, Netherlands

Keywords: Neurofluids, Neurofluids, CSF, Velocity & Flow, Clearance, Brain, Neuro

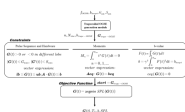Motivation: Clearance is important for healthy brain functioning. The ability to measure CSF net velocity would be valuable to gain insight into the underlying mechanisms and pathways of clearance.

Goal(s): To measure CSF net velocities in FH and RL direction whilst accounting for periodic motions, involuntary head motion and eddy currents.

Approach: A multi-slice single shot DENSE acquisition is used to measure CSF displacements over time.

Results: The measured net velocity does not fit the classical view on CSF excretion and absorption locations. Further validation is needed using a moving flow phantom.

Impact: The measured net velocities are about 10 percent of what would be expected. If confirmed in a larger cohort, the results challenge the classical view of main CSF excretion at the choroid plexus and absorption at the sagittal sinus.



Acoustic Noise Optimization of Trapezoid Oscillating Diffusion Encoding Gradient

Xingzhou Chen¹, Liyi Kang^{1,2}, Qinfeng Zhu¹, Yi-Cheng Hsu³, Xu Yan³, and Dan Wu¹

¹Department of Biomedical Engineering, College of Biomedical Engineering & Instrument Science, Zhejiang University, Hangzhou, China, ²Center for Intelligent Biomedical Instrumentation, Zhejiang University Binjiang Research Institute, Hangzhou, China, ³MR Collaboration, Siemens Healthcare China, Shanghai, China

Keywords: Gradients, Safety, Gradients Optimization, Acoustic Noise, OGSE

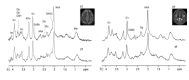
Motivation: Oscillating gradient spin-echo (OGSE) diffusion MRI sequence involves diffusion preparation and EPI readout, both having rapidly switching trapezoid gradient. Consequently, OGSE sequence generates strong acoustic noise that may introduce comfortless patient experience.

Goal(s): Our study aims to develop an optimization framework to suppress the acoustic noise by softening the trapezoid gradient.

Approach: We measured the acoustic noise frequency response function of scanner. Based on linear model of MRI acoustic noise generation, we designed a convex optimization framework to reduce the predicted A-weighting sound pressure level(SPL)

Results: Optimized gradient achieved 14.09dBA SPL reduction according to our FRF based prediction.

Impact: We developed an effective optimization method to reduce the acoustic noise of oscillating trapezoid gradient waveform, and potentially facilitate the clinical applications of OGSE. This optimization framework also has potential to reduce acoustic noise of EPI readout waveform



Initial experience of proton short echo MR spectroscopy of human brain at 5T

Hongxia Lei^{1,2}, Linfei Wen¹, Bin Deng³, Aiguo Xue¹, and Chaohong Wang¹

¹United-Imaging Healthcare, Shanghai, China, ²Wuhan United-Imaging Life Science Instrument Ltd Co., Wuhan, China,

³United-Imaging Healthcare, Shenzhen, China

Keywords: High-Field MRI, Metabolism, spectroscopy

Motivation: Proton short echo ($TE \leq 10\text{ms}$) MR spectroscopy of human brain at high magnetic fields ($\geq 3\text{T}$) provides abundant metabolic information beyond MR images, but remains challenging for routine clinical usages beyond 3T.

Goal(s): To evaluate feasibility and assess quality of proton ultrashort echo (i.e. 10ms) MR spectroscopy of human brain on a clinical, whole-body 5T MRI system.

Approach: Stimulated echo acquisition mode (STEAM) spectra with $TE=10\text{ms}$ were obtained in human brain at 3T and 5T.

Results: The feasibility of short echo MR spectroscopy of human brain at 5T was first demonstrated. The spectral quality is substantially improved when compared to 3T.

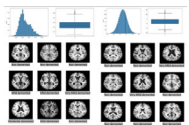
Impact: The quality of short echo MR spectra at 5T could be reached without exceeding the SAR and thus may offer additional metabolite information for large amount of clinical diagnostic applications.

AI/ML for Image Analysis, Diagnosis & Predictive Insights

Exhibition Hall (Hall 403)

Monday 13:45 - 14:45

4843



Early Alzheimer's Detection and Classification using VGG Convolutional Neural Network and Systematic Data Augmentation using MR Images

Elena Budyak¹, Jihoon Kwon¹, and Surendra Maharjan²

¹Carmel High School, Carmel, IN, United States, ²Radiology and Imaging Sciences, Indiana University School of Medicine, Indianapolis, IN, United States

Keywords: Diagnosis/Prediction, Machine Learning/Artificial Intelligence


Motivation: The use of different imaging tools at various hospitals results in varying contrast images. This fragmentation in healthcare prompted me to develop a personalized network that can be trained using hospital imaging database.

Goal(s): The main goal of this project is to predict early stages of Alzheimer's Disease (AD) using Magnetic Resonance (MR) images.

Approach: We applied convolutional neural network (CNN) to the T1 weighted images of AD, publicly available at <https://www.kaggle.com/datasets/tourist55/alzheimers-dataset-4-class-of-images>. The images were classified into four classes. F1 score and Area Under Curve (AUC) were calculated for the model after training.

Results: We demonstrated F1 score of 99.60% and AUC 0.994.

Impact: This model could be used to predict AD to other datasets that might help early detection of AD and subsequently improve treatment strategies. With various mice brain scan training, this network can also be used to aid AD researchers.



Predictive Value of Biochemical Recurrence in Advanced Prostate Cancer: Development of Deep Learning-based Radiomics Model

Huihui Wang¹, Kexin Wang², Yaofeng Zhang³, and xiaoying Wang¹

¹Peking University First Hospital, Beijing, China, ²School of Basic Medical Sciences, Capital Medical University, Beijing, China, ³Beijing Smart Tree Medical Technology Co. Ltd, Beijing, China

Keywords: Diagnosis/Prediction, Radiomics

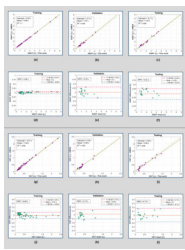
Motivation: Deep learning for predicting biochemical recurrence (BCR) is feasible but needs further evaluation in advanced prostate cancer (PCa).

Goal(s): We aimed to develop radiomics models with automatic segmentation derived from pretreatment ADC maps that may be predictive of BCR in advanced PCa.

Approach: In this study, PCa areas were segmented on ADC images by using a pre-trained artificial intelligence (AI) model. Three models were constructed to evaluate BCR prediction level.

Results: The deep-radiomics model was superior than the clinical model and the conventional radiomics model in the aspect of prediction accuracy, clinical impact and risk assessment.

Impact: With accurate BCR prediction by deep-radiomics model, more appropriate treatment plans may be formulated and intervention treatment can be carried out as soon as possible, resulting in better prognosis for patients with PCa.



Automatic Quantification of Abdominal Subcutaneous and Visceral Adipose Tissue based on Dixon Sequences using Convolutional Neural Networks

Benito de Celis Alonso¹, José Gerardo Suárez García², Po Wah-So³, Javier Miguel Hernández López¹, Silvia Sandra Hidalgo Tobón^{4,5}, and Pilar Dies Suárez⁶

¹Faculty of Physical and Mathematical Sciences, Benemérita Universidad Autónoma de Puebla, BUAP, Puebla, Mexico, ²Benemérita Universidad Autónoma de Puebla, BUAP, Puebla, Mexico, ³Department of Neuroimaging, Institute of Psychiatry, King's College London, London, United Kingdom, ⁴Facultad de Ciencias, UAM Campus Iztapalapa, CDMX, Mexico, ⁵Imaging Department., Hospital Infantil de México, Federico Gómez, CDMX, Mexico, ⁶Imaging Department, Hospital Infantil de México Federico Gómez, CDMX, Mexico

Keywords: AI/ML Software, Fat

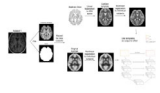
Motivation: Currently there is a widely validated commercial semi-automatic method called AMRA® Researcher, which quantifies ASAT and VAT. However, it is not accessible to everyone due to the necessary economic means.

Goal(s): To develop an automatic, simple and free methodology to quantify ASAT and VAT, with at least the same precision as AMRA® Researcher.

Approach: Preprocessing and simple CNNs applied on in-phase Dixon MRI sequences were proposed for quantify VAT and ASAT.

Results: There were no significant differences between the quantifications from AMRA Researcher and our methodology. Both obtained a high correlation and our methodology reached the precision of AMRA® Researcher.

Impact: Our automatic, simple and free ASAT and VAT quantification methodology, studying MRI through preprocessing and CNNs, achieved the precision of the commercial semi-automatic AMRA Researcher method. After future independent validation, this could become an accessible tool to assist specialists.



A Convolutional Neural Network Approach to Personalized Neuropil Density Prediction

Brian Chang¹, Adil Akif¹, John Onofrey¹, and Fahmeed Hyder¹

¹Biomedical Engineering, Yale University, New Haven, CT, United States

Keywords: Diagnosis/Prediction, Diffusion/other diffusion imaging techniques, Brain, gray matter, white matter

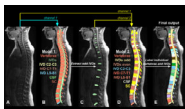
Motivation: Bottom-up energy budgets provide a way to quantify electrical activity in the brain using metabolic imaging. However, existing models are not patient-specific, instead using generalized neural cell counts, preventing direct measures of cognitive activity in the brain.

Goal(s): Our goal was to use a convolutional neural network (CNN) to demonstrate the possibility of predicting individualized neural cell counts.

Approach: Multi-modal MRI from nine patients was used to model neural and synaptic density predictions, which were compared to silver standard counts using correlation coefficient in a cross-validation study.

Results: The model demonstrates an ability to predict patient-specific energy budgets.

Impact: The success of machine learning methods in predicting neural cell and synaptic density paves the way for the use of CNNs to generate patient-specific energy budgets, improving understanding of brain energetics at a microscopic level in health and disease.



Fully Automatic Vertebrae and Spinal Cord Segmentation Using a Hybrid Approach Combining nnU-Net and Iterative Algorithm

Yehuda Warszawer^{1,2,3}, Nathan Molinier^{4,5}, Jan Valosek^{4,5}, Emanuel Shirbint¹, Pierre-Louis Benveniste^{4,5}, Anat Achiron^{1,6}, Arman Eshaghi^{7,8,9}, and Julien Cohen-Adad^{4,5,10,11}

¹Multiple Sclerosis Center, Sheba Medical Center, Ramat-Gan, Israel, ²Arrow Program for Medical Research Education, Sheba Medical Center, Ramat-Gan, Israel, ³Adelson School of Medicine, Ariel University, Ariel, Israel, ⁴NeuroPoly Lab, Institute of Biomedical Engineering, Polytechnique Montreal, Montreal, QC, Canada, ⁵Mila - Quebec AI Institute, Montreal, QC, Canada, ⁶Faculty of Medicine, Tel-Aviv University, Tel-Aviv, Israel, ⁷Queen Square Multiple Sclerosis Centre, Department of Neuroinflammation, University College London, London, United Kingdom, ⁸Queen Square Institute of Neurology, Faculty of Brain Sciences, University College London, London, United Kingdom, ⁹Centre for Medical Image Computing (CMIC), Department of Computer Science, Faculty of Engineering Sciences, University College London, London, United Kingdom, ¹⁰Functional Neuroimaging Unit, CRIUGM, Université de Montréal, Montreal, QC, Canada, ¹¹Centre de recherche du CHU Sainte-Justine, Université de Montréal, Montreal, QC, Canada

Keywords: AI/ML Software, Segmentation


Motivation: 3D visualisation of the spinal cord and vertebrae anatomy is critical for treatment planning and assessment of cord atrophy in neurodegenerative and traumatic diseases.

Goal(s): Develop a fully automatic segmentation of the whole spinal cord, vertebrae and discs.

Approach: The hybrid method combines a nnU-Net with an iterative processing algorithm with Spinal Cord Toolbox to conveniently generate ground truth labels. We used 3D T1w and T2w scans from three different databases.

Results: A validation Dice score of 0.928 was obtained (averaged across contrasts, classes and datasets), suggesting promising segmentation accuracy and capabilities for generalisation given the use of multi-site/multi-vendor datasets.

Impact: The fully automatic segmentation of the spine and spinal cord will pinpoint pathologies at specific vertebrae level, offering visualization for surgery preparation. This could also refine segmentation of substructures like multiple sclerosis lesions and tumors, inspiring solutions for related issues.



Semi-supervised learning for non-invasive radiopathomic mapping of treatment naïve glioma with multi-parametric MRI

Jacob Ellison^{1,2,3}, Nate Tran^{1,2,3}, Paramjot Singh¹, Oluwaseun Adegbite^{1,2,3}, Joanna Phillips^{4,5}, Annette Molinaro⁴, Valentina Padoia^{1,2,3}, Tracy Luks¹, Anny Shai^{4,5}, Devika Nair¹, Javier Villanueva-Meyer^{1,2}, Mitchel Berger⁴, Shawn Hervey-Jumper⁴, Manish Aghi⁴, Susan Chang⁴, and Janine Lupo^{1,2,3}

¹Radiology and Biomedical Imaging, UCSF, San Francisco, CA, United States, ²Center for Intelligent Imaging, UCSF, San Francisco, CA, United States, ³Bioengineering, UCSF/UC Berkeley, San Francisco, CA, United States, ⁴Neurological Surgery, UCSF, San Francisco, CA, United States, ⁵Pathology, UCSF, San Francisco, CA, United States

Keywords: Diagnosis/Prediction, Machine Learning/Artificial Intelligence

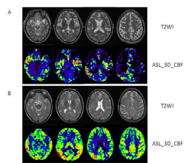
Motivation: Radiopathomic mapping of glioma could improve standard of care by helping guide surgical resection and subsequent treatment. Most current methods for predicting tumor pathology using MRI neglect intra-tumoral heterogeneity.

Goal(s): We aim to use multi-parametric MRI and deep learning to spatially map pathology for treatment naïve glioma.

Approach: We utilized histopathologically analyzed tissue samples taken during surgical resection with known coordinates on pre-surgical multi-parametric MRI and semi-supervised ensemble networks.

Results: Our model classifies Ki-67 with an AUROC of 0.84 and 0.73 for combined Ki-67 and percent cancerous cells. Including physiologic MRI and pretraining on patches of unknown pathology improved performance.

Impact: We performed radiopathomic mapping in patients with newly-diagnosed glioma using presurgical physiological + anatomical MRI and semi-supervised ensemble networks and achieved AUROCs of 0.84 and 0.73 for Ki-67 and combined Ki-67 and % cancerous cells, respectively.



Pre-operative prediction of cerebral hemodynamics for cognitive dysfunction in adults with Moyamoya Disease based on 3D-pCASL and radiomics

Tingxi Wu¹, Xiangyue Zha¹, Kan Deng², Yaohong Deng³, Qin Liu¹, and Yikai Xu¹

¹Department of Medical Imaging Center, Nanfang Hospital, Southern Medical University, Guangzhou, China, ²Philips Healthcare, Guangzhou, China, ³Department of Research & Development, Yizhun Medical AI Co. Ltd, Beijing, China

Keywords: Diagnosis/Prediction, Arterial spin labelling, Moyamoya disease

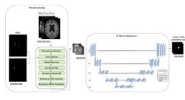
Motivation: Cognitive function in adult patients with moyamoya disease (MMD) is often impaired because of low cerebral perfusion.

Goal(s): To identify brain regions where low CBF is associated with cognitive dysfunction and assess the predictive performance of radiomics models for cognitive dysfunction in adults MMD.

Approach: 3D-pCASL and logistic regression analysis was employed to quantify CBF and explore independent predictors for preoperative cognitive dysfunction. And five different classifiers were used to establish radiomics models.

Results: Cerebral perfusion in the left LOFL, left IPL, left SMA, and left ACG showed significant associations with cognitive impairment. The final combined model had the best predictive performance.

Impact: Hypoperfusion on 3D-pCASL plays a crucial role in the detection of early cognitive impairment in adults with MMD, and the combined model that combined with CBF and radiomics features of specific brain regions showed better performance in predicting cognitive dysfunction.



Gadolinium contrast-enhanced lesion segmentation in multiple sclerosis: a deep-learning approach.

Martina Greselin^{1,2,3}, Po-Jui Lu^{1,2,3}, Lester Melie-Garcia^{1,2,3}, Mario Ocampo-Pineda^{1,2,3}, Riccardo Galbusera^{1,2,3}, Alessandro Cagol^{1,2,3,4}, Matthias Weigel^{1,2,3,5}, Nina de Oliveira Siebenborn^{1,2,3,6}, Esther Ruberte^{1,2,3,6}, Pascal Benkert⁷, Stefanie Müller⁸, Lutz Achtnichts⁹, Jochen Vehoff⁸, Giulio Disanto¹⁰, Oliver Findling⁹, Andrew Chan¹¹, Anke Salmen^{11,12}, Caroline Pot¹³, Claire Bridel¹⁴, Chiara Zecca^{10,15}, Tobias Derfuss³, Johanna M. Lieb¹⁶, Luca Remonda¹⁷, Franca Wagner¹⁸, Maria I. Vargas¹⁹, Renaud Du Pasquier¹³, Patrice H. Lalive¹⁴, Emanuele Pravatà²⁰, Johannes Weber²¹, Claudio Gobbi^{10,15}, David Leppert³, Ludwig Kappos^{1,2,3}, Jens Kuhle^{2,3}, and Cristina Granziera^{1,2,3}

¹Translational Imaging in Neurology (ThINk) Basel, Department of Biomedical Engineering, Faculty of Medicine, University Hospital Basel and University of Basel, Basel, Switzerland, ²Department of Neurology, University Hospital Basel, Basel, Switzerland, ³Research Center for Clinical Neuroimmunology and Neuroscience Basel (RC2NB), University Hospital Basel and University of Basel, Basel, Switzerland, ⁴Department of Health Sciences, University of Genova, Genova, Italy, ⁵Division of Radiological Physics, Department of Radiology, University Hospital Basel, Basel, Switzerland, ⁶Medical Image Analysis Center (MIAC), Basel, Switzerland, ⁷Clinical Trial Unit, Department of Clinical Research, University Hospital Basel, University of Basel, Basel, Switzerland, ⁸Department of Neurology, Cantonal Hospital St. Gallen, St. Gallen, Switzerland, ⁹Department of Neurology, Cantonal Hospital Aarau, Aarau, Switzerland, ¹⁰Neurology Department, Neurocenter of Southern Switzerland, Lugano, Switzerland, ¹¹Department of Neurology, Inselspital, Bern University Hospital and University of Bern, Bern, Switzerland, ¹²Department of Neurology, St. Josef-Hospital, Ruhr-University Bochum, Bochum, Germany, ¹³Service of Neurology, Department of Clinical Neurosciences, Lausanne University Hospital (CHUV) and University of Lausanne, Lausanne, Switzerland, ¹⁴Department of Clinical Neurosciences, Division of Neurology, Geneva University Hospitals and Faculty of Medicine, Geneva, Switzerland, ¹⁵Faculty of biomedical Sciences, Università della Svizzera Italiana, Lugano, Switzerland, ¹⁶Division of Diagnostic and Interventional Neuroradiology, Clinic for Radiology and Nuclear Medicine, University Hospital Basel, Basel, Switzerland, ¹⁷Department of Radiology, Cantonal Hospital Aarau, Aarau, Switzerland, ¹⁸Department of Diagnostic and Interventional Neuroradiology, Inselspital, Bern University Hospital and University of Bern, Bern, Switzerland, ¹⁹Department of Radiology, Geneva University Hospital and Faculty of Medicine, Geneva, Switzerland, ²⁰Department of Neuroradiology, Neurocenter of Southern Switzerland, Lugano, Switzerland, ²¹Department of Radiology, Cantonal Hospital St. Gallen, St. Gallen, Switzerland

Keywords: Diagnosis/Prediction, Segmentation

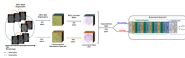Motivation: Detection of contrast-enhanced lesions (CELs) is fundamental for the diagnosis and monitoring of Multiple Sclerosis (MS) patients. This task is time-consuming and variable in the clinical setting. However, only a few studies reported automatic approaches.

Goal(s): To develop a deep-learning tool to automatically detect and segment CELs in clinical MRI scans from MS patients.

Approach: We implemented a UNet-based network with an adapted sampling strategy to overcome the scarcity of CELs. We considered the data imbalance to weight the training loss function.

Results: The model performance was evaluated for different lesion-volume ranges and achieved high performance even in low-volume lesions.

Impact: We developed a deep-learning method fulfilling clinical needs in detecting and segmenting lesions characterized by low volume, low numbers per patient and heterogeneous shapes.



Can We Distinguish Intra- and Inter-Variability with Log Jacobian Maps Derived from Brain Morphological Deformations Using Pediatric MRI Scans?

Andjela Dimitrijevic^{1,2}, Fanny Dégeilh³, and Benjamin De Leener^{1,4,5}

¹NeuroPoly Lab, Institute of Biomedical Engineering, Polytechnique Montréal, Montréal, QC, Canada, ²Research Center, Ste-Justine Hospital University Centre, Montréal, QC, Canada, ³IRISA UMR 6074, EMPENN ERL U-1228, Université de Rennes, CNRS, Inria, Inserm, Rennes, France, ⁴Research Center, Ste-Justine Hospital University Centre, Montreal, QC, Canada, ⁵Computer Engineering and Software Engineering, Polytechnique Montréal, Montreal, QC, Canada

Keywords: Other AI/ML, Data Analysis, Modelling

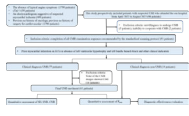
Motivation: Importance of analyzing deformation fields derived from both intra- and inter-individual pairs of T1-weighted images which could offer insights into typical and atypical neurodevelopment.

Goal(s): We aimed to fine-tune a 3D CNN to classify intra and inter-individual variability based on log Jacobian maps from deformation fields of pediatric longitudinal MRI.

Approach: 279 log Jacobian maps of both intra- and inter-individual pairs are extracted using ANTs. A 3D CNN is trained in two ways (overlap and no overlap) for binary classification using 10-fold cross-validation.

Results: As expected, the overlap scenario had higher accuracy and F1 score compared to no-overlap, nonetheless both achieving good results.

Impact: This project's focus on pediatric MRI scans aims to understand deformations in medical imaging, advancing diagnostic tools. By distinguishing intra and inter-individual variability using log Jacobian-derived deformation patterns, it subsequently aims to model typical neurodevelopment through trajectories for deviation prediction.



An appropriate threshold for LGE images using deep learning-based reconstruction in revelation clinically unrecognized myocardial infarction

Wei Yin Vivian Liu¹, Xuefang Lu², Yuchen Yan², and Yunfei Zha²

¹GE Healthcare, MR Research China, Beijing, China, ²Department of radiology, Renmin Hospital Wuhan University, Wuhan, China

Keywords: AI/ML Image Reconstruction, Cardiovascular

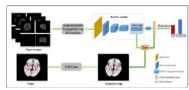
Motivation: To precisely screen out infarction in patients with unrecognized myocardial infarction (UMI) in hope of early intervention to reduce adverse cardiac events.

Goal(s): To evaluate deep learning reconstruction based late gadolinium enhancement (LGE_{DL}) in comparison with conventional reconstructed LGE (LGE_O) and also to explore an appropriate threshold method for LGE measurements.

Approach: LGE_{DL} and LGE_O of 77 patients diagnosed with UMI were evaluated for image quality and analyzed for MI areas using different standard deviation thresholds and a full-width-half-height (FWHM) method.

Results: The STRM $\geq 4SD$ and $\geq 3SD$ is respectively reckoned as the best reference threshold for LGE_{DL} and LGE_O.

Impact: The deep-learning based reconstruction LGE images had better image quality and reliable pathological evidences for detection of UMI. Significantly different Parea using threshold techniques for LGE_{DL} and LGE_O indicated the utility of STRM should be concerned.



MRI-based prediction of cerebral palsy risk in infants aged 6 months to 2 years: a deep learning approach

Zhen Jia^{1,2,3}, Tingting Huang^{2,3}, Man Li⁴, Yitong Bian^{2,3}, Xianjun Li^{2,3}, Feng Shi⁴, and Jian Yang^{1,2,3}

¹School of Future Technology, Xi'an Jiaotong University, Xi'an, China, ²Department of Radiology, The First Affiliated Hospital of Xi'an Jiaotong University, Xi'an, China, ³Shaanxi Engineering Research Center of Computational Imaging and Medical Intelligence, Xi'an, China, ⁴Department of Research and Development, Shanghai United Imaging Intelligence Co., Ltd., Shanghai, China

Keywords: Diagnosis/Prediction, Brain, Cerebral Palsy

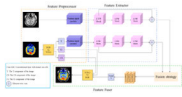
Motivation: Early prediction of cerebral palsy (CP) in infants plays a pivotal role in facilitating tailored rehabilitation treatment.

Goal(s): We hope to achieve early prediction of CP in infants aged 6 months to 2 years old based on MRI and deep learning technology.

Approach: We introduce a novel neural network model, known as the "Cerebral Palsy Brain Constraint Residual Network" (CPBC-Resnet), for the automatic prediction of CP risk based on MRI data.

Results: The CPBC-Resnet model exhibits an impressive receiver operating characteristic area under the curve (AUC) of 0.9521, achieving a sensitivity of 94.12% and a specificity of 100%.

Impact: This study streamlines cerebral palsy (CP) imaging diagnostics, reducing physician training costs, and expanding the reach of CP diagnostic technology. It promotes early CP diagnosis and intervention, particularly in areas with underdeveloped medical standards, contributing to overall child health improvement.



A multi-scale pyramid residual weight network for medical image fusion

Yiwei Liu¹, Shaoze Zhang², Xihai Zhao¹, and Zuo-Xiang He³

¹Center for Biomedical Imaging Research, Department of Biomedical Engineering, Tsinghua University, Beijing, China,

²Department of Biomedical Engineering, Tsinghua University, Beijing, China, ³Beijing Tsinghua Changgung Hospital, Beijing, China

Keywords: Diagnosis/Prediction, PET/MR, Artificial Intelligence, Brain

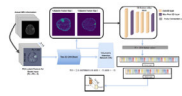
Motivation: At present, the multi-modal fusion image has the problems of weak functional information performance and much noise.

Goal(s): Based on the existing technology, this research increases the retention of functional information and improves the display quality of the fused image.

Approach: In this study, a multi-scale pyramid convolutional neural network model based on residual structure is constructed, which can extract deeper semantic information while retaining shallow context information.

Results: By constructing a new convolutional neural network, the loss of functional information in the fused image is reduced, the noise of the fused image is reduced, and the image quality is improved.

Impact: The multimodal image fusion technology proposed in this paper preserves the texture information of MRI and CT, and the functional information of PET/SPECT at the same time, which makes more dimensions available for clinical diagnosis in the future.



Classification of Grade II and III Astrocytomas for Multi-modal MRI using Deep Volumetric Attention Networks.

Hamail Ayaz¹, Oladosu Oyebeisi Oladimeji¹, David Tormey², Ian McLoughlin³, and Saritha Unnikrishnan¹

¹Computing and Electronics, Atlantic Technological University Sligo, Sligo, Ireland, ²Mechanical & Electronic Engineering,

Atlantic Technological University Sligo, Sligo, Ireland, ³Computer Science and Applied Physics, Atlantic Technological University Sligo, Galway, Ireland

Keywords: Diagnosis/Prediction, Brain, Volumetric Attention Network, Deep Learning, Astrocytomas, Glioma, Classification

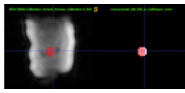
Motivation: Diagnosis and grading of astrocytomas tumour present considerable challenges. Manual grading is time-consuming and error prone. Preoperative MRIs are a useful, yet deep learning presents challenges due to computing limitations and complex architecture.

Goal(s): Study introduces novel multimodal MRI classification for grade II and III astrocytomas, aiming to improve accuracy, reduce complexity, and address interclass homogeneity via attention mechanism.

Approach: Single slice from eight MRI modalities forms a three-dimensional cube. Normalized, iPCA processed, and passed to deep model with volumetric attention network.

Results: The DVA using advanced and traditional MRI information outperforms existing models achieving an overall accuracy of 77% using five-fold cross-validation.

Impact: The proposed multimodal MRI classification approach enhances astrocytoma diagnosis and grading. The deep volumetric attention model improves accuracy, reduces model complexity, and holds potential for trustworthiness impacts in clinical practice.



A Two Step Workflow to Support Fully Autonomous MR Scanning in Prostate

Dawei Gui¹, Aanchal Mongia², Chitresh Bhushan³, Jeremy Heinlein¹, Kavitha Manickam¹, Muhan Shao³, Uday Patil², and Dattesh Shanbhag²

¹GE Healthcare, Waukesha, WI, United States, ²GE Healthcare, Bengaluru, India, ³GE Healthcare, Niskayuna, NY, United States

Keywords: Other AI/ML, Machine Learning/Artificial Intelligence

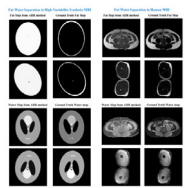
Motivation: A fully automatic workflow for scan plane prescription is desirable in clinical settings.

Goal(s): Our goal is to demonstrate a deep learning-based MRI scan workflow for fully automated MR scanning in the prostate.

Approach: This new scan workflow will identify anatomical landmarks and scan planes for prostate planning (coverage, FOV and orientation) from coil sensitivity and 3plane scout images.

Results: The deep learning-based anatomy recognition showed acceptable average location error below 5mm and plane orientation error below 10 degrees.

Impact: As no interaction from the operator is required to complete a full MR prostate scan, it paves the way for fully automated MR scans for the prostate anatomy.



High-variability synthetic fat-water MRI dataset for testing the robustness of Deep Learning-based reconstruction models

Ganeshkumar M¹, Devasenathipathy Kandasamy², Raju Sharma², and Amit Mehndiratta^{1,3}

¹Centre for Biomedical Engineering, Indian Institute of Technology - Delhi, New Delhi, India, ²Department of Radio Diagnosis, All India Institute of Medical Sciences, New Delhi, India, ³Department of Biomedical Engineering, All India Institute of Medical Sciences, New Delhi, India

Keywords: AI/ML Image Reconstruction, Quantitative Imaging, Fat-water separation, PDFF, Deep Learning, Fat Quantification, Physics Informed Deep Learning, Synthetic MRI

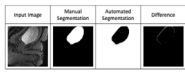
Motivation: Deep Learning (DL) models have recently been used for fat-water separation in Multi-Echo MRI (ME-MRI). However, DL models may not always be robust and under-perform when not trained with a large and diverse dataset.

Goal(s): This research proposes high-variability synthetic ME-MRI generated using the biophysical model of fat-water separation as a tool for testing the generalizability and robustness of DL-based fat-water separation models.

Approach: High-variability synthetic ME-MRI was used to evaluate the robustness of the recent state-of-the-art DL-based Ad-Hoc Reconstruction (AHR) method for fat-water separation.

Results: The AHR method lacked robustness and synthetic ME-MRIs can be effectively used to test DL models.

Impact: The fat-water maps obtained by processing the Multi Echo-MRI (ME-MRI) are of diagnostic and prognostic value in many diseases. This study investigates the role of synthetic ME-MRIs with high variability in testing the robustness of Deep Learning-based fat-water separation models.



Automated Bladder Segmentation of 3D Dynamic MRI For Urodynamic Analysis Using Deep Learning

Labib Shahid¹, Juan Pablo Gonzalez-Pereira¹, Jennifer Franck¹, and Alejandro Roldan-Alzate¹

¹University of Wisconsin-Madison, Madison, WI, United States

Keywords: Analysis/Processing, Machine Learning/Artificial Intelligence, Segmentation, Urodynamics

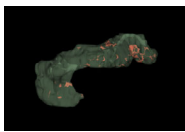
Motivation: Bladder dysfunction is assessed using catheterization which are invasive and provides insufficient biomechanical information. MRI urodynamics is tedious because segmentation of bladders over numerous time steps during voiding.

Goal(s): Implement automated segmentation using deep learning for accelerating the workflow of MRI-based urodynamic assessment.

Approach: Train a U-Net using 3D dynamic images and manually segmented masks. Use time and dice score to assess the performance of the network.

Results: Images of bladder voiding from five subjects were used to train the network and can segment one bladder in <3 minutes, compared to 20 minutes for manual segmentation. Dice score was 0.99 showing excellent performance.

Impact: Urodynamic assessment using MRI is a tedious process due to segmentation of the bladder from 3D dynamic image datasets. We automated segmentation using deep learning to accelerate the workflow. Our automated process reduced time sixfold and produces excellent segmentation.



Automated Pancreatic Segmentation and Quantitative Calculation Based on nnUnet

Li YingHao¹, Wang SuCheng¹, Zhu ZhongQi¹, Wang HongZhi¹, Li RenFeng², Wang LiHui², and Lu Qing²

¹East China Normal University, Shanghai, China, ²Department of Radiology, Shanghai East Hospital, Tongji University, Shanghai, China

Keywords: Diagnosis/Prediction, Segmentation

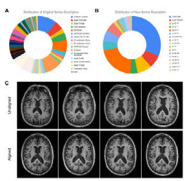
Motivation: Pancreatic diseases often exhibit spatial non-uniformity. Achieving automated segmentation of different pancreatic regions and conducting quantitative calculations of volume and fat content can effectively assist physicians in diagnosis and treatment.

Goal(s): Developing a segmentation network to achieve the automatic segmentation of the pancreas and to perform quantitative calculations of volume and fat content in different regions.

Approach: Sample acquisition was performed using Dixon sequences, and training was conducted using an improved nnUnet network. Additionally, an automated pancreatic segmentation and quantitative calculation method was developed.

Results: With a training dataset consisting of 800 cases, the network achieved a segmentation Dice coefficient of 0.92.

Impact: To save professional physician annotation time for early detection and diagnosis of pancreatic diseases, as well as for quantifying changes before and after pancreatic treatments, and to assist in clinical drug therapy.



Harmonizing Multicenter Datasets: Enhancing Consistency and Longitudinal Alignment using NLP and Realignment Algorithms

Thomas Campbell Arnold¹, Lanhong Yao¹, Ben Duffy¹, Greg Zaharchuk², Ryan Chamberlain¹, and Ludovic Sibille¹

¹Subtle Medical, Menlo Park, CA, United States, ²Radiology, Stanford University, Palo Alto, CA, United States

Keywords: AI/ML Software, Machine Learning/Artificial Intelligence, Natural Language Processing

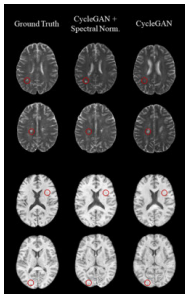
Motivation: Cohesive multicenter imaging datasets are critical for research, yet variability across institutions poses a significant challenge, especially when aggregating retrospective data for longitudinal disease monitoring.

Goal(s): Here, we present a method for harmonizing multicenter data that produces consistent series descriptions and enhances brain alignment between longitudinal time points.

Approach: We employed an NLP pipeline to standardize series descriptions and an automated algorithm to realign images. We applied these tools to ADNI imaging collected across multiple sites, scanners, and time points.

Results: The pipeline consolidated 101 unique series descriptions into 17 standardized descriptions. The alignment algorithm reduced orientation error and improved longitudinal image consistency.

Impact: Our methodology can impact clinical workflows by streamlining multicenter data analysis and enhancing longitudinal disease monitoring. These techniques improve image consistency between time points, which can facilitate disease monitoring and allow radiologists to assess changes in chronic disorders.



Overcoming the missing data challenge in clinical imaging using CycleGAN based on brain MRI in Multiple Sclerosis

Shayan Shahrokhi¹, Rehman Tariq², Olayinka Oladosu¹, and Yunyan Zhang³

¹Neuroscience, University of Calgary, CALGARY, AB, Canada, ²Biomedical Engineering, University of Calgary, Calgary, AB, Canada, ³Radiology, University of Calgary, Calgary, AB, Canada

Keywords: Analysis/Processing, Machine Learning/Artificial Intelligence

Motivation: Clinical MRI datasets are not always comprehensive or consistent, limiting their use for secondary analysis.

Goal(s): Investigating the suitability of a deep learning model named CycleGAN, with optional spectral normalization, for dealing with the missing sequence problems in clinical imaging as seen in multiple sclerosis (MS).

Approach: Using standard brain MRI of 104 MS people, we implemented 2 CycleGAN models, one with and one without spectral normalization to compare.

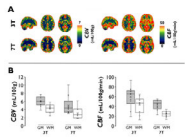
Results: CycleGAN performed competitively in image transformation between T1-weighted and T2-weighted images. Adding spectral normalization appears to improve performance, especially when the quality of training scans is inconsistent.

Impact: CycleGAN-based model has the potential to generate non-acquired images not always needed in standard clinical imaging, as seen in brain MRI in MS, where the resulting images can help promote various secondary analysis studies including machine learning.

Advances in Image Contrast

Exhibition Hall (Hall 403)

Monday 16:00 - 17:00



Non-Invasive Perfusion MR Imaging of the Human Brain via Breath-Holding

Jacob Benjamin Schulman¹, Sriranga Kashyap², Seong-Gi Kim³, and Kamil Uludag¹

¹Department of Medical Biophysics, University of Toronto, Toronto, ON, Canada, ²Krembil Brain Institute, University Health Network, Toronto, ON, Canada, ³Center for Neuroscience Imaging Research, Suwon, Korea, Republic of

Keywords: Perfusion, Perfusion

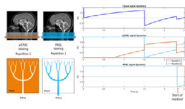
Motivation: DSC is the leading methodology for MR-based perfusion imaging. However, the technique's reliance on invasive gadolinium injections poses a major limitation.

Goal(s): Can breath-holding induce perfusion contrast that is exploitable using DSC MRI?

Approach: Ten healthy subjects underwent MRI at both 3T and 7T, while performing eight 16 s breath-holds. Breath-hold-induced signal changes were fed into a DSC MRI analysis pipeline, and perfusion was quantified.

Results: Calculated cerebral perfusion values were within the physiological range of literature values; the breath-hold task yielded significantly higher contrast-to-noise and GM-to-WM contrast with higher field strength and increased scan time, although this plateaued at roughly 6 min.

Impact: For the first time, we show that DSC-MRI using breath-holding allows for the quantification of perfusion parameters. This may have broad implications for neurovascular disease, either circumventing the need for invasive gadolinium injections or shedding additional light into pathology.



Hybrid phase-sensitive 4D MRA and perfusion imaging using dynamic arterial spin labeling with stack-of-stars golden-angle radial acquisition

Tianrui Zhao¹ and Lirong Yan¹

¹Department of Radiology, Northwestern University, Chicago, IL, United States

Keywords: Arterial Spin Labelling, Pulse Sequence Design

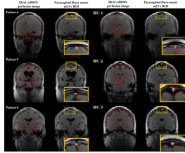
Motivation: Comprehensively characterizing cerebrovascular events including dynamic blood flow patterns and downstream perfusion is important in clinical diagnosis of cerebrovascular disorders.

Goal(s): To develop a time-efficient phase-sensitive ASL technique (PS-ASL) that provides high-quality time-resolved 4D-MRA and perfusion imaging within single scan.

Approach: PS-ASL sequence was designed by combining pCASL and PASL preparations with stack-of-stars golden-angle radial acquisition and a self-constraint low-rank subspace reconstruction. The label and control pulse modules alternated between pCASL and PASL preparations in each TR. Phase-sensitive subtraction between control and label yields 4D-MRA from PASL and perfusion from pCASL.

Results: Both dynamic 4D-MRA and perfusion maps were successfully obtained by PS-ASL.

Impact: The developed PS-ASL technique could be a potential powerful imaging tool in clinical applications, which provides detailed characterization of blood flow from both arterial and capillary beds in a single sequence.



A comparative study to assess the flow of meningeal lymphatic vessels in healthy volunteers and brain disorders using the IR-ALADDIN technique

Jun-Hee Kim¹, Roh-Eul Yoo^{2,3}, Seung-Hong Choi^{2,3}, and Sung-Hong Park¹

¹Korea Advanced Institute of Science and Technology, Daejeon, Korea, Republic of, ²Department of Radiology, Seoul National University College of Medicine, Seoul, Korea, Republic of, ³Seoul National University Hospital, Seoul, Korea, Republic of

Keywords: Neurofluids, Neurofluids

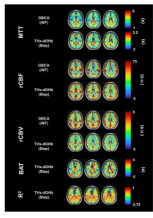
Motivation: The difference in mLVs outflow between healthy control (HC) and brain disorder patients may contribute to toxic protein aggregation and cognitive decline.

Goal(s): To demonstrate mLVs structure and flow information of brain disorder patients and compare quantitative flow metrics between HC and patient

Approach: We applied IR-ALADDIN to acquire mLVs images around superior sagittal sinus in 20 HCs and 9 patients with various brain disorders such as meningioma, hydrocephalus.

Results: The mLVs size was reduced in patients compared to HC with no significant difference in mLVs velocity, leading to overall mLVs flow reduction in patients.

Impact: The reduced mLVs flow in brain disorder patients was confirmed using a non-invasive technique. This suggests the possibility to study relationship between brain disorders and waste clearance through the mLVs flow in further studies.



Assessing cerebral perfusion: analysis of the BOLD response to a hypoxia-induced step change in deoxyhemoglobin

James Duffin^{1,2}, Ece Su Sayin¹, Olivia Sobczyk^{3,4}, Julien Su Poublanc⁵, David Mikulis⁵, and Joseph A. Fisher^{3,6}

¹Physiology, University of Toronto, Toronto, ON, Canada, ²Anaesthesiology and Pain Management, University of Toronto, Toronto, ON, Canada, ³Department of Anaesthesiology and Pain Management, University of Toronto, Toronto, ON, Canada, ⁴Joint Department of Medical Imaging and the Functional Neuroimaging Laboratory, University Health Network, Toronto, ON, Canada, ⁵Joint Department of Medical Imaging and the Functional Neuroimaging Lab, University Health Network, Toronto, ON, Canada, ⁶Toronto General Hospital Research Institute, University Health Network, Toronto, ON, Canada

Keywords: Contrast Agents, Perfusion, brain

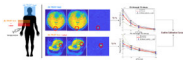
Motivation: Provide direct measurements of cerebral perfusion metrics, relative cerebral blood flow and volume, and mean transit time.

Goal(s): Generate a known step susceptibility contrast input rather than requiring back calculation of an arterial input function

Approach: We used a step reoxygenation of previously deoxygenated lung alveoli to induce a step increase in oxyhemoglobin in arterial blood and analyzed the T2*-weighted signal for each voxel. Perfusion metrics from step deoxyhemoglobin changes were compared to those from conventional analysis using a gadolinium contrast agent in healthy volunteers.

Results: The perfusion metrics from the step deoxyhemoglobin method were similar to those from Gadolinium injection.

Impact: Perfusion metrics can be measured directly from a non-invasive test using a step decrease in deoxyhemoglobin generated by instantaneous reoxygenation from a brief hypoxia. They correspond to those calculated indirectly from an intravenously injected Gadolinium contrast agent involving complex analysis.



Feasibility and Sensitivity of TRUST Measurements in the Upper Arm

Diogo Fernandes¹, Koen P.A. Baas², Matthan Caan³, Bart Biemond⁴, and Aart Nederveen¹

¹Radiology and Nuclear Medicine, Amsterdam UMC, Amsterdam, Netherlands, ²The Netherlands Cancer Institute, Amsterdam, Netherlands, ³Biomedical Engineering and Physics, Amsterdam UMC, Amsterdam, Netherlands, ⁴Clinical Haematology, CCA - Cancer Treatment and Quality of Life, Amsterdam University Medical Center, Location University of Amsterdam, Amsterdam, Netherlands

Keywords: Arterial Spin Labelling, Vessels

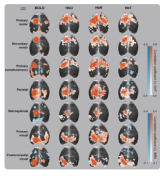
Motivation: T2-relaxation-under-spin-tagging(TRUST) is a non-invasive MRI technique to estimate blood oxygenation in the superior sagittal sinus from a T2 decay fit.

Goal(s): The calibration curve to convert T2 into oxygenation has been derived with ex-vivo experiments for healthy volunteers and patients with specific types of sickle cell disease.

Approach: Validation of these calibration curves is difficult because blood cannot be drawn from the superior sagittal sinus itself, hampering implementation of the technique in other patient groups.

Results: Here, TRUST was adapted and optimized for the arm so that its measurements of venous oxygenation can be directly compared with venipunctures from the cephalic vein.

Impact: The TRUST-sequence was optimized for non-invasive T2-measurement in the upper arm veins. A posteriori correlation with blood properties returns a venous oxygenation mapping. This may confirm the currently used calibration curve and facilitate obtaining accurate calibration curves for specific diseases.



Concurrent optoacoustic tomography and magnetic resonance imaging of resting-state functional connectivity in the mouse brain

Irmak Gezginer^{1,2}, Zhenyue Chen^{1,2}, Xosé Luís Deán-Ben^{1,2}, and Daniel Razansky^{1,2}

¹ETH Zurich, Zürich, Switzerland, ²University of Zurich, Zurich, Switzerland

Keywords: Hybrid Imaging, Molecular Imaging, Optoacoustic (Photoacoustic) Imaging

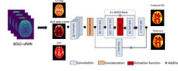
Motivation: Interpreting BOLD signals in fMRI studies is a challenging task due to their dependence on multiple factors.

Goal(s): Multiparametric readouts from a recently developed hybrid magnetic resonance optoacoustic tomography system can offer unprecedented capabilities for studying the rodent brain in resting-state conditions.

Approach: Simultaneously acquired multimodal functional data of mice were utilized to link hemoglobin resolved optoacoustic readouts to BOLD.

Results: Multiparametric brain-wide activity were detected under resting-state condition for the first time. Revealed functional connectivity maps and brain networks showed high spatial overlap among the hemodynamic components. BOLD and total hemoglobin functional connectivity were found tightly correlated, compared to oxygenated- and deoxygenated-hemoglobin.

Impact: Hybridization of optoacoustic tomography and MRI is a powerful multi-modal approach due to highly complementary contrasts and capabilities for functional neuroimaging. The more comprehensive functional readings provide unique capabilities for studying neurovascular and neurometabolic coupling mechanisms and related diseases.



Extracting Cerebral Perfusion Signal from BOLD fMRI via Deep Learning

Yiran Li¹ and Ze Wang¹

¹University of Maryland School of Medicine, Baltimore, MD, United States

Keywords: Arterial Spin Labelling, Arterial spin labelling

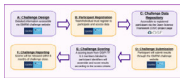Motivation: Cerebral blood flow (CBF) is a fundamental physiological measure indicating regional brain function and vascular conditions via arterial spin labeling (ASL) perfusion MRI, but ASL sequences is limited.

Goal(s): Blood-oxygen-level-dependent (BOLD) fMRI is known to be a function of CBF and other physiological sources. We try to extract CBF information from BOLD signal.

Approach: We proposed a convolutional neural network to extract CBF from BOLD fMRI signal.

Results: We confirmed the possibility of using supervised deep learning model to extract CBF from BOLD fMRI from independent sequences.

Impact: Deep learning enables the estimation of CBF signal directly from the prevalent BOLD fMRI images, offering an alternative to the ASL sequence that is not universally available across research facilities.



ISMRM - Open Science Initiative for Perfusion Imaging (OSIPI): The multi-delay Arterial Spin Labeling Challenge

Icaro A F Oliveira¹, Sriranga Kashyap¹, Henk JMM Mutsaerts^{2,3}, Jan Petr⁴, Joana Pinto⁵, Joseph G Woods⁶, Moss Y Zhao⁷, and Andre Monteiro Paschoal⁸

¹Krembil Brain Institute, University Health Network, Toronto, ON, Canada, ²Radiology and Nuclear Medicine, Vrije Universiteit Amsterdam, Amsterdam UMC location VUmc, Amsterdam, Netherlands, ³Amsterdam Neuroscience, Brain Imaging, Amsterdam, Netherlands, ⁴Helmholtz-Zentrum Dresden-Rossendorf, Dresden, Germany, ⁵Institute of Biomedical Engineering, Department of Engineering Science, University of Oxford, Oxford, United Kingdom, ⁶Wellcome Centre for Integrative Neuroimaging, FMRIB, Nuffield Department of Clinical Neurosciences, University of Oxford, Oxford, United Kingdom, ⁷Department of Neurosurgery, Stanford University, Stanford, CA, United States, ⁸Institute of Physics, University of Campinas, Campinas, Brazil

Keywords: Arterial Spin Labelling, Arterial spin labelling, Challenge; multi-PLD ASL

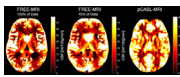
Motivation: The OSIPI ASL Challenge is a community initiative motivated by open science principles that aim to establish good practices in ASL image analysis and Cerebral Blood Flow (CBF) quantification.

Goal(s): The second ASL challenge's main goal is to provide a thorough comparison of existing post-processing pipelines focusing on Multi-PLD methodology.

Approach: The second roadmap will provide different datasets; a population dataset which will bring real variability to the challenge and synthetic data which allows straightforward ground truth comparison.

Results: The second edition of the ASL Challenge will contribute to gaining new insights into the potential sources of variability within the multi-PLD analysis pipeline.

Impact: Through the second edition of the ASL Challenge, we seek to enhance our understanding of multi-PLD analysis in the ASL community. Its success could establish a consensus on the processing of multi-PLD ASL data, positively influencing clinical and scientific practices.



Estimation of cerebral blood flow using the pulse wave amplitude in brain MRI

Julian Glandorf¹, Filip Klimeš¹, Agilo Luitger Kern¹, Andreas Voskrebenzev¹, Marcel Gutberlet¹, Norman Kornemann¹, Frank Wacker¹, Mike Wattjes², and Jens Vogel-Clausen¹

¹Institute for Diagnostic and Interventional Radiology, Hannover Medical School, Hannover, Germany, ²Institute for Diagnostic and Interventional Neuroradiology, Hannover Medical School, Hannover, Germany

Keywords: Perfusion, Quantitative Imaging, CBF, perfusion, quantification, flow-related enhancement, pCASL, imaging speed optimization

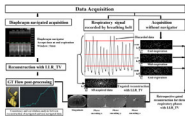
Motivation: Flow-related enhancement (FREE)-MRI could be used to generate phase-resolved perfusion-weighted brain maps.

Goal(s): To test cerebral blood flow (CBF) estimation using the pulse wave amplitude in FREE-MRI. Secondly, the potential for acceleration was evaluated retrospectively.

Approach: Twenty-four healthy subjects had cerebral MRI with balanced steady-state free precession imaging (FREE-MRI) and with pCASL-MRI for comparison.

Results: The value distribution of the estimated CBF showed disparity of the values between both techniques in the histogram. A Kolmogorov-Smirnov test confirmed differing probability distributions. The approximated CBF from FREE-MRI remained stable until 50% of the data was reconstructed and reveals large potential acceleration.

Impact: The proposed technique allows a rough approximation of the cerebral blood flow. Further sequence optimization must be achieved to improve the measurement of lowly perfused tissues. Nevertheless, the technique offers large potential for imaging speed optimization.



Hepatic 5D flow: An Effective Acquisition and Reconstruction Scheme for Portal Vein

Ruiyu Cao¹, Shaohang Li¹, Hongwei Li¹, Ying-Hua Chu², Aiqi Sun³, Ning Jin⁴, Xu Yan², Yunzhu Wu², Daniel Nico Splitthoff⁵, Hao Li¹, and He Wang¹

¹Institute of Science and Technology for Brain-Inspired Intelligence, Fudan University, Shanghai, China, ²MR Research Collaboration Team, Siemens Healthineers Ltd., Shanghai, China, ³Oden Institute for Computational Engineering and Sciences, University of Texas at Austin, Austin, TX, United States, ⁴Siemens Medical Solutions USA, Inc., Chicago, IL, United States, ⁵Siemens Healthcare GmbH, Erlangen, Germany

Keywords: Velocity/Flow, Velocity & Flow

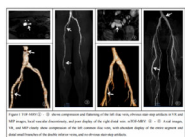
Motivation: 4D flow imaging in the liver suffers from long acquisition time and inefficient motion control.

Goal(s): Address the challenges of prolonged acquisition time and significant motion artifacts in hepatic 4D flow imaging.

Approach: We collected data from all respiratory states without a diaphragm navigator, and retrospectively reconstructed respiratory-resolved 5D flow using simultaneously recorded breathing signal.

Results: This scheme reduced the acquisition time from over 10 minutes to 6-8 minutes, while maintaining consistent image quality with few motion artifacts. High quantitative correlation in hepatic hemodynamic results was found between the results from prospectively navigated data and retrospectively binned data.

Impact: The proposed hepatic 5D flow scheme achieved high image quality and quantitative metrics, compared with those of diaphragm navigated results. This scheme can effectively shorten the acquisition time to 6-8 minutes and mitigate motion artifacts.



The application value of modified time of flight magnetic resonance venography in iliac vein compression syndrome

Li Tao¹, Gang Peng¹, Wei Zhu¹, and Xiaoyong Zhang²

¹Radiology, The First Affiliated Hospital of Chongqing Medical University, Chongqing, China, ²Clinical Science, Philips Healthcare, Chengdu, China

Keywords: Contrast Agents, Blood vessels, Time of flight magnetic resonance venography, Iliac vein compression syndrome

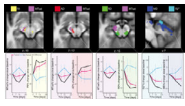
Motivation: The use of respiratory-gated TOF-MRV in assessing the degree of iliac vein compression is easily affected by respiratory uniformity, leading to vascular distortion and corresponding false images.

Goal(s): This study evaluated the diagnostic effectiveness of an improved TOF-MRV (mTOF-MRV) in Iliac vein compression syndrome (IVCS) diagnosis by optimizing key parameters, compared with conventional TOF-MRV.

Approach: Objectively evaluated the deviation of vascular stenosis degree between TOF MRV and mTOF MRV using DSA as the standard.

Results: The mTOF-MRV has better image quality and can accurately detect venous stenosis. It can be applied in the diagnosis of IVCS and further assessments after endovascular interventions.

Impact: mTOF-MRV more accurately located iliac vein stenosis without obvious stair-step artifacts and magnetic sensitivity artifacts, thereby meeting the diagnostic and clinical requirements. It can be applied in the diagnosis of iliac vein compression syndrome and further assessments after endovascular interventions.



Grey and white matter plasticity during motor-skill learning: a longitudinal diffusion MRI study.

Tim Max Emmenegger¹, Simon Schading-Sassenhausen¹, Gergely David¹, Tim Killeen¹, and Patrick Freund^{1,2,3}

¹Spinal Cord Injury Center Balgrist University Hospital, Zurich, Switzerland, ²Wellcome Centre for Human Neuroimaging, UCL Queen Square Institute of Neurology, London, United Kingdom, ³Department of Neurophysics, Max Planck Institute for Human Cognitive and Brain Sciences, Leipzig, Germany

Keywords: Multi-Contrast, Brain, Myelin plasticity, diffusion MRI, DTI, corticospinal tract, hippocampus, cerebellum, sensory motor system

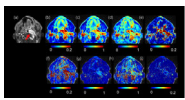
Motivation: MRI studies have demonstrated plastic changes in grey and white matter (GM/WM) during motor skill learning. However, diffusion magnetic resonance imaging (dMRI) might provide additional complementary information in contrast to multi-parametric mapping (MPM), which has been investigated previously.

Goal(s): To investigate training-induced neuroplasticity using dMRI and contextualize them to the MPM findings.

Approach: Acquisition of longitudinal dMRI and MPM during motor skill learning.

Results: We observed overlapping changes in dMRI and MPM metrics following motor skill learning. dMRI was thereby able to capture additional changes within the WM, whereas within the GM, some findings were unique to the MPM protocol.

Impact: dMRI and MPM metrics are sensitive to motor skill learning-induced changes in GM and WM. To combine the two methodologies advances our capability in detecting neuroplasticity changes and might be beneficial for patient rehabilitation.



Fluid mechanics based quantitative transport mapping network for predicting gene expression of nasopharyngeal carcinoma (NPC) patients

Qihao Zhang¹, Dominick Romano², Ben Weppner², Thanh Nguyen¹, Pascal Spincemaille³, and Yi Wang³

¹Weill Cornell Medicine, New York, NY, United States, ²Cornell University, New York, NY, United States, ³Weill Cornell Medicine, New York, NY, United States

Keywords: Perfusion, DSC & DCE Perfusion, Head & Neck Imaging

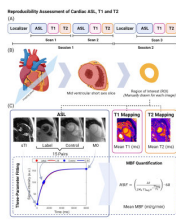
Motivation: To use fluid-mechanics based deep learning method to predict perfusion parameters from dynamic images

Goal(s): We propose to explore the possibility to use neural network trained on simulated data from fluid mechanics simulation to analyze dynamic medical images.

Approach: We use quantitative transport mapping network (QTMnet), which is trained on simulated concentration propagation profile generated from constrained constructive optimization (CCO) and transport equation-based tracer propagation simulation, to predict perfusion parameters including flow rate, permeability, vasculature volume, from DCE MRI images.

Results: QTMnet predict perfusion parameters accurately in simulation study and can distinguish different gene expression group patients comparing with using traditional kinetics model.

Impact: Proposed QTMnet method can be used to predict different perfusion parameters related to dynamic images accurately and automatically without usage of arterial input function.



Reproducibility assessment of multiparametric non-contrast cardiac MRI including ASL, T1 and T2 mapping in healthy controls

Sergio Manuel Solis-Barquero^{1,2}, Veronica Aramendia-Vidaurreta^{1,2}, Ana Ezponda¹, Marta Vidorreta³, Marina Pascual⁴, Gorka Bastarrika¹, and Maria Asuncion Fernandez-Seara^{1,2}

¹Department of Radiology, Clinica Universidad de Navarra, Pamplona, Spain, ²IdISNA, Instituto de Investigación Sanitaria de Navarra, Pamplona, Spain, ³Siemens Healthcare, Madrid, Spain, ⁴Department of Cardiology, Clinica Universidad de Navarra, Pamplona, Spain

Keywords: Arterial Spin Labelling, Arterial spin labelling, Perfusion, Myocardium, T1 Mapping, T2 Mapping, Reproducibility


Motivation: Contrast-agent free techniques are needed in cardiac MRI studies for assessment of patients with coronary artery disease but with contraindications to gadolinium contrast-agents, such as kidney disease.

Goal(s): The aim of this work was to assess the intra and intersession reproducibility of a multiparametric protocol including three non-contrast techniques (ASL, native T1 and T2 mapping) in healthy controls with a wide age range to eventually test the technique in clinical patients.

Approach: Multiparametric non-contrast cardiac MRI in ten healthy controls at 1.5T.

Results: This protocol can offer contrast free alternative for perfusion quantification, T1 and T2 mapping, with good intra and intersession reproducibility.

Impact: Multiparametric cardiac MRI with arterial spin labelling (ASL) perfusion, T1 and T2 mapping could offer a contrast-agent free alternative for patients with kidney disease, or other contraindication to gadolinium agents, with good intra and intersession reproducibility.



Decreased water exchange rate across blood-brain barrier 6-12 months after admission for COVID-19 pneumonia

Frances Robertson¹, Jacqueline Hoare¹, Betty Kadenge¹, Sarah Heany¹, and Ernesta Meintjes¹

¹University of Cape Town, Cape Town, South Africa

Keywords: Arterial Spin Labelling, COVID-19

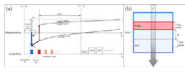Motivation: A proportion of patients admitted to hospital with SARS-CoV-2 infection have cognitive deficits that persist for several months. However, the mechanisms behind persistent neurological symptoms are unclear. Blood-brain barrier (BBB) dysfunction is a possible underlying cause.

Goal(s): We aimed to investigate BBB permeability in participants previously admitted to hospital with SARS-CoV-2 infection (post-acute COVID-19).

Approach: We used a diffusion-prepared pseudo-continuous arterial spin labelling (DP-pCASL) to quantify water exchange rate in post-acute COVID-19 participants and controls.

Results: Post-acute COVID-19 participants demonstrated lower whole brain water exchange rates across the BBB than controls, but no differences in arterial transit time or cerebral blood flow.

Impact: This is the first study to report reduced water exchange across the blood brain barrier in the context of post-acute infection with SARS-CoV-2. This may implicate glymphatic system dysfunction as a mechanism for neurological symptoms associated with long COVID-19.



Multi-Tag Time-SLIP Simulation Beyond the General Kinetic Model

Vadim Malis¹ and Mitsue Miyazaki²

¹Radiology, UC San Diego, La Jolla, CA, United States, ²Radiology, UC San Diego, La Jolla, CA, United States

Keywords: Arterial Spin Labelling, Arterial spin labelling, Simulation

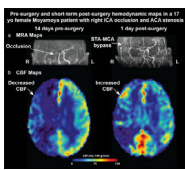
Motivation: We identified a gap in understanding multi-tag Time-SLIP MRI dynamics, crucial for advanced perfusion analysis, particularly in varying physiological and pathological states.

Goal(s): Our goal was to develop a comprehensive simulation tool to accurately predict signal changes in multi-tag Time-SLIP ASL MRI across diverse flow conditions.

Approach: We employed MATLAB to simulate numerically non-selective and selective multi-tag Time-SLIP pulse sequences, applying Bloch equations to model tissue-specific magnetization and blood flow perfusion dynamics.

Results: Simulations showed distinct magnetization patterns between odd and even pulse tags, aligning with physiological flow rates.

Impact: This simulation tool enables researchers to customize Time-SLIP MRI protocols for detailed study of fluid dynamics across the body, from blood to CSF flow. It provides a solid foundation for developing more comprehensive ASL-related simulations.



Direct Revascularization Improves Vascular Hemodynamics in Pediatric Moyamoya Patients

Moss Y Zhao¹, Elizabeth Tong², Michael Moseley², Greg Zaharchuk², and Gary Steinberg¹

¹Department of Neurosurgery, Stanford University, Stanford, CA, United States, ²Department of Radiology, Stanford University, Stanford, CA, United States

Keywords: Arterial Spin Labelling, Perfusion, Pediatrics

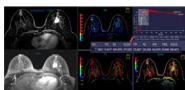
Motivation: Moyamoya is a progressive cerebrovascular disorder affecting hemodynamics and the disease often begins during childhood. However, the non-invasive assessments of hemodynamics in pediatric Moyamoya patients remain an open question.

Goal(s): Investigate the CBF change before and after revascularization in pediatric Moyamoya patients.

Approach: CBF in 42 patients was measured using arterial spin labeling on a 3T MRI 1 week before and within 2 weeks after revascularization. CBF in regions affected by vasculopathy was compared before and after revascularization.

Results: CBF in regions affected by vasculopathy increased significantly after revascularization.

Impact: ASL can be utilized to evaluate CBF in pediatric Moyamoya patients before and after direct revascularization.



Ultrafast breast MRI in differentiating high-grade from benign and low-grade malignant breast lesions

Yang Li¹, Haifa Liu¹, Qi Wang¹, Qian Xu¹, Mengzhu Wang², Robert Grimm³, and Mingwei Qi¹

¹The Fourth Affiliated Hospital of Hebei Medical University, Shijiazhuang, China, ²MR Research Collaboration, Siemens Healthineers Ltd, Beijing, China, ³MR Application Predevelopment, Siemens Healthineers AG, Erlangen, Germany

Keywords: Perfusion, Contrast Mechanisms, breast tumor; Ultrafast Breast MRI

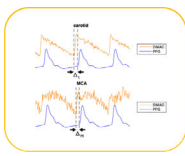
Motivation: Ultrafast (UF)-DCE MRI is a novel approach to obtain kinetic information very early after enhancement, which promises improved capabilities in differentiating malignant from benign lesions of breast cancers.

Goal(s): The early hemodynamic characteristics of lesions using breast UF-DCE MRI were systematically investigated to evaluate the value of the relevant kinetic parameters in the diagnosis of different grades of breast cancer.

Approach: The kinetic parameters of UF-DCE MRI were calculated to differentiate the different grades of breast cancer.

Results: The kinetic parameters of UF-DCE MRI can be used to distinguish high-grade from benign and low-grade breast cancer.

Impact: Breast ultrafast DCE MRI was used to explore the early hemodynamic characteristics of the lesions and evaluate the value of the relevant dynamic parameters in the diagnosis of different grades of breast cancer.



Measuring pulse-wave velocity in the healthy human brain using dynamic inflow magnitude contrast (DIMAC) MRI

Ian D Driver¹, Melissa E Wright¹, Andrew Crofts¹, Saajan Davies¹, Hannah L Chandler¹, and Kevin Murphy¹

¹Cardiff University Brain Research Imaging Centre (CUBRIC), School of Physics & Astronomy, Cardiff University, Cardiff, United Kingdom

Keywords: Velocity/Flow, Brain, Cerebrovascular health & arterial stiffness

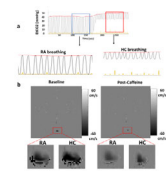
Motivation: Arterial stiffness, a key marker of cardiovascular health, can be monitored by measuring pulse-wave velocity. However, current methods do not extend into the brain due to an inability to resolve the pulse waveform on a beat-to-beat basis for intracranial arteries.

Goal(s): Our goal is to demonstrate the concept of measuring intracranial pulse-wave velocity using dynamic inflow magnitude contrast (DIMAC) MRI.

Approach: We measured intracranial pulse-wave velocity by measuring the pulse-wave delay between internal carotid and middle cerebral arteries.

Results: The arterial pulse-wave delay between the internal carotid artery and the middle cerebral artery was 29 ± 14 ms, corresponding to a pulse-wave velocity of 6.8 ± 2.2 m/s.

Impact: These results are the first stage in establishing pulse-wave velocity as a new non-invasive MRI biomarker for cerebrovascular health, providing a novel tool to investigate the role of arterial stiffness in healthy ageing and brain pathology.



Caffeine reduces cerebrovascular reactivity in addition to lowering basal perfusion

Dinil Sasi Sankaralayam¹, Zhiyi Hu^{1,2}, Cuimei Xu³, Dengrong Jiang¹, Peiying Liu⁴, Abhay Moghekar⁵, and Hanzhang Lu^{1,2,6}

¹Russell H Morgan Department of Radiology and Radiological Sciences, Johns Hopkins University School of Medicine, Baltimore, MD, United States, ²Department of Biomedical Engineering, Johns Hopkins University, Baltimore, MD, United States, ³Johns Hopkins University School of Medicine, Baltimore, MD, United States, ⁴Department of Diagnostic Radiology and Nuclear Medicine, University of Maryland School of Medicine, Baltimore, MD, United States, ⁵Department of Neurology, Johns Hopkins University School of Medicine, Baltimore, MD, United States, ⁶F. M. Kirby Research Center for Functional Brain Imaging, Kennedy Krieger Research Institute, Baltimore, MD, United States

Keywords: Perfusion, Velocity & Flow, Cerebrovascular reactivity

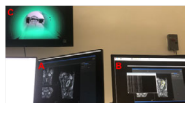Motivation: Caffeine, one of the widely used psychoactive substances is known to reduce basal cerebral blood flow (CBF). However, its effect on vasodilatory capacity has not been characterized

Goal(s): To evaluate the impact of Caffeine on cerebrovascular reactivity (CVR)

Approach: 8 healthy caffeine-naïve volunteers were scanned for baseline (pre-caffeine) and post-Caffeine CVR measurements using BOLD MRI and phase-contrast MRI (PC)-MRI during normal air breathing and hypercapnia using 5% CO₂ enriched gas mixture

Results: There was a significant reduction in blood-flux (BF) during room-air ($p=0.002$) and hypercapnia ($p=0.0015$) post caffeine administration (variation=33.7% and 41.3% respectively). PC-CVR and BOLD-CVR were reduced by 32.7% ($p=0.006$) and 22.5% ($p=0.006$) respectively

Impact: This study's findings provide valuable insights into the impact of caffeine on cerebrovascular reactivity (CVR), revealing a significant reduction after caffeine intake. Findings would be beneficial in reducing the inter-subject variability of CVR by improving the sensitivity in detecting abnormalities.



Development and in-vivo testing of an MR-compatible biofeedback device for MR-guided radiotherapy simulation and treatment

Travis Salzillo¹, Yao Ding¹, and Jihong Wang¹

¹MD Anderson Cancer Center, Houston, TX, United States

Keywords: New Devices, Motion Correction, Biofeedback


Motivation: Biofeedback during radiotherapy simulation and treatment on conventional linacs improves the accuracy and reproducibility of patient alignment, especially those using breath-hold. However, commercial devices cannot operate in MR environments.

Goal(s): The goal of this study was to develop an MR-compatible biofeedback device and test its utility in volunteer studies.

Approach: The device consists of a single-board computer and addressable LED strip, which was automatically controlled by tracking anatomic motion in CINE MR images.

Results: Initial volunteer studies using the device in an MR linac demonstrated that biofeedback-guided breath-hold resulted in more accurate and consistent target alignment compared to self-guided breath-hold.

Impact: MR-compatible biofeedback devices can facilitate and improve breath-hold techniques for MR-guided radiotherapy simulation and treatment. Furthermore, incorporation of CINE MR images to measure changes in internal anatomy improves target alignment relative to existing devices that use surface imaging.



A 36 month assessment of ASL reproducibility using a commercial perfusion phantom

Aaron Oliver-Taylor¹, Shreya Nair², Tom Hampshire¹, Alessia Bianchi², Olga Ciccarelli², Marios Yiannakas², and Xavier Golay^{1,3}

¹Gold Standard Phantoms Limited, Sheffield, United Kingdom, ²NMR Research Unit, UCL Queen Square Institute of Neurology, London, United Kingdom, ³Brain Repair and Rehabilitation, UCL Queen Square Institute of Neurology, London, United Kingdom

Keywords: Phantoms, Phantoms, ASL, perfusion

Motivation: During longitudinal studies it is important to ensure quality assurance of MRI data. Here we use a commercially available perfusion phantom for QA of ASL in a 40-patient placebo-control study.

Goal(s): The goal of this study was to assess the utility of a perfusion phantom for QA of ASL MRI in a clinical trial setting.

Approach: Inversion recovery T1 measurements and pseudo-continuous ASL at 3 different phantom flow rates were scanned periodically on a 3T MRI system over a 36 month period.

Results: Once data due to errant phantom behaviour was discounted, the QA metric of labelling efficiency was in a reasonable range.

Impact: By acquiring independent T1 measures of the phantom's perfusate, then computing ASL perfusion maps and comparing against the phantom's pump flow rate, a useful QA metric can be established that can provide confidence in acquired subject ASL data.

MR seq	Risk	MR personnel	Patients	Non-MR personnel
MRSA	MRSA	100%	100%	100%
MRSA	MRSA	100%	100%	100%
MRSA	MRSA	100%	100%	100%
MRSA	MRSA	100%	100%	100%
MRSA	MRSA	100%	100%	100%
MRSA	MRSA	100%	100%	100%
MRSA	MRSA	100%	100%	100%
MRSA	MRSA	100%	100%	100%
MRSA	MRSA	100%	100%	100%
MRSA	MRSA	100%	100%	100%

The hierarchy of hazard controls in MR safety practice

Ives R Levesque^{1,2} and Evan McNabb³

¹Medical Physics Unit and Gerald Bronfman Department of Oncology, McGill University, Montreal, QC, Canada, ²Medical Physics, McGill University Health Centre, Montreal, QC, Canada, ³Medical Imaging, McGill University Health Centre, Montreal, QC, Canada

Keywords: Safety, Safety

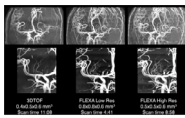
Motivation: MR safety guidance formulated by experts from the MR community build upon a combination of experience and technical expertise. MR safety guidance may benefit from assessment based on general workplace safety practices.

Goal(s): To critically assess MR safety guidance and practices using the hierarchy of hazard controls.

Approach: MR safety practices were scored using a 5-point scale derived from the hierarchy of hazard controls, in several areas of risk for MR personnel, patients, and non-MR personnel.

Results: Hazard controls for non-MR personnel had consistently high effectiveness scores, while those for MR personnel and patients had moderate effectiveness scores, with a greater range.

Impact: The analysis presented in this work could serve as a tool to analyse choices made in the deployment of safety measures, to motivate decision- or policy-making, or as a tool for assessment of MR safety programs.



Fast and High-Resolution Intracranial MR Angiography at 7T using FLEXA

Naoyuki Takei¹, Brian Burns², Nathan T Roberts³, Xucheng Zhu², and Tetsuya Wakayama⁴

¹GE HealthCare, Tokyo, Japan, ²GE HealthCare, Menlo Park, CA, United States, ³GE HealthCare, Waukesha, WI, United States, ⁴GE HealthCare, Hino, Japan

Keywords: High-Field MRI, High-Field MRI, 7T, 3DTOF, Non-contrast MRA, High gradient performance, microvascular


Motivation: Non-contrast 3DTOF demonstrates visualizing the cerebral microvasculature at 7T MRI, but the scan time is too long, typically about 10 minutes due to requiring high spatial resolution.

Goal(s): Our goal was to reduce the acquisition time by a factor of 2.

Approach: We utilize FLEXA on the high gradient performance system at 7T.

Results: Comparable image quality to 3DTOF was obtained with FLEXA technique with a factor of 2 decrease in acquisition time.

Impact: The improvement in acquisition speed through FLEXA comes from the strategy of short TR with thin slab and opens new standard for scan protocol optimization at 7T MRA.



Development of a phantom for assessment of signal-to-noise ratio in whole-body diffusion-weighted MRI

Ciara Harrison^{1,2,3}, Sam Keaveney^{1,2}, Mihaela Rata^{1,2}, Naomi Mcaddy¹, David Collins^{1,2}, Geoff Charles-Edwards^{1,2}, and Jessica M Winfield^{1,2}

¹MRI Unit, The Royal Marsden NHS Foundation Trust, London, United Kingdom, ²Division of Radiotherapy and Imaging, The Institute of Cancer Research, London, United Kingdom, ³Medical Physics, St George's University Hospitals NHS Foundation Trust, London, United Kingdom

Keywords: Phantoms, Whole Body, Whole-body diffusion-weighted imaging

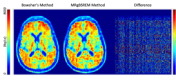
Motivation: Poor signal-to-noise ratio (SNR) of whole-body diffusion-weighted images (WB-DWI) impacts the diagnostic exam quality in whole-body MRI. Evaluating SNR of WB-DWI using healthy volunteers is challenging when developing imaging protocols for multi-centre studies.

Goal(s): Develop a phantom for assessing whether a proposed WB-DWI protocol will provide adequate SNR in patient examinations.

Approach: A phantom was developed which replicated relevant MR properties of WB-MRI patients. We measured SNR using the phantom and qualitatively graded SNR in subjects.

Results: Good correlation was found between the phantom and the subject data and a discrimination threshold between good and poor quality exams was determined.

Impact: A phantom can be used to assess the SNR of WB-DWI protocols and shows good correlation with qualitative image quality, enabling faster, quantitative optimisation of SNR in WB-DWI protocols when setting up multi-centre studies.



Comparing Bowsher's Method to MRgBSREM in PET Recon with MR-priors in the Presence of Mismatch Between MRI and PET Images

Mehdi Khalighi¹, Matthew Spangler-Bickell², Floris Jansen², Daniel Litwiller², Dawn Holley¹, Hillary Vossler¹, Elizabeth Mormino¹, Michael Moseley¹, and Greg Zaharchuk¹

¹Stanford University, Stanford, CA, United States, ²GE HealthCare, Waukesha, WI, United States

Keywords: PET/MR, PET/MR, MR Priors, Motion Correction

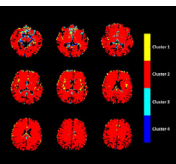
Motivation: Using MR-priors in PET reconstruction has been performed in numerous studies. While MR-priors provide more SNR and better resolution to PET-images, without considering motion there may be misalignment between PET and MR images which leads to crosstalk artifacts. Another concern is mismatch between MR and PET images which can potentially affect the final PET image.

Goal(s): To compare the two most-widely used PET recon with MR-priors methods: the Bowsher's method and MRgBSREM.

Approach: We created an MR-series with severe line artifacts and used it as MR-priors in both methods.

Results: We have shown that MRgBSREM handles these mismatches better than the Bowsher's method.

Impact: MRgBSREM is more robust to mismatches between PET and MR. This is achieved by adding a PET-seed image to identify similar-voxels which avoids the situation in which voxels with significantly different PET-uptake would be considered similar based only on MR-images.



Quantifying Spatial Variations of Cardiac-Induced Volumetric Strain Using DENSE MRI: Insight from an Observational Study

Ellen van Hulst¹, Mario G. Báez-Yañez¹, Ayodeji L. Adams¹, Geert Jan Biessels², and Jacobus J.M. Zwanenburg¹

¹Center for Image Sciences, University Medical Center Utrecht, Utrecht, Netherlands, ²Department of Neurology, University Medical Center Utrecht, Utrecht, Netherlands

Keywords: Neurofluids, Brain, Volumetric strain; Brain tissue deformation


Motivation: The heartbeat causes deformations and volumetric strain in the surrounding brain tissue which can be observed using Displacement Encoding with Stimulated Echoes (DENSE) MRI. Local variations in volumetric strain reveal both expansion and compression in individual voxels or regions.

Goal(s): To offer insights into the heterogeneous patterns seen in volumetric strain maps.

Approach: Volumetric strain data of nine subjects was included and clustered (k-means) into four clusters.

Results: Both expanding and compressing clusters were found in all subjects. Compressing clusters were mostly found at the periphery of the brain and possibly reflect structures facilitating fluid movement (sulci and veins).

Impact: Clustering volumetric strain data into individual clusters with similar voxels reveals distinct volumetric strain profiles in DENSE data. Potentially, these clusters can be used to cleanup DENSE data from fluid-related artifacts to make the data specifically reflect brain tissue strains.



Imaging Artifacts of Novel Laser-cut Venous Stents: Dependence between Stent Design and Radiofrequency Shielding

Lisa Regler¹, Simon Reiss¹, Niklas Verloh², Wibke Uller², and Michael Bock¹

¹Division of Medical Physics, Dept. of Diagnostic and Interventional Radiology, Medical Physics, University Medical Center Freiburg, Faculty of Medicine, University of Freiburg, Freiburg, Germany, ²Dept. of Diagnostic and Interventional Radiology, Medical Physics, University Medical Center Freiburg, Faculty of Medicine, University of Freiburg, Freiburg, Germany

Keywords: In Silico, Artifacts


Motivation: RF shielding up to 95% in stents creates image artifacts that can impact an accurate diagnosis of vessel patency after stent implantation.

Goal(s): The association between design parameters of novel venous stents and their RF shielding properties were investigated.

Approach: Therefore, field simulations and measurements were performed of the relative induced B_1 in venous stents with different lengths and cell geometries.

Results: Edge length of the stent cells and their orientation relative to the B_1 transmit field determine the amount of RF shielding.

Impact: The work provides information about the correlation of venous stent geometries and RF shielding artifacts. Sequence parameters e.g. excitation flip angle could be adapted for different stent models to possibly achieve higher intraluminal signal in post-implantation MRI venography.



Design of a nonlinear human-breast gradient coil with controllable gradient variation

Feng Jia¹, Philipp Amrein^{1,2}, Maxim Zaitsev¹, and Sebastian Littin¹

¹Division of Medical Physics, Department of Diagnostic and Interventional Radiology, Medical Center University of Freiburg, Faculty of Medicine, University of Freiburg, Freiburg, Germany, ²Neoscan-Solutions GmbH, Magdeburg, Germany

Keywords: Gradients, Gradients


Motivation: To assess diffusion metrics on a cellular scale necessitates much higher gradient amplitudes. A local nonlinear breast gradient coil needs methods of controlling the field variation during the coil design stage.

Goal(s): Control the y-axis gradient variation of a double layer local breast gradient coil to achieve far above 1T/m in the whole target region.

Approach: Incorporation of a constraint to control the variation of the gradient along the y-axis with a double-layer current-carrying surface.

Results: A non-linear local human breast gradient coil with a gradient strength between 1.61 and 3.74 T/m for a current of 650 A was designed.

Impact: The coil design with a subsequent implementation paves the way to the application of novel diffusion imaging techniques for the detection and characterization of breast cancer.



Characterisation of 3D Printed Materials for MRI Applications

George Michael John Bruce¹, David Brennan¹, and Pauline Hall Barrientos¹

¹MRI Physics, NHS Greater Glasgow and Clyde, Glasgow, United Kingdom

Keywords: Phantoms, Precision & Accuracy, 3D Printing, Phantoms, Quantification, Material Characterisation

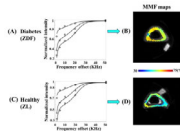
Motivation: 3D printed materials offer the capability of manufacturing custom phantoms or coil prototypes. While materials for other modalities (such as CT) are widely available, the same cannot be said for MRI.

Goal(s): The goal of this project was to characterise a wide range of 3D printed materials for use in MRI.

Approach: Using standardised sample sizes, and relaxation property mapping sequences.

Results: Some materials, such as Nylon, proved invisible to MRI. Other materials, such as OrganLike, showed relaxation properties similar to those in the brain at 3T.

Impact: 3D printing offers the potential to rapidly create low cost, reproducible prototypes for MRI. This work provides an extensive list of the properties of materials, aiding others in narrowing down a material of choice.



Macromolecular fraction and magnetization exchange rate acquired with UTE-MRI differ in the tibial bone of diabetic rats: a feasibility study.

Dina Moazamian¹, Soo Hyun Shin¹, Saeed Jerban², Alireza Tyarani¹, Arya Suprana¹, Hamidreza Shaterian Mohammadi¹, Eddie Fu¹, Christine B Chung^{1,3}, Yajun Ma², Nigel B Calcutt⁴, Eric Y Chang², and Jiang Du^{2,5}

¹University of California San Diego, San Diego, CA, United States, ²Radiology, University of California San Diego, San Diego, CA, United States, San Diego, CA, United States, ³Radiology service, VA San Diego Healthcare System, San Diego, CA, United States, ⁴Pathology, University of California San Diego, San Diego, CA, United States, ⁵VA San Diego Healthcare System, San Diego, CA, United States

Keywords: High-Field MRI, Bone, Diabetes bone, UTE-MRI, MMF, Exchange rate

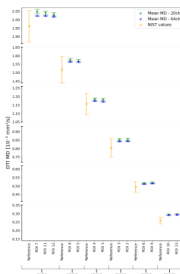
Motivation: Increased risk of fractures in patients with type-2 diabetes mellitus (T2DM) despite higher average bone mineral density is unexplained with routine diagnostic tools like DEXA and CT.

Goal(s): This study aimed to examine the feasibility of using ultrashort echo time (UTE) magnetization transfer (MT) modeling to detect the potential differences between T2DM and normal rats.

Approach: The macromolecular fraction (MMF) and proton exchange rate (k_{ab}) from UTE-MT modeling on the tibial bone of Zucker diabetic fatty (ZDF) and Zucker lean (ZL) rats were compared.

Results: There was a significant difference in MMF and k_{ab} measures between the two groups.

Impact: The MMF and k_{ab} measures can detect potential bone alternations related to T2DM which may help to better understand the pathogenesis of T2DM bone fractures.



Bias and Variability of Mean Diffusivity from DTI Across Two Head Coils: a Traceable Phantom Study.

Agnieszka Sierhej^{1,2,3}, Matt Hall^{1,2}, Nadia Smith², and Chris Clark^{1,3}

¹University College London, London, United Kingdom, ²National Physical Laboratory, Teddington, United Kingdom, ³Great Ormond Street Hospital for Children NHS Foundation Trust, London, United Kingdom

Keywords: Phantoms, Quantitative Imaging, Reproducibility

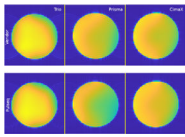
Motivation: Variability and bias of diffusion parameters need to be assessed to separate the measurement-induced variability from biological effects.

Goal(s): Our goal was to assess the bias and variability of mean diffusivity (MD) from the Diffusion Tensor Model using a traceable phantom.

Approach: The NIST/QIBA phantom was scanned multiple times using two different head coils on the same system. The differences between MD measured using different head coils and bias to NIST-reported values were investigated.

Results: A significant difference in measured MD with two coils can be found across multiple vials. Both coils introduce non-negligible bias to NIST-reported values for lower MD values.

Impact: Using traceable phantoms is essential in the development of Diffusion MRI-based Quantitative Imaging Biomarkers (QIBs). Different head coils can introduce significant differences across MD values and should be treated as confounding factors in QIBs studies.



Automated Vendor-Independent Open-Source Quality Assurance Protocol using Pulseq

Qingping Chen¹, Frank Zijlstra^{1,2,3}, Sebastian Littin¹, Jon-Fredrik Nielsen⁴, and Maxim Zaitsev¹

¹Division of Medical Physics, Department of Radiology, University Medical Center Freiburg, Faculty of Medicine, University of Freiburg, Freiburg, Germany, ²Department of Radiology and Nuclear Medicine, St. Olav's University Hospital, Trondheim, Norway, ³Department of Circulation and Medical Imaging, NTNU - Norwegian University of Science and Technology, Trondheim, Norway, ⁴Functional MRI Laboratory, University Of Michigan, Ann Arbor, MI, United States

Keywords: System Imperfections, System Imperfections: Measurement & Correction, Vendor-Neutral Automated Quality Assurance

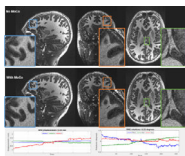
Motivation: Ensuring comparable performance of MR protocols across vendors and over time duration.

Goal(s): To implement an easy-to-use vendor-independent quality control pulse sequences and data analysis routines.

Approach: Relying on Pulseq as a vendor-independent MR pulse sequence environment, we implemented the established quality assurance protocols (ACR/fBIRN). Following the image reconstruction from the acquired data, performed either on the scanner or off-line in Gadgetron, images are analyzed by the open-source Matlab pipeline.

Results: The proposed protocol has been tested on three 3T Siemens scanners with over a decade difference in the manufacturing date and has been successfully executed on a 3T GE scanner.

Impact: The proposed protocol and post-processing scripts allow for easy and streamlined quality assurance, contributing an essential component for Pulseq to become usable in large scale multicenter imaging studies.



Pushing the image quality by integrating FatNav and pTx Universal Pulses in MPRAGE and MP2RAGE sequences at 7T

Franck Mauconduit¹, Thomas Diraison¹, Aurelien Massire², Vincent Gras¹, Alexandre Vignaud¹, Daniel Gallichan³, and Nicolas Boulant¹

¹University Paris-Saclay, CEA, CNRS, BAOBAB, NeuroSpin, Gif-sur-yvette, France, ²Siemens Healthcare SAS, Courbevoie, France, ³CUBRIC, Cardiff, United Kingdom

Keywords: High-Field MRI, High-Field MRI

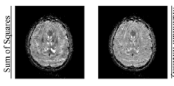
Motivation: Ultra-high field MRI of the brain suffers from an increased B_1^+ inhomogeneity as well as involuntary motion artifacts when very high spatial resolution is targeted.

Goal(s): Integration of a FatNav technique into pTx Universal Pulse sequences would be beneficial to reach the best image quality at very high resolution.

Approach: An MP(2)RAGE sequence using GRAPE pTx universal pulses was modified to integrate a FatNav module. High-resolution protocols were acquired in vivo on the brain.

Results: Very high-quality images were obtained throughout the brain and cerebellum thanks to FatNav motion correction and pTx Universal Pulses.

Impact: The ultra-high field community targetting high-resolution protocols on the whole brain would benefit from a FatNav-enabled PASTEUR package to bring robust protocols against B_1^+ inhomogeneities and involuntary motion of the head.



Bilateral Orthogonality Generating Acquisitions Method for Homogenous Balanced Steady-State Free Precession at 7T

Çelik Boğa¹ and Anke Henning¹

¹UT Southwestern Medical Center, Dallas, TX, United States

Keywords: Parallel Transmit & Multiband, Brain, bSSFP, parallel transmission, transmit field inhomogeneity


Motivation: Elimination of the transmit field inhomogeneity effects in the brain for T₂ contrast at 7T.

Goal(s): Removing the transmit field inhomogeneity effects in balanced steady state free precession acquisitions using Bilateral Orthogonality Generative Acquisitions method.

Approach: Bilateral Orthogonality Generative Acquisitions method is implemented at dual channel parallel transmit 7T system using several balanced steady state free precession acquisitions with varying scan parameters to eliminate the transmit field inhomogeneity effects and reduce the banding artifacts effects via different combining schemes in the final image.

Results: T₂ contrast was obtained without the transmit field inhomogeneity effects but residual banding artifacts exists in the final images.

Impact: T₂ contrast can be achieved without the transmit field inhomogeneity effects in the brain using balanced steady state free precession sequence.



Inhomogeneity-informed Field-fitting for Quantitative Susceptibility Mapping (if-QSM)

Alexandra Grace Roberts¹, Alexey Dimov², Thanh Nguyen², Pascal Spincemaille², and Yi Wang^{2,3}

¹Electrical and Computer Engineering, Cornell University, New York, NY, United States, ²Radiology, Weill Cornell Medicine, New York, NY, United States, ³Biomedical Engineering, Cornell University, New York, NY, United States

Keywords: Bioeffects & Magnetic Fields, Artifacts


Motivation: Inhomogeneity in measured multi-gradient echo (mGRE) field data corrupts reconstructions of quantitative susceptibility maps by obscuring the tissue field of interest with strong background field.

Goal(s): To extend the voxel spread function (VSF) library implementation to a nonzero phase offset and demonstrate improvements on QSM.

Approach: The measured field was estimated and inhomogeneity contributions computed using the extended library implementation. The inhomogeneity field was then estimated and subtracted from the total field to reduce the influence of strong background fields in the QSM reconstruction

Results: Inhomogeneity-informed field-fitting for QSM is shown to improve total field reconstructions of the brain, carotid, and cervical spine.

Impact: The voxel spread function (VSF) library implementation is extended to include initial phase offset contributions and reduce the effect of field inhomogeneity in quantitative susceptibility map (QSM) reconstruction.



Towards an Intraoral Coil Array Design for Dental MRI

Agazi Samuel Tesfai¹, Tim Hilgenfeld², Michael Bock¹, and Ali Caglar Özen¹

¹Division of Medical Physics, Department of Diagnostic and Interventional Radiology, University Medical Center Freiburg, Faculty of Medicine, University of Freiburg, Freiburg, Germany, ²Department of Neuroradiology, Heidelberg University, Heidelberg, Germany

Keywords: RF Arrays & Systems, RF Arrays & Systems, intraoral, dental, maxillofacial, RF coil

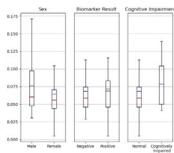
Motivation: In dental diagnostics MRI provides an improved soft tissue contrast for endodontic, craniomaxillofacial and implant applications with better visibility of anatomical structures.

Goal(s): An intraoral coil array is introduced for dental MRI to investigate feasibility, achievable signal gain and parallel acquisition performance.

Approach: Coil element size, material, and shape properties are investigated with respect to image SNR. The array is adjusted to the dental anatomy on a 3D phantom to estimate the sensitivity and the g factor of parallel imaging.

Results: Intraoral coil array improves SNR, spatial resolution and provides a homogenous B₁ receive profile. It allows parallel imaging to minimize measurement time.

Impact: Intraoral coil arrays can enhance MRI of small dental structures, required for endodontics, while increasing the spatial coverage in oral cavity. Compared to single-loop coils, a more homogeneous receive sensitivity can be achieved and parallel imaging becomes feasible.



Brain Tissue Displacement and Strain Measures in an Alzheimer's Disease Cohort using DENSE

Caroline Doctor¹, Leonardo Rivera², Laura Burns Eisenmenger³, Sterling Johnson⁴, and Kevin Johnson⁵

¹Department of Medical Physics, University of Wisconsin, Madison, Madison, WI, United States, ²Department of Medicine, Department of Medical Physics, University of Wisconsin, Madison, Madison, WI, United States, ³Department of Radiology, University of Wisconsin, Madison, Madison, WI, United States, ⁴Department of Medicine, University of Wisconsin, Madison, Madison, WI, United States, ⁵Department of Medical Physics, Department of Biomechanical Engineering, Department of Radiology, University of Wisconsin, Madison, Madison, WI, United States

Keywords: Neurofluids, Alzheimer's Disease, Aging, Brain, Blood Vessels, Cardiovascular, Dementia, Flow, Neuro, Neurodegeneration, Neurofluids, Velocity & Flow

Motivation: Cardiac driven motions may affect Alzheimer's Disease.

Goal(s): The goal was to provide preliminary results on the success of measuring the displacement and strain of brain tissues due to Cardiac Arterial Pulsations (CAPs) using DENSE (Displacement ENcoding with Stimulated Echoes) in patients with AD and age-comparable controls.

Approach: DENSE scan data from a sample of 133 volunteers was processed and evaluated for trends in the derived displacement and strain information.

Results: High variability was found in the displacement measures, and future work is needed to determine the confounding factors behind the variability and to what degree those factors can be minimized going forward

Impact: DENSE MR was used to measure displacement of brain tissue from cardiac effects in Alzheimer's disease (AD) patients and age-comparable controls. Preliminary results are inconclusive and future work is needed to determine what confounding factors are affecting the displacement measures.



Design of a novel double-tuned RF coil system for 1H/13C MR imaging at 7T

Feng Du^{1,2}, Nan Li^{1,2}, Jie Zhou³, Zhe Wang⁴, Xiaoliang Zhang⁵, Hairong Zheng^{1,2}, and Ye Li^{1,2}

¹Lauterbur Imaging Research Center, Shenzhen Institutes of Advanced Technology, Chinese Academy of Sciences, Shenzhen, China, ²Key Laboratory for Magnetic Resonance and Multimodality Imaging of Guangdong Province, Shenzhen, China, ³Tsinghua University, Beijing, China, ⁴State Key Laboratory of Brain and Cognitive Science, Beijing MRI Center for Brain Research, Institute of Biophysics, Chinese Academy of Sciences, Beijing, China, ⁵Department of Biomedical Engineering, State University of New York, Buffalo, NY, United States

Keywords: RF Arrays & Systems, RF Arrays & Systems


Motivation: Hyperpolarized ¹³C MR imaging is of particular interest in cancer applications such as tumor staging and monitoring treatment response as it provides unique real-time metabolic information.

Goal(s): This work is to develop a novel double-tuned RF coil that can achieve uniform excitation and highly sensitive acquisition for ¹H/¹³C MR imaging at 7T.

Approach: The numerical electromagnetic simulation was utilized to evaluate the feasibility and performance in s-parameters and B₁⁺ field distributions. The bench tests were conducted to further validate the performance.

Results: These simulated and measured results indicated that the development of an efficient ¹H/¹³C RF coil for MR imaging at 7T.

Impact: A novel double-tuned RF coil system that can achieve uniform excitation and highly sensitive acquisition for ¹H/¹³C MR imaging at 7T was developed. This coil system has the potential to be used for hyperpolarized ¹³C MRI at ultra-high field.



Identifying potential therapeutic targets for focal transcranial magnetic stimulation (TMS) in a rat model of cocaine dependence

Hanbing Lu¹, Samantha Hoffman¹, and Yihong Yang¹

¹Neuroimaging Research Branch, National Institute on Drug Abuse, NIH, Baltimore, MD, United States

Keywords: Small Animals, Brain, TMS, CBV, basal metabolism

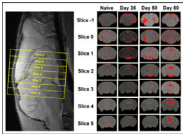
Motivation: Transcranial magnetic stimulation (TMS) shows promise as a therapeutic intervention for many neuropsychiatric conditions. Yet, pinpointing the appropriate stimulation target remains elusive.

Goal(s): To identify brain regions affected by prolonged cocaine exposure, and to identify potential targets for focal TMS.

Approach: Basal CBV were mapped by injecting iron-oxide contrast. Multi-echo gradient echo and spin echo sequences were employed to generate maps of 05732972-a323-4027-8676-ccee7744913e">R2.

Results: Many brain regions, including the prelimbic cortex, exhibited a significant decrease in basal CBV following prolonged cocaine exposure. The prelimbic cortex is situated relatively close to the cortical surface and presents a promising candidate for TMS.

Impact: Likely the first attempt to identify TMS targets using the CBV mapping approach.



Blood brain barrier permeability characterization in the NOD-EAE mouse model of secondary progressive multiple sclerosis using MRI

Mohammed Salman Shazeeb¹, Nellwyn Hagan², and Xiaoyou Ying²

¹University of Massachusetts Chan Medical School, Worcester, MA, United States, ²Sanofi, Cambridge, MA, United States

Keywords: Biology, Models, Methods, Multiple Sclerosis, blood brain barrier permeability


Motivation: Blood brain barrier (BBB) dysregulation is one of the earliest signs of multiple sclerosis (MS) and the mechanism underlying BBB breakdown is not completely understood.

Goal(s): We sought to use the non-obese diabetic experimental allergic encephalomyelitis (NOD-EAE) mouse model of secondary progressive MS to understand BBB breakdown in efforts to explore potential MS therapeutics.

Approach: MRI was used to quantify BBB permeability metrics using gadolinium contrast agent.

Results: We quantified the spatial and temporal characterization of BBB permeability in NOD-EAE mice with progressing disease using MRI. These quantifying parameters can potentially be used to test the effect of therapeutic agents on BBB breakdown.

Impact: The NOD-EAE mouse model of secondary progressive multiple sclerosis (SPMS) can potentially be used to assess blood brain barrier characteristics using contrast-enhanced MRI in efforts to test therapeutic agents that can be used in the treatment of SPMS.



Measurement of awake rats CSF pulsation using EPI-based resting-state fMRI data

Dongho Shin¹, Jun-Hee Kim¹, and Sung-Hong Park¹

¹KAIST, Daejeon, Korea, Republic of

Keywords: Neurofluids, Neurofluids

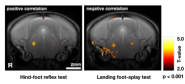
Motivation: This research aims to explore the relationship between CSF dynamics and BOLD signals using EPI-based resting-state fMRI data from an open database of rat models.

Goal(s): Rodents and humans are compared regarding CSF dynamics and the BOLD signal.

Approach: The study computes temporal correlations between CSF pulse, CSF edge, and the BOLD signal.

Results: While in resting state, both CSFpulse and CSFedge indices were correlated with global BOLD, exhibiting a stronger correlation for CSFedge and varying peak correlations at -1s, -10s, and +11s. The temporal correlation between CSF dynamics and global BOLD indicates differences in CSF physiology in humans compared to smaller animals.

Impact: The study results imply differing correlation coefficients between CSF dynamics and the BOLD signal, suggesting promising pathways for deeper investigations into brain CSF dynamics in small animal models and neuroscientific advancements using EPI-based fMRI database.



Correlation analysis of the behavioral analysis and quantitative T2 map data in the SOD1G93A mouse model

Momoka Kuramochi^{1,2}, Yuji Komaki², Hiroyuki Kameda³, Kosuke Kudo³, and Junichi Hata¹

¹Tokyo Metropolitan University, Tokyo, Japan, ²Central Institute for Experimental Animals, Kawasaki, Japan, ³Hokkaido University, Sapporo, Japan

Keywords: Preclinical Image Analysis, Preclinical, Amyotrophic lateral sclerosis (ALS)


Motivation: Amyotrophic lateral sclerosis is still an understudied disease, and early detection is important.

Goal(s): This study aimed to clarify the transition of the pathophysiology and evaluate the relationship between the abnormalities detected on magnetic resonance imaging and the development of clinical symptoms by combining the T₂ map data obtained in the previous study with behavioral analysis.

Approach: Behavioral analysis was performed on four parameters, namely, bodyweight, general condition, hind-foot reflex test, and landing foot-splay test. Correlation analysis of the behavioral analysis data and T₂ map data was performed in each voxel.

Results: A correlation was detected in the trigeminal motor nucleus.

Impact: Changes in the trigeminal motor nucleus are indicated to be closely related to early changes in amyotrophic lateral sclerosis (ALS). This finding is suggested to be useful for the early diagnosis of ALS in humans and research on novel treatments.



T2*-mapping of the mouse brain at 7T with a 3D Multi Gradient Echo Sequence.

Nicolas SIMONNEAU¹, Aurélien TROTIER¹, Elise COSENZA², Laurent PETIT², Emeline J RIBOT¹, and Sylvain MIRAUX¹

¹CRMSB, CNRS, Bordeaux, France, ²GIN-IMN, CNRS, Bordeaux, France

Keywords: Small Animals, Relaxometry

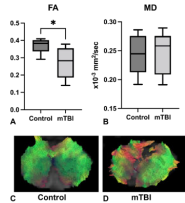
Motivation: Measuring T2* in mouse brains may therefore be of interest in assessing pathological models or innovative treatments directed against these pathologies.

Goal(s): The goal of this study was to obtain a high resolution and accurate T2* map of the mouse brain *ex vivo* and *in vivo*.

Approach: A 3D Multi Gradient Echo sequence with a drift compensation module was used and combined with an optimized fitting model which takes account the non-central chi distribution of the multi-channel gaussian noise.

Results: T2* map were obtained *ex vivo* and *in vivo* at 117 μm isotropic resolution in 20 minutes.

Impact: A high-resolution 3D Multi-Gradient Echo sequence sequence has been coupled with an optimized fitting algorithm to generate high resolution T2* map of the mouse brain. This method can be used to study preclinical stroke model.



DTI/DKI Biomarkers of Chronic mild Traumatic Brain Injury

Donghoon Lee¹ and James Meabon^{1,2}

¹University of Washington, Seattle, WA, United States, ²VA Puget Sound Health Care System, Seattle, WA, United States

Keywords: Biomarkers, Traumatic brain injury

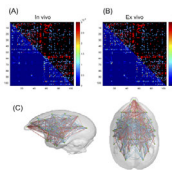
Motivation: Imaging biomarkers accurately diagnosing and monitoring treatment response for chronic mild Traumatic Brain Injury (mTBI) are needed.

Goal(s): This study aimed to experimentally validate and determine the performance of MRI biomarkers for monitoring chronic repetitive mild traumatic brain injury (mTBI).

Approach: We used diffusion tensor imaging (DTI) and diffusion kurtosis imaging (DKI) to assess white matter injury in mouse brains with chronic mTBI and compared results with those for age-matched control brains.

Results: Reduction in fractional anisotropy and increase of axial kurtosis were observed in the medulla of mTBI brains compared to the parameters in the same region of control brains.

Impact: It is new to monitor DTI and DKI parameters as noninvasive biomarkers in the brain with chronic mTBI.



Water diffusion is influenced by the changes in regional volume

Daisuke Yoshimaru^{1,2,3,4}, Tomokazu Tsurugizawa^{3,5}, Naoya Hayashi^{6,7}, Junichi Hata^{1,2,6}, Shuhei Shibukawa^{8,9}, Kazuhiro Saito⁴, Hideyuki Okano^{2,10}, and Hiroataka James Okano^{1,2}

¹Division of Regenerative Medicine, Jikei University School of Medicine, Tokyo, Japan, ²RIKEN Center for Brain Science, Saitama, Japan, ³National Institute of Advanced Industrial Science and Technology (AIST), Ibaraki, Japan, ⁴Department of Radiology, Tokyo Medical University, Tokyo, Japan, ⁵University of Tsukuba, Ibaraki, Japan, ⁶Tokyo Metropolitan University, Tokyo, Japan, ⁷Tokyo Medical University Hospital, Tokyo, Japan, ⁸Faculty of Health Science, Department of Radiological Technology, Juntendo University, Tokyo, Japan, ⁹Tokyo Medical University, Tokyo, Japan, ¹⁰Keio University School of Medicine, Tokyo, Japan

Keywords: Preclinical Image Analysis, Brain Connectivity, axial diffusivity, marmosets, brain volume

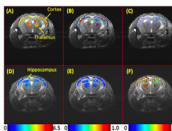
Motivation: A direct examining the volume and diffusion indices of in vivo and ex vivo brains from the same individual is of great interest in linking clinical and histological studies.

Goal(s): The goal of this study is to investigate the relationship between brain volume and diffusion indices in brain using in vivo and ex vivo brains from the same individual.

Approach: Dwi indices and brain volumes of the whole brain, white matter, cerebral cortex, cerebellum, and 52 brain regions were compared in vivo and ex vivo from same individuals.

Results: For each DWI index, AD was correlated with volume change in 40 cortical regions.

Impact: This study successfully compared the same brain in vivo and ex vivo directly, and it sufficiently demonstrates the relationship between volume and diffusion indices. In particular, AD is most sensitive to regional volume changes.



CEST MRI detects antiretroviral therapy-induced metabolomic alterations in brains of a rodent model

YUTONG LIU¹, Gabriel C. Gauthier¹, Micah A. Summerlin², and Aditya N. Bade²

¹Radiology, University of Nebraska Medical Center, Omaha, NE, United States, ²Pharmacology and Experimental Neuroscience, University of Nebraska Medical Center, Omaha, NE, United States

Keywords: Small Animals, CEST & MT, Drugs, metabolites, antiretroviral, HIV, ART, glutamate, creatine

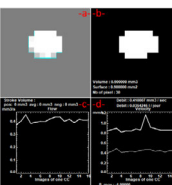
Motivation: The neurotoxicity of antiretroviral (ARV) drugs has been reported to affect neurocognition.

Goal(s): In this study, we tried to link CEST results of ARVs and metabolites to elucidate the effects of ARVs on metabolic alterations.

Approach: Mice administrated with TDF/3TC/DTG were scanned using CEST MRI to detect 3TC (at 1 and 2 ppm) and TDF (at 3 ppm). Metabolites were also measured using CEST MRI.

Results: Results showed that when used in combination, MRI is not sensitive to the CEST contrasts of 3TC and TDF. Glutamate, creatine and NOE were affected by TLD indicating the toxicity of TLD.

Impact: The study showed the potential to use CEST MRI to elucidate the effects of antiretroviral drugs on the neuropathologic outcomes by testing the association of MRI measurements of ARVs and metabolic imaging results.



reproducibility and accuracy of PC-MRI for low velocity measurement: A pilot study.

KAMEL ABDERRAHIM^{1,2}, Olivier Baledent^{1,3}, and sidy fall³

¹Facing Faces Institute/CHIMERE EA 7516, University of Picardy, AMIENS, France, ²Bruker Biospin MRI GmbH, Wissembourg, France, ³University Centre for Health Research (CURS, PIRMPA), University of Picardy Jules Verne, Amiens, France

Keywords: Preclinical Image Analysis, Data Acquisition, Flow measurement

Motivation: Non-invasive measurement of intracranial flow can elucidate fluid interactions within the brain. However, it's essential to determine the range of velocities that can be reliably measured using this approach.

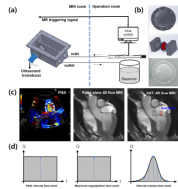
Goal(s): Our aim is to assess the ability of PC MRI "Flow Compensated Fast low angle Shot (fcFLASH)" based sequence for velocity measurements in small blood vessels and cerebrospinal fluid in rats.

Approach: A phantom is built to simulate fluid flow. Measurements are repeated for each velocity range.

Results: Non gated fcFLASH-based PC MRI allows a rough estimation of flow velocities on the order of 0.5 cm/s.

Impact: our study shows that the fcFLASH-based PC MRI can be used for a rough estimation of a small fluid circulation. A methodological development is necessary for a reliable measurement.

4910



The effect of valve annulus tracking on mitral valve regurgitation: A comparative in vitro study between ultrasound and 4D flow MRI

Minseong Kwon¹, Juyeon Lee², Sungho Park^{3,4}, and Hyungkyu Huh¹

¹Medical Device Development Center, Daegu-Gyeongbuk Medical Innovation Foundation, Daegu, Korea, Republic of, ²Ulsan university, Ulsan, Korea, Republic of, ³Department of Radiology, Children's Hospital Colorado, University-Campus, Aurora, CO, United States, ⁴Institute of Medical Devices, Kangwon National University, Chuncheon, Korea, Republic of

Keywords: Flow, Cardiovascular

Motivation: Mitral valve regurgitation (MVR) is the most common heart valve diseases, but accurate quantification of MVR has been limited due to the dynamic motion of valves.

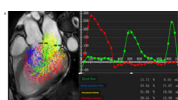
Goal(s): We hypothesize that volumetric flow information by 4D flow MRI with the compensation of MV motion could address this challenge.

Approach: MVR was measured using a simulated-in vitro model by comparing with actual flow from pump, ultrasound, and 4D flow MRI with/without a mitral registration algorithm.

Results: PISA method overestimated MVR. 4D flow MRI without algorithm seems to have similar the amount of actual MVR, while it decreased with employing algorithm.

Impact: Accurate quantification of regurgitation plays an important role for diagnosing patients with valvular diseases. This study would have a chance to measure accurate MVR quantification and quantify complex intracardiac blood flow using 4D flow MRI.

4911



4D flow CMR-derived left ventricular hemodynamic indicators for evaluating heart failure with reduced ejection fraction patients

Rui Wang¹, Xinyan Tao¹, Jianxiu Lian², and Lei Xu¹

¹Department of Radiology, Beijing Anzhen Hospital, Capital Medical University, Beijing, China, ²Philips Healthcare, Beijing, China

Keywords: Heart Failure, Cardiovascular

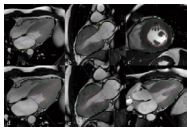
Motivation: Heart failure is a clinical syndrome in which the heart is unable to pump blood efficiently, and Heart Failure with Reduced Ejection Fraction (HFrEF) with the left ventricular ejection fraction (LVEF) < 40% serve as high morbidity and mortality.

Goal(s): The aim of this study is to investigate the hemodynamic environment in left ventricle of different phases.

Approach: 4D flow technology could offer non-invasive method for quantifying the alternatives of intracardiac blood flow components in HFrEF with and without MACE.

Results: Results showed reduced DF-KEiESV, DEF-KEiESV, higher RVo and peak E-wave RVo-KEiEDV were confirmed in MACE+ group when compared with MACE- group.

Impact: The hemodynamic analysis in HFrEF when compared patients with and without MACE illustrated significant alternative of intracardiac blood flow components by using 4D flow technology, which could offer valuable insight for further assessment and treatment planning.



Predictive value of left atrial and left ventricular strain for sudden cardiac death risk in hypertrophic cardiomyopathy by feature-tracking CMR

Xinyu Zhu¹, Pengfei Liu¹, Ying Shi¹, Jianxiu Lian², Lulu Li¹, Honghu Shen¹, and Haishan Wu¹

¹the First Affiliated Hospital of Harbin Medical University, Harbin, China, ²Philips Healthcare, Beijing, China

Keywords: Myocardium, Cardiomyopathy


Motivation: The risk stratification for implantable cardioverter-defibrillators (ICD) placement in high-risk patients with hypertrophic cardiomyopathy (HCM) has challenges.

Goal(s): The aim of this study is to investigate the connection between left atrial and left ventricular strain and sudden cardiac death (SCD) risk stratification by feature-tracking CMR.

Approach: All patients were satisfied by the 2020 AHA/ACC HCM Risk-SCD model with feature-tracking CMR for assessing left atrial and left ventricular strain.

Results: Results demonstrated that both left atrial and left ventricular strain show obvious attenuation in high-risk group than low-risk group. LVGRS+LARS combined model exhibited a superior diagnostic value for identifying high-risk SCD.

Impact: The LVGRS+LARS combined model could provide additional predictive value for improving SCD risk stratification in clinical practice, which may provide vital insights into the judicious clinical utilization of ICD to reduce SCD in HCM.



Prognostic Value of Right Ventricular 3D Trabecular Complexity in Arrhythmogenic right ventricular cardiomyopathy

Jin-Yu Zheng¹, Bing-Hua chen¹, Chong-Wen Wu¹, Rui Wu¹, Dong-Aolei An¹, Ruo-Yang Shi¹, Jingyu Xie², Shan-shan Jiang³, Lian-Ming Wu¹, and Lei Zhao⁴

¹Renji Hospital, School of Medicine, Shanghai Jiao Tong University, Shanghai, China, ²Philips Healthcare, shanghai, China, ³Philips Healthcare, Xi'an, Shaanxi, China, ⁴Beijing Anzhen Hospital, Capital Medical University, Beijing, China

Keywords: Myocardium, Cardiovascular

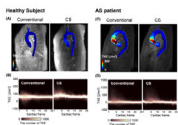
Motivation: Arrhythmogenic right ventricular cardiomyopathy (ARVC) is characterized by progressive myocardial fibro-fatty infiltration accompanied by trabecular disarray. The prognostic value of trabecular disorder assessed by three-dimensional (3D) fractal dimension (FD) measurement is unclear.

Goal(s): To investigate the prognostic value of 3D right ventricular trabecular complexity of ARVC.

Approach: Using cine images, trabecular complexity was measured with 3D fractal analysis to calculate 3D-FD in ARVC patients retrospectively. Cox regression analyses and Kaplan-Meier survival analysis were performed to identify the prognostic value of 3D-FD.

Results: RV 3D-FD was a significant risk predictor for MACE in ARVC and provided incremental prognostic value to conventional predictors.

Impact: Based on the results, we suggested 3D RV trabecular complexity, derived from non-invasive imaging examination, as a new biomarker for early clinical therapy in medication and ICD implantation in order to moderate the onset of adverse endpoints in ARVC patients.



Good agreement of turbulent kinetic energy assessment by compressed sensing-accelerated 4D flow MRI in aortic stenosis patients

Sungho Park^{1,2,3}, Ning Jin⁴, Dongyeop Han⁵, Bae Young Lee⁶, Minseong Kwon³, Jeong-Eun Yi⁷, and Hyungkyu Huh³

¹Department of Radiology, Children's Hospital Colorado, University of Colorado Anschutz Medical Campus, Aurora, CO, United States, ²Institute of Medical Devices, Kangwon National University, Chuncheon, Korea, Republic of, ³Medical Device Development Center, Daegu-Gyeongbuk Medical Innovation Foundation, Daegu, Korea, Republic of, ⁴Cardiovascular MR R&D, Siemens Medical Solutions, Cleveland, OH, United States, ⁵Siemens Healthineers Ltd., Seoul, Korea, Republic of, ⁶Department of Radiology, Eunpyeong St. Mary's Hospital, College of Medicine, The Catholic University of Korea, Seoul, Korea, Republic of, ⁷Division of Cardiology, Department of Internal Medicine, Eunpyeong St. Mary's Hospital, College of Medicine, The Catholic University of Korea, Seoul, Korea, Republic of

Keywords: Flow, Data Analysis, 4D flow MRI, Compressed sensing

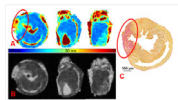
Motivation: Compressed sensing (CS) acceleration has improved the clinical applicability of 4D flow MRI. However, but no studies have investigated turbulent kinetic energy (TKE) assessment using CS-accelerated 4D flow MRI.

Goal(s): This study aims to validate TKE assessment in CS 4D flow MRI compared to conventional 4D flow MRI.

Approach: The effect of CS acceleration on TKE assessment was evaluated by in vitro coarctation model. In addition, TKE assessment was further validated in healthy subjects and aortic stenosis (AS) patients.

Results: TKE parameters had good agreement in AS patients at the ascending aorta, while healthy subjects had significant differences.

Impact: TKE estimation has been limited due to asymmetric velocity encoding scheme, requiring additional MR scans. This study firstly validates the reliability of TKE using CS 4D flow with reduced scan time in AS patients.



Adiabatic T1rho-mapping of subacute myocardial ischemia with ultra-short echo time 3-D imaging in ex vivo mice

Iida Rätty¹, Antti Paajanen², Mikko Nissi², Sanna Kettunen¹, Anna-Kaisa Ruotsalainen¹, Svetlana Laidinen¹, Seppo Ylä-Herttua¹, and Elias Ylä-Herttua¹

¹A.I. Virtanen Institute for Molecular Sciences, University of Eastern Finland, Kuopio, Finland, ²Department of Technical Physics, University of Eastern Finland, Kuopio, Finland

Keywords: Myocardium, Quantitative Imaging, Ex vivo applications, High field MRI, Small animals, Ischemia, Preclinical imaging

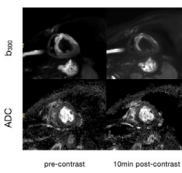
Motivation: Conventional CMR techniques have many limitations, such as slowness and inability to provide contrast-agent free 3-D assessments of myocardium in the cardiac diseases.

Goal(s): The aim of this study is to develop a faster, high-resolution 3-D CMR imaging method for quantitative imaging of the myocardium after myocardial infarction (MI).

Approach: Mice hearts were imaged ex vivo 7 days after the factitious MI by using an ultra-short echo time 3-D $T_{1\rho}$ technique (MB-SWIFT-CS).

Results: The $T_{1\rho}$ relaxation times were elevated in the infarct area. The findings were validated by 2-D CMR maps and histopathology to confirm ischemia, edema, and fibrosis in the myocardium.

Impact: This study presents a quantitative ultra short echo time 3-D CMR method for ex vivo assessment of myocardium after factitious myocardial infarction in mice. The method allowed rapid comprehensive 3-D myocardial evaluation by utilizing compressed sensing and relaxation time mapping.



Diffusion-weighted imaging of reperfused acute myocardial infarction: effect of intravenous gadolinium-based contrast agent administration

Shuguang Han¹, Dan Wang¹, Jiali Wang¹, Lu Han², Peng Wu², Yongjun Cheng², Chunfeng Hu¹, and Kai Xu¹

¹Department of Radiology, The Affiliated Hospital of Xuzhou Medical University, XUZHOU, China, ²Philips Healthcare, Shanghai, China, Shanghai, China

Keywords: Myocardium, Diffusion/other diffusion imaging techniques, acute myocardial infarction, reperfusion injury

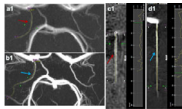
Motivation: Cardiac diffusion-weighted(DW)imaging has proven to be an effective approach to explore ischemia reperfusion myocardium damage and inflammation induced by treatment after reperfusion.

Goal(s): The objective of this study was to investigate whether contrast agent (CA) administration significantly affects DWI in the evaluation of reperfused acute myocardial infarction.

Approach: The apparent diffusion coefficient (ADC) values,signal intensity(SI) and contrast-to-noise ratio(CNR) pre- and post-contrast were measured in the intramyocardial hemorrhage (IMH),edema area and remote regions, respectively.

Results: The ADC values in IMH and edema area were not significantly changed between pre- and post-contrast ($P>0.05$), while the SI of remote myocardium was inhibited and CNRs were reduced.

Impact: To better assess ischemia reperfusion myocardium damage, DWI is recommended to perform as much as possible before the gadolinium-based contrast agent administration.



The clinical application of 5.0 T 3D TOF MRA in the imaging of AChA and related cerebrovascular diseases

Zhangzhu Li¹, Mingyan Shang², Min Fu³, Zhensong Wang³, Jianxian Liu³, Liang Yin³, Dan Yu⁴, and Jie Gan²

¹Shandong Provincial Third Hospital, Cheeloo College of Medicine, Shandong University, JINAN, China, ²Department of Radiology, Shandong Provincial Third Hospital, Cheeloo College of Medicine, Shandong University, Jinan, China, ³Department of Radiology, Shandong Provincial Third Hospital, Cheeloo College of Medicine, Shandong University, JINAN, China, ⁴United Imaging Research Institute of Intelligent Imaging, Beijing, People's Republic of China, Beijing, China

Keywords: Vascular, Brain, magnetic resonance imaging; TOF MRA; Anterior choroidal artery AChA; 5.0 T

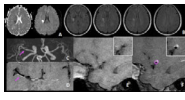
Motivation: Improved cerebrovascular disease diagnosis requires enhanced imaging of the anterior choroidal artery (AChA).

Goal(s): To evaluate the effectiveness of a 5.0T ultra-high-field MR scanner for cerebrovascular imaging compared to traditional 3.0T scanners.

Approach: Retrospective analysis using 5.0T MR imaging to assess AChA visualization in patients with cerebrovascular complaints.

Results: The 5.0T scanner significantly outperformed the 3.0T in image quality and detail, providing superior AChA delineation, which is essential for diagnosing related cerebrovascular diseases.

Impact: The 5.0T MR imaging's superior visualization of AChA paves the way for better diagnosis and management of deep brain vascular diseases, potentially influencing treatment outcomes and advancing neurovascular research.



Vulnerable plaques are associated with white matter hyperintensities: a finding on high-resolution vessel wall magnetic resonance imaging.

Jiayu Li¹, Ying Shi¹, Jianxiu Lian², and Pengfei Liu¹

¹First Affiliated Hospital of Harbin Medical University, Harbin, China, ²Philips Healthcare, Beijing, China

Keywords: Atherosclerosis, Atherosclerosis

Motivation: Cerebral small vessel disease (CSVD) is a common disease in the elderly with uncertain causes. We wanted to explore whether intracerebral macrovascular disease is related to CSVD.

Goal(s): This study was to explore the relationship between atherosclerotic plaque characteristics and wall changes and white matter hyperintensities (WMH) associated with CSVD.

Approach: As a non-invasive technique, high-resolution vessel wall magnetic resonance imaging can display vascular image and measure plaque parameters and vascular wall changes. Using the tools, the differences between WMH groups were analyzed.

Results: WMH was associated with unstable plaques. Age, wide distribution and significant enhancement were independent factors affecting WMH.


Impact: Unstable atherosclerotic plaque may cause CSVD, suggesting that clinicians should pay more attention to patients with ischemic stroke. The plaque vulnerability parameter may be a new index to evaluate the degree of WMH.

Neurofluid Imaging

Exhibition Hall (Hall 403)

Tuesday 13:30 - 14:30

4919



The relation between sleep indices and indices for brain interstitial fluid dynamics by MRI and the effects of orexin antagonists: a FLUID study.

Toshiaki Taoka^{1,2}, Kunihiro Iwamoto³, Seiko Miyata³, Ippei Okada³, Rintaro Ito^{1,2}, Rei Nakamichi², Toshiki Nakane², Kazushige Ichikawa⁴, Hirohito Kan⁵, Koji Kamagata⁶, Junko Kikuta⁶, Shigeki Aoki⁶, Akihiro Fujimoto⁷, Yuki Kogo⁷, Nobuyasu Ichinose^{1,8}, Shinji Naganawa², and Norio Ozaki⁹

¹Department of Innovative Biomedical Visualization (iBMV), Nagoya University, Nagoya, Japan, ²Department of Radiology, Nagoya University, Nagoya, Japan, ³Department of Psychiatry, Nagoya University, Nagoya, Japan, ⁴Department of Radiological Technology, Nagoya University, Nagoya, Japan, ⁵Department of Integrated Health Sciences, Nagoya University, Nagoya, Japan, ⁶Department of Radiology, Juntendo University of Medicine, Tokyo, Japan, ⁷Medical Headquarters, Eisai Co., Ltd., Tokyo, Japan, ⁸Department of CT-MR Solution Planning, Canon Medical Systems Corporation, Otawara, Japan, ⁹Pathophysiology of Mental Disorders Nagoya University Graduate School of Medicine, Nagoya University, Nagoya, Japan

Keywords: Neurofluids, Neurofluids


Motivation: The motivation is to investigate the relationship between sleep and interstitial fluid dynamics influenced by the administration of lemborexant, a dual orexin receptor antagonist.

Goal(s): The goal is to identify changes in indices of interstitial fluid dynamics related to sleep before and after the administration of lemborexant.

Approach: ALPS-index, Ktrans by DSC method, and choroid plexus volume were assessed as indicators of interstitial fluid dynamics.

Results: The sleep indexes on a night were found to correlate with the ALPS-index measured in the evening before that night's sleep. In multiple regression analysis, the ALPS-index was lower when sleep parameters were poor at baseline.

Impact: The sleep indexes on a night were found to correlate with the ALPS-index measured the evening before. The evaluation of the ALPS-index before and after lemborexant administration revealed that the baseline sleep status played a role in improving the index.



Altered blood pulsatility & small vessel disease marker associations in obstructive sleep apnoea post-continuous positive airway pressure

Michael S Stringer¹, Lizzie Hill², Alasdair Morgan¹, Dany Jaime Garcia¹, Lucia Ballerini³, Will Hewins⁴, Rosalind Brown¹, Roberto Duarte Coello¹, Bradley Macintosh^{5,6}, Jose Bernal⁷, Andrew Lim^{6,8}, Rosa Sommer^{6,8}, Maria Valdes Hernandez¹, Francesca Chappell¹, Sandra Black⁶, Ian Marshall¹, Fergus Doubal¹, Renata Riha⁹, Michael J Thrippleton¹, and Joanna M Wardlaw¹

¹Centre for Clinical Brain Sciences and UK Dementia Research Institute, University of Edinburgh, Edinburgh, United Kingdom, ²School of Applied Sciences, University of the West of England, Bristol, United Kingdom, ³University for Foreigners of Perugia, Perugia, Italy, ⁴School of Health in Social Science, University of Edinburgh, Edinburgh, United Kingdom, ⁵Department of Medical Biophysics, University of Toronto, Toronto, ON, Canada, ⁶Hurvitz Brain Sciences Program, Sunnybrook Research Institute, Toronto, ON, Canada, ⁷Institute of Cognitive Neurology and Dementia Research, Otto-Von-Guericke University and DZNE Magdeburg, Magdeburg, Germany, ⁸Institute of Medical Sciences, University of Toronto, Toronto, ON, Canada, ⁹Department of Sleep Medicine, Royal Infirmary of Edinburgh, NHS Lothian, Edinburgh, United Kingdom

Keywords: Neurofluids, Blood vessels, Phase contrast MRI


Motivation: Sleep affects vascular health and brain waste clearance. Sleep disorders, including obstructive sleep apnoea (OSA), are associated with higher small vessel disease (SVD) burden increasing stroke/dementia risk. OSA treatment relies on continuous positive airway pressure (CPAP).

Goal(s): We aimed to assess the effect of CPAP on MRI-based blood pulsatility index (PI) measures and associations with SVD burden.

Approach: We assessed arterial/venous PI using phase-contrast MRI in patients with moderate/severe OSA before and after 4 months CPAP.

Results: Arterial PI tended lower post-CPAP, consistent with better vascular health. Post-CPAP patients with higher venous PI had less severe basal ganglia perivascular space burden.

Impact: Few studies have investigated MRI-based blood pulsatility index (PI) in obstructive sleep apnoea (OSA). We found effective treatment may improve brain vascular health, altering blood PI. Higher venous PI post-treatment may link to brain waste clearance, but requires further study.



The role of glymphatic function and CSF circulation in patients with glioma

Xiaodan Liu¹, Angela Jakary¹, Oluwaseun Adegbite¹, Tracy Luks¹, Reza Eghbali¹, Villanueva-Meyer Javier¹, Susan Chang², Duan Xu¹, and Janine Lupo¹

¹Radiology and Biomedical imaging, University of California, San Francisco, San Francisco, CA, United States, ²neurological surgery, University of California, San Francisco, San Francisco, CA, United States

Keywords: Neurofluids, Tumor, CSF circulation, glymphatic system, Diffusion tensor imaging analysis along the perivascular space (ALPS)


Motivation: Limited research has been performed on the role of CSF circulation in the glymphatic transport in patients with glioma.

Goal(s): To evaluate the relationship between CSF circulation disturbance and glymphatic dysfunction in different glioma subtypes.

Approach: A novel measure of glymphatic function (ALPS index) was quantified and compared among 100 patients with different genetic subtypes and associated with CSF circulation related factors and tumor volume.

Results: We found that lower ALPS index in the tumor hemisphere was found in IDH-wildtype glioblastomas and with increasing grade in IDH-mutant gliomas. CSF circulation related factors were correlated with disruptions in glymphatic function.

Impact: Our promising results provide a novel insight of glymphatic dysfunction in patients with glioma.



Improvement of Glymphatic System Using Low-Intensity Focused Ultrasound (LIFU) for Lymphatic Enhancement

Hyochul Lee^{1,2}, Taekyu Jang^{1,2}, Ok kyu Park^{2,3}, Taewon Choi⁴, Seoyun Chang⁴, Jinhyoung Park⁴, and Seung Hong Choi^{1,2,3}

¹Interdisciplinary Program in Cancer, Seoul National University, Seoul, Korea, Republic of, ²Department of Radiology, Seoul National University Hospital, Seoul, Korea, Republic of, ³Center for Nanoparticle Research, Institute for Basic Science (IBS), Seoul, Korea, Republic of, ⁴Department of Biomedical Engineering, Sungkyunkwan University, Suwon, Gyeonggi-do, Korea, Republic of

Keywords: Neurofluids, Brain, Glymphatic system, Low-Intensity Focused Ultrasound, Lymphatic Enhancement, Contrast-enhanced MRI


Motivation: Enhanced lymphatic flow may improve the glymphatic system for metabolic waste clearance from the brain.

Goal(s): Our goal was to demonstrate that stimulating the lymphatics can enhance the glymphatic system.

Approach: We introduced low-intensity focused ultrasound (LIFU) to enhance the lymphatics and assessed the glymphatic system in rats by visualizing signal changes in contrast-enhanced MRI.

Results: The LIFU group exhibited a more rapid increase and decrease in signal intensity compared to the control group.

Impact: Lymphatic enhancement using LIFU could influence the improvement of the glymphatic system. This enhancement could positively affect cognitive function, with potential implications for preventing and treating neurodegenerative diseases.



How Breathing and Cardiac functions interact with Cerebral arterio-venous blood flows: Origin of CSF oscillations

Pan LIU¹, Kimi Owashi², Heimiri Monnier², Cyrille Capel³, Serge Metanbou⁴, and Olivier Balédent^{1,2}

¹Amiens Picardy University Hospital, CHIMERE UR.7516, Amiens, France, ²Jules Verne University of Picardy, CHIMERE UR 7516, Amiens, France, ³Amiens Picardy University Hospital, Neurosurgery Department, Amiens, France, ⁴Amiens Picardy University Hospital, Radiology Department, Amiens, France

Keywords: Neurofluids, Neurofluids, Real time, phase contrast, CSF, CBF

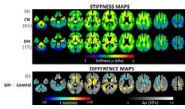
Motivation: The main drivers of CSF oscillations are currently controversial.

Goal(s): To investigate whether the breathing or cardiac regulated Cerebral blood flow are the major driver of CSF dynamics.

Approach: Investigate Cerebral blood and CSF flows through the intracranial compartment during free and deep breathing using real-time phase-contrast sequence. To quantify the neurofluids volume displacement along the cardiac cycle.

Results: Both cardiac and breathing cycles influenced neurofluids volume displacements. CSF dynamics is significantly correlated with intracranial blood volume change. CSF dynamic acts as a compensatory mechanism of intracranial blood volume dynamics.

Impact: This study confirms that intracranial blood volume change due to cardiac and breathing activities are the main drivers of CSF dynamic. This study provides valuable insights for understanding CSF circulation's complex mechanism and investigating idiopathic cerebral diseases.



MR Elastography as a Potential Imaging Biomarker and Non-Invasive Method for Diagnosing Spontaneous Intracranial Hypotension

Ian Mark¹, Pragalv Karki², Jeremy Cutsforth-Gregory², Waleed Brinjikji², Ajay Madhavan², Steven Messina², Petrice Cogswell², John Chen², Richard Ehman², John Huston², and Matthew Murphy²

¹Radiology, Mayo Clinic, Rochester, MN, United States, ²Mayo Clinic, Rochester, MN, United States

Keywords: Neurofluids, Elastography, SIH; CSF Leak


Motivation: Spontaneous intracranial hypotension (SIH) is a debilitating disease with a normal brain MRI in 20% of cases.

Goal(s): Our goal was to use MR elastography (MRE) to identify unique viscoelastic patterns in SIH patients.

Approach: We performed brain MRE in 15 SIH patients and compared their mechanical properties to 65 healthy controls.

Results: SIH patients exhibited significant differences in both stiffness and damping ratio compared to healthy controls.

Impact: We demonstrate MRE as a potential imaging biomarker and a non-invasive method for diagnosing SIH, including patients with a normal brain MRI.



Interaction of neurofluids flow dynamics studied by PC-MRI

Kimi Piedad Owashi^{1,2}, Pan Liu^{1,2}, Serge Metanbou³, Cyrille Capel^{2,4}, and Olivier Balédent^{1,2}

¹Medical Image Processing, University Hospital, Amiens, France, ²CHIMERE UR 7516, Jules Verne University of Picardy, Amiens, France, ³Radiology, University Hospital, Amiens, France, ⁴Neurosurgery, University Hospital, Amiens, France

Keywords: Neurofluids, Neurofluids

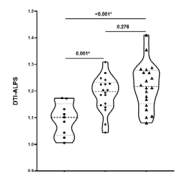
Motivation: Cervical-level is often chosen to estimate Cerebral Blood-Volume Change (CB-VC) during cardiac cycle. Due to the heterogeneity in extracranial cerebral veins anatomy and their high compliance, we hypothesize that the intracranial level could be a better choice to investigate blood and CSF interactions.

Goal(s): To determine the best level for studying the interaction of neurofluids flow dynamics.

Approach: Using PC-MRI, CB-VC and CSF-Volume Change (CSF-VC) were calculated in 36 volunteers at intracranial and extracranial levels, and their interactions were compared by linear regressions.

Results: The interaction between CSF-VC and CB-VC dynamics at intracranial level ($R^2:0.82\pm0.16$) was higher ($p<0.001$) than at extracranial level ($R^2:0.46\pm0.36$).

Impact: This study highlights the greater consistency of spinal CSF-VC response to vascular volume dynamics measured intracranially rather than at the cervical level. These findings are valuable to consider for studying cranio-spinal neurofluids flow dynamics interactions, pressure and compliance.



Exploring the development of glymphatic system function in very preterm infants through the diffusion along perivascular space index

Congcong Liu^{1,2}, Chunxu Da^{1,2}, Xinyi Huang^{1,2}, Tianjiao Chen^{1,2}, Miaomiao Wang^{1,2}, Xianjun Li^{1,2}, and Jian Yang^{1,2}

¹Department of Radiology, The First Affiliated Hospital of Xi'an Jiaotong University, Xi'an, China, ²Shaanxi Engineering Research Center of Computational Imaging and Medical Intelligence, Xi'an, China

Keywords: Normal Development, Neonatal

Motivation: Despite white matter perivascular spaces visual grades in preterm was not different from term infants, whether the glymphatic system function differently with preterm and term infants remains unclear.

Goal(s): Exploring development of glymphatic system function in very preterm (VP) infants, comparing with term infants.

Approach: The diffusion along perivascular space index (ALPS) was used to evaluate the glymphatic system function via diffusion tensor images (DTI).

Results: The DTI-ALPS index was significantly lower in VP neonates than VP infants at term equivalent age (TEA) or term neonates. However, the DTI-ALPS index in VP infants at TEA was not found differences with term neonates.

Impact: The glymphatic system function was developing with gestational age, while very preterm infants presented "catch-up" growth pattern up to TEA.

¹Key Laboratory of Endocrine Glucose & Lipids Metabolism and Brain Aging, Ministry of Education; Department of Radiology, Shandong Provincial Hospital Affiliated to Shandong First Medical University, Jinan, China, ²Department of Psychiatry and Psychotherapy, Jena University Hospital, Jena, Germany; Center for Intervention and Research on adaptive and maladaptive brain Circuits underlying mental health (C-I-R-C), Jena-Magdeburg-Halle, Germany, Jena, Germany, ³Department of Radiology, Beijing Tsinghua Changgung Hospital, Beijing, China

Keywords: DWI/DTI/DKI, Diffusion Tensor Imaging, Diffusion Tensor Imaging along the Perivascular Space

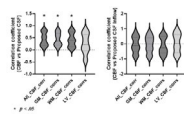
Motivation: Cognitive decline is associated with the impairment of glymphatic clearance, which can be investigated noninvasively using diffusion tensor imaging along the perivascular space (DTI-ALPS).

Goal(s): To investigate the linkage of cerebral small vessel disease (CSVD) burdens with left/right glymphatic function based on DTI-ALPS.

Approach: Glymphatic system function was assessed using diffusion tensor imaging along the perivascular space.

Results: The DTI-ALPS indexes in the CSVD groups were lower than the HC group. Hazard factors for right DTI-ALPS included CSVD severity and sex. Although the right DTI-ALPS index was associated with cognition in univariate analysis, it was not significant in regression analysis.

Impact: The DTI-ALPS technique provides a new opportunity for exploring the damage of CSVD burdens.


Comparing cerebral blood flow and cerebrospinal fluid flow during breath-holding and motor tasks in the human brain.
JaeGeun Im¹, JunHee Kim¹, and SungHong Park¹

¹KAIST, Daejeon, Korea, Republic of

Keywords: Neurofluids, Neurofluids

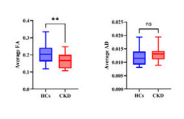
Motivation: Recent studies highlight the significant impact of arterial pulsation on CSF movements in animal studies, but direct comparison in awake humans is still limited.

Goal(s): This study aims to concurrently measure CSF and CBF, excluding the influence of breathing, to analyze their correlation. Additionally, it investigates changes in CSF movement during the motor task.

Approach: Simultaneously measuring CBF and CSF by applying pCASL, and comparing how they change during breath-holding and motor tasks.

Results: During breath-holding, we observed a positive correlation between CBF and CSF. Furthermore, we confirmed reduced CSF inflow during the motor task compared to the resting state.

Impact: The relationship between CSF movement and CBF was analyzed during breath-holding and motor tasks in humans for the first time. This study offers a new way to study CBF and CSF movement, providing a better understanding of CBF-CSF physiology.


Glymphatic dysfunction in patients with Chronic kidney disease is associated with cognitive decline
Lijun Song¹, Wenbo Yang¹, Mingan Li¹, Boyan Xu², Zhenghan Yang¹, Hao Wang¹, and Zhen-chang Wang¹

¹Department of Radiology, Beijing Friendship Hospital, Capital Medical University, Beijing, China, ²GE HealthCare, MR Research, Beijing, China, Beijing, China

Keywords: fMRI Analysis, Kidney, glymphatic system

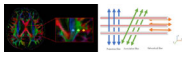
Motivation: The relationship between CSF inflow, which is an essential physiological activity of the glymphatic system, and cognitive decline in patients with chronic kidney disease (CKD) is unclear.

Goal(s): Our goal was to explore the patterns of CSF inflow changes in patients with CKD and its relationship with cognitive decline.

Approach: The CSF in the the subarachnoid space along the middle cerebral were analyzed with ultra-long echo time and low-b diffusion tensor imaging.

Results: Disturbed CSF inflow patterns is associated with cognitive decline in patients with CKD.

Impact: A novel approach to measure the CSF inflow of the glymphatic system exhibits the potential for detecting brain glymphatic dysfunction in patients with CKD, which may be one of the pathogenic mechanisms of cognitive decline.



Glymphatic function as a predictor of mild cognitive impairment to dementia conversion in Parkinson's disease

Huize Pang¹, Juzhou Wang¹, Yueluan Jiang², and Guoguang Fan¹

¹the first hospital of China Medical University, Shenyang, China, ²MR Research Collaboration, Siemens Healthineers, Beijing China, Beijing, China

Keywords: Diffusion Analysis & Visualization, Diffusion Tensor Imaging, DTI-ALPS

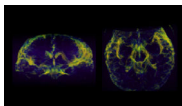
Motivation: Impaired glymphatic function is reported to be associated with cognitive function in Parkinson's disease (PD). However, an evaluation of the role of the glymphatic dysfunction contributing to the dementia conversion of mild cognitive impairment (MCI) with use of MRI remains lacking.

Goal(s): To evaluate the value of glymphatic function to predict the dementia conversion in PD with MCI.

Approach: We calculated the water diffusion in the periventricular white matter using DTI-ALPS to evaluate the glymphatic function in PD with cognitive impairment during the follow-up.

Results: The left DTI-ALPS is significantly lower in dementia converters, and is valuable for prediction of PD dementia conversion.

Impact: The reduction of glymphatic activity, assessed by DTI-ALPS, was more severe in PD with MCI convert to dementia. Therefore, DTI-ALPS may assist in identifying PD with MCI at a high risk of dementia conversion before the onset of dementia symptoms.



Diffusion-weighted imaging-based fluidography for assessing cerebrospinal fluid dynamics in the brains

Shunrou Fujiwara¹, Kuniaki Ogasawara¹, Kohei Chida¹, Yosuke Akamatsu¹, Takahiro Koji¹, Kenya Miyoshi¹, Kohki Oikawa¹, Jun Yoshida¹, Yoshitaka Kubo¹, and Yoshichika Yoshioka¹

¹Iwate Medical University, Yahaba, Japan

Keywords: Neurofluids, Brain

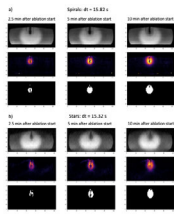
Motivation: Few study has developed the 3-D image like DTI-tractography to show tendency of CSF dynamic through the whole brain.

Goal(s): To develop DWI-fluidography for demonstrating tendency of CSF dynamic through the whole brain.

Approach: DWI with multiple b values and MPGs was scanned, and calculated a statistical variation of DWI signals obtained by different MPGs at each b value. The normalized value of the summation of all variations was defined as a value in a voxel for DWI-fluidography.

Results: The 3-D DWI-fluidography clearly showed differences of CSF dynamics at anatomical spaces filled with CSF, and the fluidography could reflect quantitative results with ADCs.

Impact: The DWI-fluidography has the potential to help us to diagnose/find/investigate CSF-related diseases in the brain. Then, it may open the door to new research area.



3D MR Thermometry Sequences for Abdominal Microwave Ablation Monitoring on Phantom Simulating Breathing Motion

Dominik Horstmann^{1,2}, Bennet Hensen^{1,2}, Othmar Belker^{1,2}, Thomas Gerlach^{2,3}, Moritz Gutt^{1,2}, Simon Schröer^{1,2}, Ivan Vogt^{2,3}, Frank Wacker^{1,2}, and Marcel Gutberlet^{1,2}

¹Diagnostic and Interventional Radiology, Hannover Medical School, Hannover, Germany, ²Research Campus STIMULATE, Magdeburg, Germany, ³Faculty of Electrical Engineering and Information Technology, Otto-von-Guericke University, Magdeburg, Germany

Keywords: MR-Guided Interventions, Thermometry

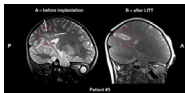
Motivation: 3D MR-thermometry enhances microwave ablation success by providing real-time temperature and ablation insights. However, clinical availability is limited due to challenges such as breathing motion and electromagnetic interferences.

Goal(s): Our study conducts 3D MR-thermometry comparing stack-of-stars and a stack-of-spirals sequences using a clinically approved generator and phantoms simulating breathing motion.

Approach: Temperature precision and precision of ablation zones of both sequences were compared.

Results: Stack-of-spirals sequence seems to be the superior MR-thermometry sequence. Dice scores of around 90 % and temperature precisions around 1°C were reached with very little image degradation due to motion or electromagnetic interferences.

Impact: Our study shows the possibility of motion robust 3D MR-thermometry using a clinically approved microwave generator. Future developments might provide real-time 3D MR thermometry during clinical abdominal thermal therapies, enhancing their success and increasing the total number of MR interventions.



Intraoperative 3T MRI as navigator for laser interstitial thermal therapy in paediatric epilepsy and tumour surgery.

Gilbert Hangel^{1,2}, Matthias Tomschik², Johannes Herta², Jonathan Wais², Fabian Winter², Gregor Kasprian³, Martha Feucht⁴, Christian Dorfer², and Karl Rössler²

¹High-field MR Center, Department of Biomedical Imaging and Image-guided Therapy, Medical University of Vienna, Vienna, Austria, ²Department of Neurosurgery, Medical University of Vienna, Vienna, Austria, ³Division of Neuroradiology and Musculoskeletal Radiology, Department of Biomedical Imaging and Image-guided Therapy, Medical University of Vienna, Vienna, Austria, ⁴Center for Rare and Complex Childhood Onset Epilepsies, Member of ERN EpiCARE, Department of Pediatrics and Adolescent Medicine, Medical University of Vienna, Vienna, Austria

Keywords: Thermometry/Thermotherapy, Interventional Devices, MR-guided LITT

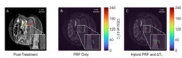
Motivation: MR-guided laser interstitial thermal therapy (LITT) uses laser fibres to ablate lesions under MR-thermometry monitoring. Distance between OR and MRI complicates this procedure, but previous generations of intraoperative MRIs were limited to fields up to 1.5T.

Goal(s): We investigated a dual-room setup for intraoperative 3T MRI as navigation/monitoring for LITT.

Approach: In eleven paediatric patients, we demonstrated this setup as navigation/monitoring for LITT.

Results: We quantified achievable time and precision parameters, e.g., a mean total surgery time of 4.9 hours.

Impact: Minimised surgery time and complications as well as improved treatment monitoring for laser interstitial thermal therapy make dual-room intraoperative 3T MRIs beneficial for paediatric patients.



In Vivo 3D Hybrid fat-water MR Thermometry via Simultaneous Proton Resonance Frequency Shift and T1 Measurement

Nicholas Richards¹, Michael Malmberg¹, Samuel I. Adams-Tew¹, Henrik Odéen¹, Dennis Parker¹, and Allison Payne¹

¹University of Utah, Salt Lake City, UT, United States

Keywords: Thermometry/Thermotherapy, Thermometry

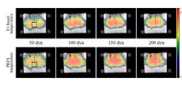
Motivation: In current clinical magnetic resonance-guided focused ultrasound (MRgFUS) ablation applications, only aqueous tissues are monitored with MR thermometry. Accurate thermometry of heterogeneous aqueous and fat tissue volumes would increase treatment safety and efficacy.

Goal(s): Evaluate a single reference variable flip angle (SR-VFA) sequence for hybrid proton resonance frequency shift and ΔT_1 MR thermometry in heterogeneous tissue volumes.

Approach: MRgFUS ablation in an in vivo rabbit model was monitored with SR-VFA thermometry. Cumulative thermal dose (CTD) maps calculated from SR-VFA images were compared with non-perfused volumes and histological samples.

Results: SR-VFA derived CTD maps accurately predicted volumes of thermal damage in muscle and fat.

Impact: Hybrid proton resonance frequency shift and T_1 thermometry allows for accurate temperature monitoring of heterogeneous tissue volumes. This increases the safety and efficacy of MR-guided focused ultrasound treatments in mixed-tissue treatment areas by ensuring target temperatures reach appropriate thresholds.



Simultaneous Acquisition of Temperature Mapping for Fatty and Nonfatty Biological Tissues based on Look-Locker Technique with dual echoes

Sangwoo Kim¹, Jinwoo Hwang^{2,3}, Chulhyun Lee⁴, and Sukhoon Oh⁴

¹Daewon University College, Jecheon, Korea, Republic of, ²Biomedical Engineering, Seoul, Korea, Republic of, ³Philips Korea, Seoul, Korea, Republic of, ⁴Korea Basic Science Institute, Cheongju, Korea, Republic of

Keywords: Thermometry/Thermotherapy, Thermometry


Motivation: Temperature errors in PRFS occur primarily in tissues containing adipose substances because fat changes its magnetic susceptibility with temperature.

Goal(s): This study aimed to simultaneously monitor the temperatures of fat and non-fat tissues using Look-Locker (LL) technique with dual echoes.

Approach: Two-point Dixon technique can be utilized to estimate the adipose components, which may aid in the separation of adipose tissue in PRFS. In addition, the method allows for a more refined B_0 correction.

Results: Compared to the temperature measured by the fiber-optic sensor, the PRFS and T_1 -based temperatures showed a small difference of about 0.11 ~ 0.22 °C and 0.06 ~ 0.15 °C, respectively.

Impact: This study yields an evidence that Look-Locker technique with dual echoes is suitable for simultaneous acquisition of temperature mapping for adipose and non-adipose tissues, providing an accurate temperature monitoring comparable to a fiber-optic sensor as well as rapid acquisition.



Tissue-Mimicking Phantoms with Tunable Acoustic and Mechanical Properties for Visualizing MRgFUS Cavitation Lesions

Elizabeth MacKayedee Joyce Allen¹, Henrik Odeen², Paul-Emile Victor Passe-Carlus¹, Hunter Harris¹, and Steven Allen¹

¹Electrical Engineering, Brigham Young University, Provo, UT, United States, ²University of Utah, Salt Lake, UT, United States

Keywords: MR-Guided Focused Ultrasound, Phantoms, histotripsy, cavitation, lesioning, HIFU

Motivation: Develop tissue-mimicking phantoms for MR-guided focused ultrasound (MRgFUS) procedures, enabling precise cavitation lesion visualization.

Goal(s): Phantoms with tunable acoustic and mechanical properties, capable of producing MR image contrast when exposed to cavitation lesioning. Previous designs lacked tunable parameters or MR contrast, hindering comprehensive study of cavitation behavior. This project seeks to fill this gap by developing versatile phantoms with MR contrast.

Approach: Combine evaporated milk, saline, agarose, and live red blood cells to create versatile phantoms. Conduct systematic experiments to validate tunable acoustic attenuation, mechanical stiffness, and lesion contrast for MRgFUS.

Results: Successfully produced customizable phantoms with excellent lesion contrast in MRgFUS.

Impact: Researchers can use the results presented here to construct MR visible phantoms that interrogate acoustic cavitation.



Using Magnetic Resonance Imaging to visualize ultrasound wave propagation through a medium

Paul-Emile Victor Passe-Carlus¹, Davi Ferrazza Cavinatto¹, Carson Reed¹, Elizabeth Allen¹, and Steven P Allen¹

¹Brigham Young University, Provo, UT, United States

Keywords: MR-Guided Focused Ultrasound, Focused Ultrasound, Ultrasound, Electromagnet, Gradient, Brain

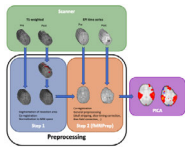
Motivation: Lack of a feedback mechanism renders focused ultrasound neuromodulation results inconsistent and difficult to reproduce.

Goal(s): This study hypothesis that electromagnets coupled with MRI can quantify low pressure acoustic fields in a gel sample.

Approach: We constructed a custom resonant electromagnet coil to encode propagating acoustic waves into the complex phase of MR images.

Results: Acoustic propagation appeared in the phase patterns of MR images, they differed from hydrophone measurements. The speed of sound was correct, but the measured pressure amplitude was different.

Impact: This is the first acquisition of acoustic waves using MRI with a human compatible coil.



Implementation of a Data Analysis Pipeline for intraoperative fMRI

Nicolas Weigl^{1,2,3}, Roxane Licandro³, Matthias Tomschik¹, Jonathan Wais¹, Cora Hedrich⁴, Julia Shawarba¹, Gregor Kasprian⁵, Karl Rössler^{1,6}, Christian Dorfer¹, and Gilbert Hangel^{1,2,6}

¹Department of Neurosurgery, Medical University of Vienna, Vienna, Austria, ²High-field MR Center, Department of Biomedical Imaging and Image-guided Therapy, Medical University of Vienna, Vienna, Austria, ³Computational Imaging Research Lab (CIR), Department of Biomedical Imaging and Image-guided Therapy, Medical University of Vienna, Vienna, Austria, ⁴Department of Pediatrics and Adolescent Medicine, Medical University of Vienna, Vienna, Austria, ⁵Department of Radiodiagnostics, Medical University of Vienna, Vienna, Austria, ⁶Christian Doppler Laboratory for MR Imaging Biomarkers, Vienna, Austria

Keywords: Other Interventional, Software Tools, fMRI Preprocessing

Motivation: Immediate changes in functionality during brain surgery in tumor and epilepsy patients are worth investigating in order to improve prediction of surgical outcomes.

Goal(s): We want to implement a preprocessing-pipeline for pre- and post-resection data that allows comparison between both scans and the application of further analysis methods.

Approach: We propose a two-step approach, where we first pre-register the anatomical data to MNI-space with consideration of the resection area and then use this data in a second step for preprocessing of fMRI data.

Results: The preprocessing gives satisfactory results that enable further analysis of intraoperative fMRI data, such as PICA.

Impact: We showed that the difficult case of pre- and post-resection data preprocessing is feasible and allows analysis of intraoperative fMRI data. This enables further investigation of changes in brain functionality during surgery which might lead to improvements in neurosurgery.

Model	Accuracy	AUC
Support Vector Machine	0.77	0.80
Naive Bayes	0.75	0.78
Decision Tree	0.76	0.79
Ridge Regression	0.77	0.80

Predicting antiseizure medication treatment outcome using AI and Structural MRI

Mohammad-Reza Nazem-Zadeh¹, Daniel Thom¹, Debabrata Mishra¹, Shani Nguyen¹, Zhibin Chen¹, Richard Shekwan Chang¹, Ben Sinclair¹, Meng Law¹, and Patrick Kwan¹

¹Neuroscience, Monash University, Melbourne, Australia

Keywords: MR-Guided Interventions, Machine Learning/Artificial Intelligence, drug outcome estimation, seizure freedom


Motivation: Implementation of AI-driven precision medicine and finding the most effective Antiseizure Medications.

Goal(s): To predict outcomes of drug interventions in epilepsy patients and categorize them into distinct seizure outcome groups.

Approach: The research employs both patient characteristic, clinical, and MRI features going through a feature selection step followed by binary classification using Support Vector Machine, Naive Bayes, Decision Tree, and Ridge Regression.

Results: Ridge regression combined with genetic algorithm outperformed the others, achieving an accuracy of 0.77 and AUC (Area Under the Curve) of 0.80 in predicting seizure outcome. This success was attained using a total of 18 MRI features and 10 ASMs.

Impact: Our model may help selection of the most effective ASM for individual patients. This may reduce the need for consecutive drug trials involving ineffective medications, thereby alleviating associated burdens.



Needle Artifact Prediction by Modeling Dephasing in MR-Guided Interventions

Jonas Frederik Faust^{1,2}, Axel Joachim Krafft¹, Jianing Pang³, Mark Edward Ladd^{2,4,5}, and Florian Maier¹

¹Siemens Healthcare GmbH, Erlangen, Germany, ²Faculty of Physics and Astronomy, Ruprecht-Karls-Universität Heidelberg, Heidelberg, Germany, ³Siemens Medical Solutions USA Inc, Malvern, PA, United States, ⁴Medical Physics in Radiology, German Cancer Research Center (DKFZ), Heidelberg, Germany, ⁵Faculty of Medicine, Ruprecht-Karls-Universität Heidelberg, Heidelberg, Germany

Keywords: MR-Guided Interventions, MR-Guided Interventions, needle artifact, device artifact, needle intervention, percutaneous intervention, modelling

Motivation: MR-guided needle interventions benefit from prior knowledge of needle artifact size and shape, as the artifact is important for instrument visualization and localization.

Goal(s): To investigate an analytical model for the dephasing artifact of a 20-gauge aspiration needle in GRE imaging based on material and imaging parameters.

Approach: Model accuracy was evaluated in-vitro for $B_0 = 0.55T/1.5T/3T$, $res = (1mm)^3/(2mm)^3$ and $TE = 5ms/15ms/25ms$ using Dice score (DSC) and Hausdorff distance (d_H) as metrics.

Results: For isotropic voxel grids, the dephasing needle artifact could be well approximated by the model (DSC $\geq 86\%$, $d_H \leq 2$ voxels).

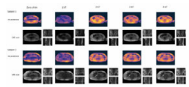
Impact: The approximation of needle artifacts using an analytical model provides an instructive way for artifact size prediction and can potentially facilitate MR-guided intervention planning (e.g., the choice of imaging parameters, needle selection and system selection).

B0 & B1 Coils & Phantoms

Exhibition Hall (Hall 403)

Tuesday 15:45 - 16:45

4941



In-vivo 7T body MRI with complete abdominal coverage using pTx and a 32-Tx-channel whole-body RF antenna array

Johannes A. Grimm^{1,2}, Christoph S. Aigner³, Constantin Schorling¹, Sebastian Dietrich³, Stephan Orzada¹, Thomas M. Fiedler¹, Mark E. Ladd^{1,2,4}, and Sebastian Schmitter^{1,3,5}

¹Medical Physics in Radiology, German Cancer Research Center (DKFZ), Heidelberg, Germany, ²Faculty of Physics and Astronomy, Heidelberg University, Heidelberg, Germany, ³Physikalisch-Technische Bundesanstalt (PTB), Braunschweig and Berlin, Germany, ⁴Faculty of Medicine, Heidelberg University, Heidelberg, Germany, ⁵Center for Magnetic Resonance Research, University of Minnesota, Minneapolis, MN, United States

Keywords: High-Field MRI, Parallel Transmit & Multiband, whole-body, abdomen, kT-points, free-breathing, 3D, RPE acquisition


Motivation: Flip angle variations or voids are problematic at 7T, especially when large fields of excitation are needed, such as for the entire abdomen.

Goal(s): To homogeneously excite the whole abdomen using dynamic pTx and to investigate the minimal number of kT-points necessary.

Approach: Dynamic pTx is applied in the abdomen using a 32-Tx-channel whole-body array and free-breathing relative B_1^+ mapping.

Results: The preliminary data indicates that exciting the whole abdomen is feasible and that dynamic pTx yields sufficient FA homogeneity in all subjects.

Impact: The preliminary data indicates that exciting the whole abdomen is feasible and that dynamic pTx yields sufficient FA homogeneity in all subjects.



Investigating the robustness of estimating B₁⁺-maps by a neural network at different UHF sites.

Kimon Hadjikiriakos¹, Felix Krüger¹, Felix Zimmermann¹, Layla Tabea Riemann¹, Katja Degenhardt¹, Kerstin Hammernik², Johannes Grimm^{3,4}, Simon Schmidt⁵, Greg Metzger⁵, Mark E. Ladd⁵, Tobias Schaeffter¹, and Sebastian Schmitter^{3,5,6}

¹Physikalisch-Technische Bundesanstalt (PTB), Braunschweig and Berlin, Germany, ²School of Computation, Information and Technology, Technical University of Munich, Munich, Germany, ³Medical Physics in Radiology, German Cancer Research Center (DKFZ), Heidelberg, Germany, ⁴Faculty of Physics and Astronomy, Heidelberg University, Heidelberg, Germany, Heidelberg, Germany, ⁵Center for Magnetic Resonance Research, University of Minnesota, Minneapolis, MN, United States, Minneapolis, MN, United States, ⁶Center for Magnetic Resonance Research, University of Minnesota, Minneapolis, MN, United States, Minneapolis, MN, United States, Minneapolis, MN, United States, Minneapolis, Germany

Keywords: High-Field MRI, RF Pulse Design & Fields, High-Field MRI, pTx, B₁⁺ mapping, neural networks

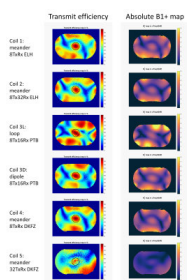
Motivation: B₁⁺-maps needed for subject-specific pTx can be derived from localizers using a neural network (NN), omitting separate B₁⁺-mapping. Ideally, a single, general NN applicable to all UHF sites is highly desired.

Goal(s): Investigate the robustness of a neural network predicted B₁⁺-field maps. Utilizing receive profiles from an 8Tx/32Rx head coil as neural network input.

Approach: Comparing the performance on data from identical and different commercial head coils across multiple MRI sites.

Results: Achieving SSIMs as high as 96% and RMSEs as low as 2.7%, with error mapping predominantly localizing discrepancies at the cranial margins, suggesting that larger datasets could enhance Gaussian convergence.

Impact: The study suggests that a single NN trained by a large B₁⁺ library for one type of pTx head coil may be disseminated to other UHF sites that use the same coil. This will enable a fast, streamlined pTx calibration.



A comparison of various custom-built pTx RF arrays for body imaging at 7T with regard to their transmit efficiency.

Johannes A. Grimm^{1,2}, Oliver Kraff³, Markus May^{3,4}, Max Lutz⁵, Stephan Orzada¹, Harald H. Quick^{3,4}, Mark E. Ladd^{1,2,3,6}, and Sebastian Schmitter^{1,5,7}

¹Medical Physics in Radiology, German Cancer Research Center (DKFZ), Heidelberg, Germany, ²Faculty of Physics and Astronomy, Heidelberg University, Heidelberg, Germany, ³Erwin L. Hahn Institute for Magnetic Resonance Imaging, Universität Duisburg-Essen, Essen, Germany, ⁴High Field and Hybrid MR Imaging, University Hospital Essen, Essen, Germany, ⁵Physikalisch-Technische Bundesanstalt (PTB), Braunschweig and Berlin, Germany, ⁶Faculty of Medicine, Heidelberg University, Heidelberg, Germany, ⁷Center for Magnetic Resonance Research, University of Minnesota, Minneapolis, MN, United States

Keywords: RF Arrays & Systems, RF Arrays & Systems, Ultra highfield, 7T, coil comparison, pTx, transmit efficiency

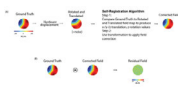
Motivation: A standardized pTx body array would be highly beneficial for 7T, especially as a step toward achieving an extension of the existing 7T CE label/FDA clearance to whole-body MRI.

Goal(s): To compare the transmit performance (Tx efficiency/coverage) of 5 different existing body coils containing different element types.

Approach: Measure relative and absolute B₁⁺ maps and evaluate them regarding the Tx efficiency and Tx heat-foot coverage.

Results: The B₁⁺ efficiency was similar for all local coil concepts with some differences in heat-foot excitation coverage. The remote array achieved the largest heat-foot excitation coverage and can achieve similarly high flip angles as the local arrays.

Impact: B₁⁺ efficiency was similar for all local coil concepts with some differences in excitation coverage. The remote array achieved the largest excitation coverage and can achieve similarly high flip angles as the local arrays if sufficient transmit power is available.



Field-based spatial self-registration of multi-coil hardware for B₀ field control

Isabelle Zinghini¹, Ian Macleod¹, Carlotta Ianniello¹, Sebastian Theilenberg¹, and Christoph Juchem^{1,2}

¹Biomedical Engineering, Columbia University, New York, NY, United States, ²Radiology, Columbia University, New York, NY, United States

Keywords: System Imperfections, System Imperfections: Measurement & Correction

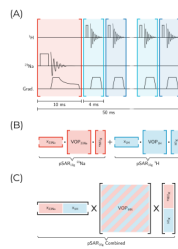
Motivation: Successful multi-coil B₀ field control relies on reproducible hardware placement.

Goal(s): Our goal was to detect hardware misplacements from MC-generated field patterns alone (i.e. without field probes) to allow spatial transformations for correction.

Approach: We co-registered unique field maps before and after hardware displacements to derive the underlying translation and rotation parameters.

Results: In simulation and preliminary scanner validation, hardware misplacements were detected with sub-millimeter/sub-degree precision.

Impact: Field-based spatial self-registration for multi-coil field inserts is expected to allow optimal B₀ field control even with differences in hardware placement, thus preserving the best shim performance.



Improved multinuclear parallel transmit optimization using multinuclear virtual observation points

Simon Schmidt¹ and Gregory J Metzger¹

¹Center for Magnetic Resonance Research, University of Minnesota, Minneapolis, MN, United States

Keywords: High-Field MRI, High-Field MRI, X-nuclei, SAR, VOP

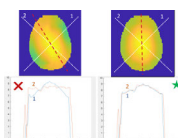
Motivation: Managing peak local SAR for pTx-enabled studies at UHF is challenging, especially for multinuclear acquisitions.

Goal(s): To evaluate the feasibility and potential advantages of multinuclear VOPs for pTx optimizations in multinuclear studies.

Approach: Simulation data was used to perform L-curve analyses to quantify the achievable minimal excitation errors at different peak 10g local SAR levels using both mononuclear and multinuclear VOPs.

Results: Multinuclear VOPs can substantially improve excitation performance at a set peak 10g local SAR level in multinuclear acquisitions by preserving the spatial correlation between the 10g local SAR resulting from each individual nucleus's excitation.

Impact: The improved ¹H excitation performance enabled through multinuclear VOPs can lead to improved image quality and reduced scan times for a variety of multinuclear imaging applications.



B1 SHIM CALIBRATION USING 1D ENCODED B1 DATA

Andrew J Wheaton¹ and Wayne R Dannels¹

¹Canon Medical Research USA, Mayfield, OH, United States

Keywords: System Imperfections, System Imperfections: Measurement & Correction, B1 shim

Motivation: To develop a method for fast per-patient calibration of B1 shim parameters.

Goal(s): To reduce scan time for per-patient B1 shimming calibration to improve patient throughput.

Approach: A key insight is that 1D projections acquired with specific projection orientations are sufficient to capture B1 distribution patterns. By comparing a pair of orthogonal B1 projections in the brain or by measuring average B1 amplitude of a pair of ROIs in a single projection across the breast, left-right B1 symmetry can be measured.

Results: Optimal B1 shim settings can be determined with a total time < 1 second as confirmed by B1 maps.

Impact: The proposed method for per-patient B1 shimming calibration using 1D B1 projections instead of 2D B1 maps can quickly calibrate B1 shimming parameters in less than one second.



A Next Generation Surface Array For Body Imaging at 7T

Tobey D Haluptzok¹, Russell L Lagore¹, Simon Schmidt¹, and Gregory J Metzger¹

¹University of Minnesota, Minneapolis, MN, United States

Keywords: RF Arrays & Systems, High-Field MRI

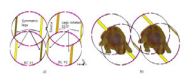
Motivation: Improved RF coil performance is needed to realize the gains from UHF body imaging.

Goal(s): Design a 7T body array with improved stability and increased transmit/receive performance.

Approach: A 32 channel loop-dipole (32LD) array was constructed with a shield allowing for on board electronics. Dipoles were transceivers while loops were coupled in groups of three on transmit while receiving separately. Comparisons were made with an existing 16LD array.

Results: The 32LD is more stable, has a lower flatter z-profile on transmit, 20% higher central SNR and supports parallel imaging on all axes

Impact: The new 32LD array provides a more robust platform for clinical translation of UHF body imaging while approaching the theoretical gains in SNR and improved parallel imaging performance enabling increased spatiotemporal resolutions at 7T.



Single port quadrature polarization of two birdcage coils for small animal imaging

Daniel Hernandez¹, Jae Jun Lee², Sang-Woo Kim², Taewoo Nam³, Eunwoo Lee³, and Kyoung-Nam Kim⁴

¹Neuroscience Research Institute, Gachon University, Incheon, Korea, Republic of, ²Non-clinical Center, KBIO Osong Medical Innovation Foundation, Chungbuk, Korea, Republic of, ³Department of Health Sciences and Technology, GAIHST, Gachon University, Incheon, Korea, Republic of, ⁴Department of Biomedical Engineering, Gachon University, Incheon, Korea, Republic of

Keywords: Hybrid & Novel Systems Technology, Prenatal

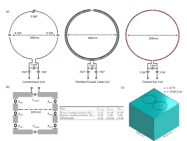
Motivation: The development of hardware dedicated to pre-clinical applications that can produce high quality images for small animal MRI systems with limited transmission channels.

Goal(s): a double birdcage coil that can deliver uniform field for multiple rats, while having only one transmission channel.

Approach: Employing electromagnetic simulations, we devised a geometric arrangement comprising two birdcage coils with a leg distribution rotated relative to each other. This configuration enables the generation of uniform, high-intensity circularly polarized fields.

Results: Uniform magnetic fields were acquired with double birdcage coil with a single excitation port. These results also showed uniform field and with similar intensity between two rats.

Impact: By employing double birdcage coils with rotated leg distributions, we achieve the generation of uniform and strong circularly polarized magnetic fields. This breakthrough offers significant advancements in pre-clinical applications and has the potential to improve research in small animal MRI.



7T MRI Coils: Streamline Approach in Analysis of Coil Coupling

Jules Vliem¹ and Irena Zivkovic¹

¹Electrical Engineering, Eindhoven University of Technology, Eindhoven, Netherlands

Keywords: High-Field MRI, RF Arrays & Systems, Coupling

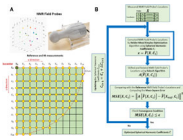
Motivation: To gain a better understanding of electromagnetic (EM) interactions in RF coil designs by visualizing their EM flow.

Goal(s): Identifying the dominant coupling mechanism in different coil types through visualization of electric and magnetic fields and power flow.

Approach: Simulating conventional, shielded-coaxial-cable (SCC), twisted pair coils, and square loops (self-decoupled coils) to visualize their EM fields using streamlines.

Results: Diverse coupling behaviors are observed among the coil types, each demonstrating unique dominant mechanisms. A high resemblance in the EM flow between the self-decoupled coil and the SCC and twisted pair coils was found.

Impact: Identifying the dominant coupling mechanism in different coil designs with streamlines can help in adjusting the coil design for maximum interelement decoupling when placed in an array configuration.



Open-Source Algorithm for 3D Gradient Nonlinearity Characterization Using a Rigid Arrangement of NMR Field Probes

Mojtaba Shafiekhani¹, Sebastian Littin¹, Ying Hua Chu², Yi-Cheng Hsu², Maxim Zaitsev¹, and Niklas Wehkamp¹

¹Division of Medical Physics, Department of Diagnostic and Interventional Radiology, University Medical Center Freiburg, Faculty of Medicine, University of Freiburg, Freiburg, Germany, ²MR Research Collaboration Team, Siemens Healthineers Ltd., Shanghai, China

Keywords: Gradients, Gradients

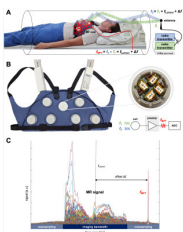
Motivation: MRI users rely on vendor-specific means to correct for distortions due to gradient nonlinearity. This study endeavors to measure gradient nonlinearities without a dedicated phantom for MR systems where accurate correction parameters are unavailable.

Goal(s): Develop a nonproprietary gradient nonlinearity measurement procedure.

Approach: We conduct NMR field probe measurements to determine the gradient nonlinearity. A dedicated algorithm detects inconsistencies between the apparent probe positions and seeks the optimal spherical harmonic coefficients correcting for distortions.

Results: We demonstrate the feasibility of the proposed measurement and a reduction of distortions in MR images.

Impact: The proposed nonproprietary approach for measuring gradient nonlinearity induced distortions without a dedicated phantom has the potential to promote accuracy and reproducibility of imaging studies across different MRI systems, if the sites are equipped with a field camera.



Motion-corrected supine breast MRI using a flexible coil vest and beat pilot tones – preliminary results

Lena Nohava¹, Karyna Isaieva², Roberta Frass-Kriegl¹, Bastian Rapp¹, Raphaela Czerny¹, Onisim Soanca¹, Jacques Felblinger², Freddy Odille², and Elmar Laistler¹

¹High Field MR Center, Center for Medical Physics and Biomedical Engineering, Medical University of Vienna, Vienna, Austria, ²IADI, Université de Lorraine, INSERM U1254, Nancy, France

Keywords: RF Arrays & Systems, Breast

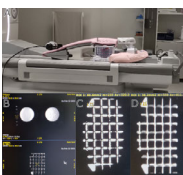
Motivation: This study addresses the challenge of motion artifacts in free-breathing supine breast MRI using a flexible RF coil, aiming to improve image quality and patient comfort.

Goal(s): The primary goal is to demonstrate the feasibility of motion correction using beat pilot tones (BPT) in combination with the GRICS algorithm, requiring no additional on-patient hardware.

Approach: A volunteer underwent supine breast MRI performing various breathing patterns, while BPT motion signals were extracted. The GRICS algorithm was used for retrospective motion correction.

Results: Motion artifacts were effectively reduced for flat abdominal and normal thoracic breathing. However, heavy thoracic breathing artifacts were insufficiently reduced.

Impact: Motion-corrected supine breast MRI with a flexible coil promises improved diagnostic image quality and increased patient comfort. Further optimization of acquisition and motion-correction techniques for clinical supine breast MRI will ultimately aid in early disease detection and management.



Utilizing DLP 3D Printing for MRI-Visible Phantoms in Biomedical Applications

Yanlu Wang¹

¹Oncology-Pathology, Karolinska Institute, Stockholm, Sweden

Keywords: Phantoms, Interventional Devices, Rapid prototyping, medical devices, phantoms, biopsy

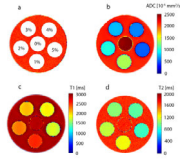
Motivation: This study is motivated by the authors to easily, and cheaply, manufacture phantoms and other accessories that is inherently dimensionally accurate, MRI compatible, and visible in MRI images.

Goal(s): The goal of the study is to develop a manufacturing method to create a MRI-visible localization grid for MR-guided breast biopsies.

Approach: By hollowing out the part without inclusions of any drainage holes, we can ensure liquid resin is trapped inside the part during the printing process.

Results: The finished part is shown to be inherently MRI visible as demonstrated on both T1- and T2-weighted images from our MRI biopsy protocol.

Impact: This approach offers an efficient and cost-effective solution for creating MRI-visible objects with high spatial accuracy, which is useful for producing phantoms and other MRI compatible accessories.



A comparison of different sources of soy lecithin for the production of MRI phantoms with systematic analysis of effects on T1, T2, and diffusion

Victor Fritz^{1,2,3}, Petros Martirosian¹, Jürgen Machann^{1,2,3}, and Fritz Schick¹

¹Department of Diagnostic and Interventional Radiology, University of Tuebingen, Section on Experimental Radiology, Tübingen, Germany, ²Institute for Diabetes Research and Metabolic Diseases of the Helmholtz Centre Munich at the University of Tuebingen, Tübingen, Germany, ³German Center for Diabetes Research (DZD), Neuherberg, Germany

Keywords: Phantoms, Phantoms


Motivation: While soy lecithin has been shown to be a beneficial substance for the production of diffusion phantoms, there is no research to date on whether this applies generally or only to specific product sources of soy lecithin.

Goal(s): To investigate the variability of the MR-related properties of three different types of soy lecithin (SL-1, SL-2, SL-3).

Approach: Aqueous soy lecithin solutions of different concentrations were prepared for all three soy lecithin sources and examined using DWI and Relaxometry.

Results: It was found that the MR-related properties of aqueous soy lecithin solutions are dependent on the type of soy lecithin used.

Impact: This work shows that MR properties of soy lecithin strongly depend on the product source. Related effects must be considered for the production of phantoms with tissue-like relaxation and diffusion properties.



Open-Source Simulator for Spatial Encoding Effects in Highly Variable B0 and Gradient Fields

Radhika Tibrewala^{1,2,3}, Christopher Collins^{1,2,3}, Jan Paska^{1,2}, Jakob Assländer^{1,2,3}, and Daniel K Sodickson^{1,2,3}

¹Bernard and Irene Schwartz Center for Biomedical Imaging, Department of Radiology, New York University Grossman School of Medicine, New York, NY, United States, ²Center for Advanced Imaging Innovation and Research (CAI2R), Department of Radiology, New York University Grossman School of Medicine, New York, NY, United States, ³Vilcek Institute of Graduate Biomedical Sciences, New York University Grossman School of Medicine, New York, NY, United States

Keywords: Hybrid & Novel Systems Technology, Simulations, spatial encoding

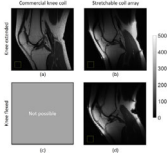
Motivation: Design of accessible scanners may require accounting for substantial magnetic field inhomogeneities, which challenge assumptions used in MRI simulators.

Goal(s): To capture the encoding effects of strong field variations accurately and efficiently, predicting distortions of input images.

Approach: We discretized magnetic fields as usual but extended the MR signal simulation at each grid point from the 0th-order approximation, which assumes a locally-constant field, to a 1st-order approximation, which assumes a locally-linear field.

Results: The 1st-order approximation, which has an analytic solution, better captures strongly varying fields and enables simulations on a coarser grid, greatly improving computational efficiency.

Impact: The simulator enables evaluation of scanner designs with strongly varying magnetic fields. Simulated images can be utilized to generate training data efficiently from existing ground-truth images, enabling exploration of machine-learning techniques prior to the construction of prototype systems.



Development and dynamic in vivo evaluation of a multi-channel stretchable self-tuning coil array.

Elizaveta Motovilova¹, Terry Ching², Jana Vincent³, Ek Tsoon Tan⁴, Victor Taracila³, Fraser Robb³, Michinao Hashimoto², Darryl B. Sneag⁴, and Simone Angela Winkler¹

¹Weill Cornell Medicine, New York, NY, United States, ²Singapore University of Technology and Design, Singapore, Singapore, ³GE Healthcare, Aurora, OH, United States, ⁴Hospital for Special Surgery, New York, NY, United States

Keywords: RF Arrays & Systems, RF Arrays & Systems, liquid metal, stretchable RF coils

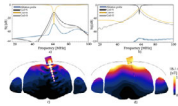
Motivation: Motivated by the limitations of traditional RF receive coils, this study aims to demonstrate *in vivo* imaging using a conformal and stretchable, self-tuning liquid metal coil array.

Goal(s): This study's goal was to demonstrate improved signal-to-noise ratio (SNR) with the stretchable array compared to commercial coils.

Approach: We designed and fabricated a one-dimensional 6-channel stretchable coil array and tested it *in vitro* and in healthy volunteers using standard knee imaging sequences.

Results: In vitro and in vivo experiments demonstrated an SNR improvement of 4.7x over a dedicated commercial knee coil.

Impact: Our self-tuning stretchable coil array allows for maximized SNR and improved image quality due to its conformal fit and minimized distance from the target anatomy. This concept could also allow for dynamic imaging, leading to enhanced, clinically relevant, MRI applications



Optimizing RF Coil Design to Minimize RF Interference in MR-Guided Microwave Liver Ablations at 1.5T

Daniel Hernandez¹, Myung-Ho In², and Kyoung-Nam Kim³

¹Neuroscience Research Institute, Gachon University, Incheon, Korea, Republic of, ²Department of Radiology, Mayo Clinic, Rochester, MN, United States, ³Department of Biomedical Engineering, Gachon University, Incheon, Korea, Republic of

Keywords: System Imperfections, Interventional Devices

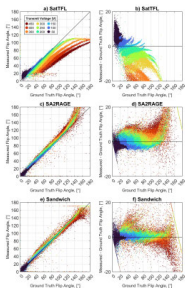
Motivation: Clinical MRI-guided microwave ablations often suffer from noise due to electromagnetic interference (EMI) between ablation probes and imaging coils. Instead of modifying the clinical microwave ablation system that could compromise FDA-approval, we explore alternative coil designs to mitigate the noise.

Goal(s): Minimize EMI between the microwave ablation probes and imaging coils during clinical MR-guided microwave ablations.

Approach: We applied a band-pass filter, studying the impact of coil size, and investigating efficient coil combinations to reduce interference.

Results: A band-pass filter led to a 89% improvement in field uniformity. Also employing smaller coils can mitigate the ripple effects induced by the ablation probe.

Impact: Our study addresses the critical need to reduce electromagnetic interference (EMI) between microwave ablation probes and imaging coils during clinical MR-guided microwave ablations at 1.5T. Motivated by the interference challenges in current clinical setups, we develop methods to mitigate EMI.



A Comparison of FLASH-based Volumetric B₁⁺ Mapping Methods in Phantom at 7 Tesla

James L. Kent¹, Patrick Liebig², Matthijs H. S. de Buck^{3,4,5}, Ladislav Valkovič^{6,7}, Iulius Dragonu⁸, and Aaron T. Hess¹

¹Wellcome Centre for Integrative Neuroimaging, FMRIB, Nuffield Department of Clinical Neurosciences, University of Oxford, Oxford, United Kingdom, ²Siemens Healthcare AG, Erlangen, Germany, ³Spinoza Centre for Neuroimaging, Amsterdam, Netherlands, ⁴Department of Computational Cognitive Neuroscience and Neuroimaging, Netherlands Institute for Neuroscience, KNAW, Amsterdam, Netherlands, ⁵Department of Radiology and Nuclear Medicine, Amsterdam University Medical Centers, University of Amsterdam, Amsterdam, Netherlands, ⁶Oxford Centre for Clinical Magnetic Resonance Research, John Radcliffe Hospital, University of Oxford, Oxford, United Kingdom, ⁷Department of Imaging Methods, Institute of Measurement Science, Slovak Academy of Sciences, Bratislava, Slovakia, ⁸Research & Collaborations GB&I, Siemens Healthcare Ltd, Frimley, United Kingdom

Keywords: High-Field MRI, Pulse Sequence Design, B₁⁺ Mapping, SatTFL, Sandwich, SA2RAGE, 7 Tesla

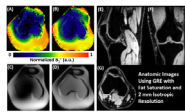
Motivation: Fast and accurate B₁⁺ mapping is critical for parallel transmission in ultra-high field MRI, but several options exist, and which is the most optimal is unknown.

Goal(s): To evaluate three FLASH-based volumetric B₁⁺ mapping methods; 2D SatTFL, 3D SA2RAGE and 3D Sandwich.

Approach: We acquired fully sampled absolute B₁⁺ maps at 7T in a realistic human head phantom across multiple transmission voltages to establish a ground truth and assess the dynamic range of each method.

Results: SA2RAGE and Sandwich both enable low-power non-selective RF pulses and maintain accuracy for low B₁⁺ regions. Sandwich has a 60% shorter acquisition time than SA2RAGE.

Impact: This study will help to inform a choice of B₁⁺ mapping sequences when imaging at ultrahigh field.



Development of a Multichannel Transmit Array for Knee Arterial Spin Labeling Imaging at 7 Tesla

Matt Waks¹, Alireza Sadeghi-Tarakameh¹, Lance DelaBarre¹, Xiaoping Wu¹, Jutta Ellermann¹, Gregor Adriany¹, Greg Metzger¹, and Xiufeng Li¹

¹Center for Magnetic Resonance Research, University of Minnesota, Minneapolis, MN, United States

Keywords: RF Arrays & Systems, Arterial spin labelling

Motivation: To overcome the limitations of a commercially-available single-transmit channel knee coil in terms of B₁⁺ inhomogeneity in the imaging region, and limited coverage in the proximal femoral meta-diaphysis for knee bone marrow arterial spin labeling (ASL) at 7T.

Goal(s): Our goal was to evaluate the B₁⁺ performance of possible transmit array designs, as the first step towards an optimized design for an ASL imaging knee coil.

Approach: 6- and 8-channel multichannel transmit array designs were explored experimentally and in simulation.

Results: Both evaluated transmit arrays provided more uniform B₁⁺ and better coverage in the labelling region compared to a single-transmit channel knee coil.

Impact: Development of pTx-capable knee coils will greatly improve the quality, reliability, and efficiency of knee ASL imaging at 7T and can provide the clinically critical but currently not available platform for the assessment of knee bone marrow perfusion.



A Novel 30-Channel Ultra-flexible Phased-Array for High-Resolution and Parallel Imaging Optimized MR Hand/Wrist/Brachial Plexus Imaging at 3T

YUN JEONG STICKLE¹, Clyve Follante¹, Canyon Aspy¹, Seth Blankenship¹, Tae-Young Yang¹, Tony Thomas¹, Maggie Fung², Yan Wen², Fraser Robb¹, Ek Tsoon Tan³, and Darryl Sneag³

¹MR ENGINEERING, GE HEALTHCARE, Aurora, OH, United States, ²MR Research, GE HEALTHCARE, Waukesha, WI, United States, ³Hospital for Special Surgery, New York, NY, United States

Keywords: RF Arrays & Systems, RF Arrays & Systems

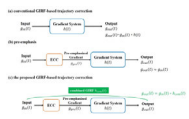
Motivation: Conventional hand/wrist coils have larger loop sizes and limited number of elements, resulting in insufficient SNR and acceleration capability for imaging small anatomic structures.

Goal(s): To develop a small flexible coil for hand/wrist, which improves spatial resolution, SNR and acceleration with flexibility for brachial plexus imaging as well when combined with other coils.

Approach: A 30-Channel parallel imaging optimized coil was built with the small flexible dual loop, high impedance internal cable baluns, exceptionally low noise preamplifiers and highly flexible mechanical materials.

Results: This study shows higher SNR and improved acceleration capabilities for results for this novel ultra-flexible coil compared to conventional coils.

Impact: This novel coil design provides comfortable fitting, high-resolution and higher acceleration for in-vivo 3T hand/wrist/unilateral brachial plexus imaging.



Joint pre-emphasis and post-processing method for improving GIRF-based spiral trajectory correction

Guangqi Li¹, Sisi Li¹, and Hua Guo¹

¹Center for Biomedical Imaging Research, Department of Biomedical Engineering, School of Medicine, Tsinghua University, Beijing, China

Keywords: System Imperfections, System Imperfections: Measurement & Correction, Trajectory correction

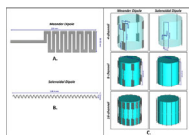
Motivation: Gradient imperfections typically cause ringing and blurring artifacts in spiral imaging. Gradient impulse response function (GIRF) characterizes the gradient system and can be applied for gradient prediction in image reconstruction. However, the low-pass characteristic of the gradient system could cause a penalty of the achieved resolution.

Goal(s): This work aims to improve the GIRF-based spiral trajectory correction.

Approach: A joint pre-emphasis and post-processing method was introduced to correct spiral trajectory. The effectiveness of our proposed method was tested on the phantom and in-vivo experiments.

Results: The ringing and blurring artifacts were further mitigated using our proposed method.

Impact: A joint pre-emphasis and post-processing correction strategy was proposed in this study. The results of phantom and in-vivo experiments indicate that our proposed method yields good image quality and effectively reduces the loss of the actual resolution.



A numerical investigation of meander and solenoidal dipole antenna array configurations for 7T MR applications.

Aditya Ashok Bhosale¹, Leslie Ying¹, and Xiaoliang Zhang¹

¹Biomedical Engineering, The State University of New York at Buffalo, Buffalo, NY, United States

Keywords: RF Arrays & Systems, RF Arrays & Systems

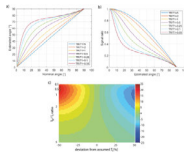
Motivation: Optimize dipole antennas for 7T MR applications.

Goal(s): Enable compact 300MHz dipole structures for higher-channel arrays.

Approach: Introduce a solenoidal dipole design and evaluate against meander designs using numerical simulations.

Results: Analyze H-field efficiency, electric-field distributions, coupling, and Q-factors in multi-channel arrays.

Impact: The introduction of a solenoidal dipole design overcomes limitations posed by meander structures, enabling shorter and compact 300MHz dipole antennas for 7T MR applications within higher-channel multi-channel arrays, positively impacting MR imaging efficiency and signal quality.



Fast and accurate 31P B1-mapping at high magnetic fields with short TRs.

Mark Stephan Widmaier^{1,2}, Antonia Kaiser¹, Salome Baup¹, Ying Xiao^{3,4}, Yun Jiang⁵, Zhiwei Huang^{2,3}, Daniel Wenz¹, and Lijing Xin¹

¹Animal imaging and technology core, CIBM Center for Biomedical Imaging, École Polytechnique Fédérale de Lausanne (EPFL), Lausanne, Switzerland, ²Laboratory for Functional and Metabolic Imaging, École Polytechnique Fédérale de Lausanne (EPFL), Lausanne, Switzerland, ³Animal imaging and technology core, CIBM Center for Biomedical Imaging, École polytechnique fédérale de Lausanne (EPFL), Lausanne, Switzerland, ⁴Laboratory for Functional and Metabolic Imaging, Ecole Polytechnique Fédérale de Lausanne (EPFL), Lausanne, Switzerland, ⁵Department of Radiology, Case Western Reserve University, Cleveland, Cleveland, OH, United States

Keywords: RF Pulse Design & Fields, RF Pulse Design & Fields, DAM, 31P, B1 mapping, fast B1, MRSI, X-Nuclei

Motivation: Fast and accurate B1 mapping for ³¹P MRI is challenging due to the low sensitivity of ³¹P nucleus and its long T1 relaxation times.

Goal(s): This study aims to develop a fast B1 mapping approach for ³¹P at 7T.

Approach: A look-up table approach was adopted to enable B1 mapping at short TR. Fast spiral encoding together with weighted averaging was implemented with a GRE sequence to further accelerate the acquisition.

Results: B1 mapping was validated in phantom and in vivo in human calf muscle and brain within a scan time of 10min.

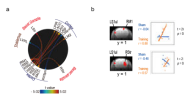
Impact: The presented fast and accurate B1 mapping correction method is particularly suited for moderate to short repetition times, showing promise for future applications in rapid X-nuclei imaging.

fMRI Connectivity: Wire Together, Fire Together

Exhibition Hall (Hall 403)

Wednesday 8:15 - 9:15

4963



Elucidation of whole-brain network in operant training using functional connectivity and immediate gene expression

Kazumi Kasahara^{1,2}, Keigo Hikishima³, Mariko Nakata⁴, Tomokazu Tsurugizawa¹, Noriyuki Higo¹, and Kenji Doya²

¹Human Informatics and Interaction Research Institute, National Institute of Advanced Industrial Science and Technology, Tsukuba, Japan, ²Neural Computation Unit, Okinawa Institute of Science and Technology Graduate University, Okinawa, Japan, ³Health and Medical Research Institute, National Institute of Advanced Industrial Science and Technology, Tsukuba, Japan, ⁴University of Tsukuba, Tsukuba, Japan

Keywords: Functional Connectivity, Neuroscience


Motivation: It is unclear how and what cellular-level changes cause changes in the whole-brain network in operant training.

Goal(s): To investigate the functional network changes and underlying cellular processes involved in operant learning.

Approach: We utilized resting-state functional magnetic resonance imaging (rsfMRI) and whole-brain immunohistochemical analysis of early growth response 1 (EGR1) in mice during the early and late stages of training.

Results: Increased functional connectivity and EGR1 regional correlations were observed between the limbic and thalamus or auditory cortex early, and between motor and somatosensory cortex and striatum in the late stage.

Impact: Our study is an initial effort to create a new experimental approach that combines rsfMRI and immunohistochemistry to connect large-scale and small-scale mechanisms of learning.



Functional connectome phenotype of multiple cerebrovascular disease markers and its interaction with plasma p-tau181 on downstream outcomes

Joanna Su Xian Chong¹, Fang Ji¹, Saima Hilal^{2,3,4}, Joyce Ruifen Chong^{3,4}, Jia Ming Lau¹, Boon Yeow Tan⁵, Narayanaswamy Venketasubramanian^{3,6}, Mitchell Kim Peng Lai^{3,4}, Christopher Li-Hsian Chen^{3,4}, and Juan Helen Zhou^{1,7,8}

¹Centre for Sleep and Cognition & Centre for Translational Magnetic Resonance Research, Yong Loo Lin School of Medicine, National University of Singapore, Singapore, Singapore, ²Saw Swee Hock School of Public Health, National University of Singapore and National University Health System, Singapore, Singapore, ³Memory Ageing & Cognition Centre, National University Health System, Singapore, Singapore, ⁴Department of Pharmacology, Yong Loo Lin School of Medicine, National University of Singapore, Singapore, Singapore, ⁵St Luke's Hospital, Singapore, Singapore, ⁶Raffles Neuroscience Centre, Raffles Hospital, Singapore, Singapore, ⁷Integrative Sciences and Engineering Programme (ISEP), National University of Singapore, Singapore, Singapore, ⁸Department of Electrical and Computer Engineering, National University of Singapore, Singapore, Singapore

Keywords: Functional Connectivity, Alzheimer's Disease, Cerebrovascular disease


Motivation: Cerebrovascular disease (CeVD) is assessed by several MRI markers, but their impact on brain functional connectivity (FC) remains unclear.

Goal(s): To examine how multiple CeVD markers influence FC, and how CeVD-related FC changes interact with Alzheimer's disease pathology to influence downstream outcomes.

Approach: We studied multivariate associations between four CeVD markers and whole-brain FC in 529 participants, and how this CeVD-related FC phenotype interacted with plasma p-tau181 to influence longitudinal brain atrophy and cognitive decline.

Results: We identified a FC phenotype linked to high CeVD burden across all markers. This phenotype and p-tau181 contributed additively, but not synergistically, to atrophy and cognitive decline.

Impact: Using a multivariate approach, our study demonstrated that CeVD exerted widespread, non-MRI marker-specific effects on the whole-brain functional connectome. Further, we showed that AD and CeVD have additive but not synergistic effects on neurodegeneration and cognitive changes over time.



White matter-engaged multilayer network for evaluation of functional deficits in Alzheimer's disease

Lyuan Xu^{1,2}, Zhongliang Zu^{1,3}, Yurui Gao^{1,4}, Muwei Li^{1,3}, Kurt G. Schilling^{1,3}, Soyoung Choi^{1,3}, Adam W. Anderson^{1,3,4}, John C. Gore^{1,3,4}, and Zhaohua Ding^{1,2}

¹Vanderbilt University Institute of Imaging Science, Nashville, TN, United States, ²Department of Electrical and Computer Engineering, Vanderbilt University, Nashville, TN, United States, ³Department of Radiology and Radiological Sciences, Vanderbilt University Medical Center, Nashville, TN, United States, ⁴Department of Biomedical Engineering, Vanderbilt University, Nashville, TN, United States

Keywords: Functional Connectivity, Alzheimer's Disease

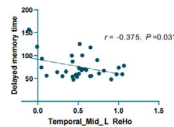
Motivation: The role of white matter (WM) in the functional connectivity within brain networks has not been well studied.

Goal(s): Our goal was to use a high-order graph model to comprehensively analyze brain functional networks that engage WM.

Approach: We constructed multilayer networks and analyzed network parameters in the brains of subjects with Alzheimer's disease (AD).

Results: Multilayer network analysis showed increased sensitivity for detecting significant deterioration in functional connectivity (FC) in AD.

Impact: Multilayer networks allow more comprehensive understanding of structure-function relations within the whole brain and may provide deeper insight into the pathophysiology of degenerative brain disease.



Alterations in Spatial Working Memory and Brain Activity following 24h of Acute Sleep Deprivation in Healthy Men: A Resting-State fMRI Study

Lili Xu¹, Haoyuan Zhang², Xicong Geng², and Jing Zhang¹

¹Department of Magnetic Resonance, Lanzhou University Second Hospital, Lanzhou, China, lanzhou, China, ²School of Psychology, Northwest Normal University, Lanzhou, China, lanzhou, China

Keywords: fMRI Analysis, fMRI (resting state)

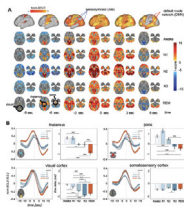
Motivation: The precise neural mechanisms through which SD induces spatial working memory impairment are currently the subject of ongoing investigation.

Goal(s): The purpose is to investigate the causes of spatial working memory deficits in subjects following SD.

Approach: we employed a combination of ROCFT and rs-fMRI.

Results: We observed elevated ALFF and ReHo in the Precuneus_L, ParaHippocampal_R, Postcentral_R, and Temporal_Mid_L regions, as well as reduced ReHo in the bilateral Frontal_Sup regions. Furthermore, we identified a negative correlation between the ReHo of Temporal_Mid_L and the duration of the 30min delayed recall, suggesting that these changes may contribute to the impaired spatial working memory following SD.

Impact: The alterations in ALFF and ReHo after SD point to potential underlying mechanism for spatial working memory impairment. These findings offer promising avenues for future research aimed at elucidating the intricate neural mechanisms responsible for SD-induced spatial working memory deficits.



Modulation of cross-hierarchy propagating waves across sleep stages

Xufu Liu¹, Dante Picchioni², Yifan Yang¹, Jacco de Zwart², Jeff Duyn², and Xiao Liu^{1,3}

¹Department of Biomedical Engineering, The Pennsylvania State University, University Park, State College, PA, United States, ²National Institute of Neurological Disorders and Stroke, National Institutes of Health, Bethesda, MD, United States, ³Institute for Computational and Data Sciences, The Pennsylvania State University, University Park, State College, PA, United States

Keywords: fMRI Analysis, fMRI (resting state), sleep

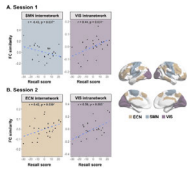
Motivation: Endogenous brain activity plays a pivotal role during sleep. Previous research suggested that endogenous brain activity during wakefulness can take the form of infra-slow waves propagating along the cortical hierarchical gradient. But it remains unclear how these infra-slow waves modulate across sleep stages.

Goal(s): To elucidate sleep stage dependent changes in the cross-hierarchy propagations.

Approach: We measured and analyzed overnight fMRI/EEG data.

Results: The cross-hierarchy propagating waves modulate systematically across sleep stages. REM sleep features more frequent propagations from sensory/motor regions to higher-order brain networks, which are associated with eye movements and characterized by phase shifts in the thalamus, pons, and visual cortex.

Impact: The findings reveal a highly structured nature of endogenous brain dynamics during REM sleep and their potential link to known REM features of electrophysiological PGO waves and eye movements.



Functional brain network reconfiguration from rest to movie changes across repeated movie-viewing and associates with free recall performance

Eric Kwun Kei Ng¹, Wan Lin Yue¹, Xing Qian¹, Kian Foong Wong¹, Michael W L Chee¹, and Juan Helen Zhou^{1,2,3,4}

¹Centre for Sleep and Cognition, Yong Loo Lin School of Medicine, National University of Singapore, Singapore, Singapore, ²Centre for Translational MR Research, Yong Loo Lin School of Medicine, National University of Singapore, Singapore, Singapore, ³Integrative Sciences and Engineering Programme, NUS Graduate School, National University of Singapore, Singapore, Singapore, ⁴Department of Electrical and Computer Engineering, National University of Singapore, Singapore, Singapore

Keywords: Functional Connectivity, fMRI, functional reconfiguration, movie paradigm

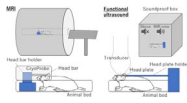
Motivation: It remains unclear if brain functional reconfiguration from resting state is cognitively relevant for naturalistic conditions.

Goal(s): To establish changes in brain functional connectivity (FC) similarity between rest and repeated movie watching and their relation with memory in young adults.

Approach: We studied intra- and inter network FC similarity changes across 3 movie-viewing BOLD fMRI sessions, and correlated similarity measures with memory recall scores of one movie.

Results: Movies with higher cognitive load and narrative structure evidenced stronger changes in rest-movie functional reconfiguration across sessions; association with recall scores shifted from sensory networks to associative networks over sessions. Higher similarity was more advantageous.

Impact: Rest-movie functional reconfiguration lent support to the hypothesis that less reconfiguration may reflect higher information processing efficiency by brain functional networks. It further informs memory encoding and retrieval in naturalistic contexts.



Effects of MRI acoustic noise on resting state functional connectivity

Keigo Hikishima^{1,2}, Tomokazu Tsurugizawa¹, Kazumi Kasahara¹, Ryusuke Hayashi¹, Ryo Takagi¹, Kiyoshi Yoshinaka¹, and Naotaka Nitta¹

¹National Institute of Advanced Industrial Science and Technology, Tsukuba, Japan, ²Okinawa Institute of Science and Technology Graduate University, Onna, Japan

Keywords: Functional Connectivity, Brain Connectivity, MRI acoustic noise

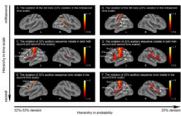
Motivation: Loud acoustic noise during resting state fMRI can affect functional connectivity (FC), but the precise effect of MRI acoustic noise on FC is not well understood.

Goal(s): To clarify the impact of MRI acoustic noise on FC.

Approach: FC in mice under MRI acoustic noise was investigated using functional ultrasound (fUS), a functional imaging method based on relative cerebral blood volume, and the FC obtained was compared with FC by fMRI.

Results: As acoustic noise increased, in the auditory network FC between the retrosplenial dysgranular and auditory cortexes decreased, while in the non-auditory network FC anticorrelation between the infralimbic and motor cortexes increased.

Impact: Anticorrelation between the default mode network (e.g., infralimbic cortex) and task-positive networks (e.g., motor cortex) is an important feature of brain network antagonism. Attention should be paid to the acoustic noise level when fMRI to evaluate anticorrelation of such networks.



Hierarchical auditory processing integrating macroscopic and mesoscopic neural networks

Yuwei Jiang¹, Yangjiayi Mu¹, and He Wang¹

¹*Institute of Science and Technology for Brain-Inspired Intelligence, Fudan University, Shanghai, China*

Keywords: Task/Intervention Based fMRI, fMRI (task based), layer-fMRI, neuroscience

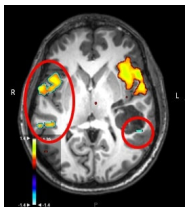
Motivation: The invasive microscopic research on the brain can only be widely conducted in animal models. Detecting signals in laminar level using noninvasive MRI helps us bridge knowledge between macro- and micro-research.

Goal(s): To understand the neural mechanism of hierarchical auditory processing in both macroscopic and mesoscopic brain cortex in-vivo.

Approach: We used the 7T MRI to perform the whole-brain-fMRI and layer-fMRI with ultra-high-resolution when human was listening to a hierarchical auditory sequence paradigm.

Results: The responses to the hierarchical auditory processing are not only along a pathway from auditory to frontal cortices, but also various across laminar cortex.

Impact: We used the layer-fMRI to find that the auditory processing is distributed across cortical layers in a hierarchical manner. The detection of auditory processing in both macroscopic and mesoscopic levels allows us to build predictive coding model in multiple dimensions.



Language Lateralization on resting state fMRI Vs task fMRI, in neurosurgical cases

SANTOSH KUMAR GUPTA¹ and RITHIKA SRIRAM¹

¹*MRI, P.D.Hinduja Hospital, Mumbai, India*

Keywords: Functional Connectivity, fMRI (resting state), fMRI (task)

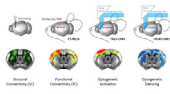
Motivation: Understanding hemispheric language dominance is crucial for surgery, yet task-based fMRI has many challenges. Resting-state fMRI shows promise, but its ability to depict language lateralization is still evolving, with varied results in literature.

Goal(s): To assess language dominance on rest fMRI in neurosurgical patients by different methods and seeing concordance with task-based fMRI.

Approach: We explored three calculation techniques for lateralization: first using individual seed volumes, second using voxel activation in ipsilateral hemisphere, and third using net voxel activation generated in bilateral hemispheres

Results: Maximum of 54.55% concordance of rest-fMRI with task-based fMRI was seen for language dominance, with one of the methods.

Impact: Our results emphasize that rest fMRI for language dominance should be used with caution and as an adjunct to task fMRI in neurosurgical patients.



Bilateral resting-state functional connectivity reflects spontaneous neural interactions measured by mouse fMRI with optogenetic silencing

Hyun Seok Moon¹, Thanh Tan Vo^{1,2,3}, and Seong-Gi Kim^{1,2}

¹Center for Neuroscience Imaging Research, Institute for Basic Science (IBS), Suwon, Korea, Republic of, ²Department of Biomedical Engineering, Sungkyunkwan University, Suwon, Korea, Republic of, ³Department of Intelligent Precision Healthcare Convergence, Sungkyunkwan University, Suwon, Korea, Republic of

Keywords: Functional Connectivity, fMRI

Motivation: Despite the widespread use of resting-state fMRI in the neuroscience field, the relationship between functional connectivity and neural interactions is not fully understood.

Goal(s): We aimed to explore whether resting-state functional connectivity arises from spontaneous neural interactions among brain regions.

Approach: We conducted resting-state and multi-site optogenetic fMRI in excitatory or inhibitory neuron-specific optogenetic mouse models and examined their relationship.

Results: Resting-state functional connectivity patterns were strongly correlated with optogenetic silencing-induced connectivity which revealed extensive intrahemispheric and interhemispheric neural interactions during rest. This result suggests that functional connectivity arises from neural interactions via polysynaptic structural connectivity.

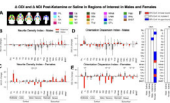
Impact: The results support the notion that functional connectivity stems from spontaneous neural interactions between regions. Our next goal is to investigate whether brain state-dependent functional connectivity alterations stem from enhanced or weakened neural interactions, using multi-site optogenetic silencing fMRI.

Neuroradiology Miscellaneous

Exhibition Hall (Hall 403)

Wednesday 9:15 - 10:15

4973



Noninvasive quantification of ketamine-induced structural plasticity in mice using multishell diffusion weighted imaging

Sedona Noel Ewbank¹, Alex Ronald Hart¹, Austen Brooks Casey², Jennifer A McNab¹, Boris Dov Heifets², and Raag Dar Airan¹

¹Department of Radiology, Stanford University, Stanford, CA, United States, ²Department of Anesthesiology, Perioperative and Pain Medicine, Stanford University, Stanford, CA, United States

Keywords: Pharmacology, Diffusion/other diffusion imaging techniques, Pharmacology

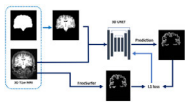
Motivation: To monitor treatment, we need noninvasive quantitation of the microstructural changes known to accompany rapid-acting antidepressant therapy.

Goal(s): Our goal was to develop a noninvasive biomarker of the structural plasticity induced by rapid-acting antidepressants.

Approach: Neurite orientation dispersion and density imaging (NODDI) was assessed before and after treating male and female mice with ketamine, with or without opioid blockade.

Results: Ketamine induced alterations of orientation dispersion index (ODI) and neurite density index (NDI) in brain regions involved in mood regulation and reward processing, particularly in females. Curiously, opioid blockade induced trendwise increases in NDI and ODI across multiple brain regions, independent of ketamine.

Impact: Our preliminary results indicate that multishell diffusion MRI tracks the brain microstructural changes known to be induced by ketamine and related rapid-acting antidepressants, enabling a noninvasive quantitative biomarker that could be used to track individual patient response to antidepressant therapy.



Accelerated Cortical Thickness Mapping Using Deep Learning

Jia-Xiu Chen¹, Teng-Yi Huang¹, Yu-Chen Liao¹, and Jui-Jung Yu¹

¹National Taiwan University of Science and Technology, Taipei, Taiwan

Keywords: Gray Matter, Data Analysis, Deep learning, Cortical thickness, ADNI

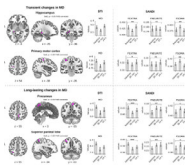
Motivation: The long processing time of current CT mapping methods hampers their use in clinical research. A faster and reliable CT mapping alternative is needed.

Goal(s): To create a deep-learning model that reduces CT mapping time without compromising accuracy or the ability to classify Alzheimer's disease.

Approach: We trained a 3D U-Net-based model on T1-weighted MRI datasets to produce CT maps, generating two model variants—one using skull-stripped and the other using both whole-brain and skull-stripped images. Performance was benchmarked against FreeSurfer.

Results: The complete Unet-based CT mapping workflow, inclusive of preprocessing, was executed in under a minute without relying on GPU acceleration.

Impact: The developed deep-learning-based method, executed within a minute, could accelerate neurological research related to CT values by providing fast and reliable procedure for CT mapping.



Time course of structural neuroplasticity induced by procedural motor learning: DTI vs SANDI

Guillermina Griffa¹, Marco Palombo², Abraham Yeffal¹, Hong-Hsi Lee³, Susie Y. Huang³, and Valeria Della-Maggiore¹

¹IFIBIO-Houssay, Department of Physiology, School of Medicine, University of Buenos Aires, Argentina, Buenos Aires, Argentina, ²Brain Research Imaging Centre (CUBRIC), School of Psychology and School of Computer Science and Informatics, Cardiff University, Cardiff, UK., Cardiff, United Kingdom, ³Athinoula A. Martinos Center for Biomedical Imaging, Department of Radiology, Massachusetts General Hospital, Harvard Medical School, Boston, MA, USA., Boston, MA, United States

Keywords: Gray Matter, Neuroscience, motor learning, plasticity, SANDI

Motivation: Performance gains during motor sequence learning (MSL) are linked to increased hippocampal activity and fast changes in mean diffusivity. Yet, DTI is not biologically specific.

Goal(s): To identify the biological compartment(s) driving changes in gray-matter microstructure during MSL.

Approach: We applied SANDI to multi-shell-DWI acquired in 28 subjects on the Connectome scanner before, 30 min, and 24h post MSL training.

Results: MSL-induced transient changes in DTI were associated with a temporary increase in soma fraction at 30 min, compatible with a fast homeostatic response (e.g. astrocytic swelling). Long-lasting DTI changes were associated with an increment in neurite fraction compatible with structural remodelling.

Impact: Our work may broaden the scope of understanding of human hippocampal memory and help pinpoint the biological substrates of plasticity. Moreover, it may set the basis for developing a biologically meaningful biomarker of neuroplasticity to detect early signs of neuropathology.



The causal effect of insomnia on the hippocampal volume and hippocampal plasticity.

Xixi Dang¹ and Yinghe Chen²

¹Department of Psychology, Hangzhou Normal University, Hangzhou, China, ²Faculty of Psychology, Beijing Normal University, Beijing, China

Keywords: Gray Matter, Brain, Mendelian randomization; sleep; hippocampus

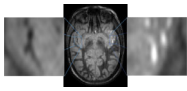
Motivation: The causal relationship between the sleep-related traits and the plasticity of subcortical brain volumes remains unclear.

Goal(s): This study aims to explore the causal relationship between two sleep-related traits (i.e., sleep duration and insomnia) and subcortical volumes.

Approach: Two-sample Mendelian randomization (MR) analysis

Results: We found a significant causal effect of insomnia but not sleep duration on the hippocampal volume. Moreover, insomnia showed significant causal influence on the structural plasticity of the hippocampus, which may be associated with the rates of hippocampal atrophy.

Impact: The causal effect of insomnia on the hippocampal volume and plasticity may explain the adverse effect of insomnia on memory and may offer new evidence which could push the exploration of sleep management to delay the course of neurodegenerative diseases.



Hybrid dynamic bright and black blood angiography by vessel-selective saturation angiography.

Wiebke Entelmann¹, Monika Huhndorf², Olav Jansen², and Thomas Lindner¹

¹Neuroradiology, Universitätsklinikum Hamburg-Eppendorf, Hamburg, Germany, ²Radiology, UKSH Kiel, Kiel, Germany

Keywords: Blood Vessels, Vessels


Motivation: Examining a simultaneous bright and black blood sequence.

Goal(s): Demonstrate ability to simultaneously acquire bright and black blood contrast in one image, providing simultaneous information on time-resolved artery-selective blood flow as well as the vessel walls integrity.

Approach: Feasibility was evaluated by comparing calculated magnetization from a Bloch simulation and measured signal values from volunteer.

Results: Simulated and measured image data showed a largely similar course over time points. An outlier time point has to be further investigated. Best black blood contrast to surrounding tissue was not found at the time point with the lowest blood signal.

Impact: The study demonstrates the ability to simultaneously acquire bright and black blood contrast in a single image set and resulting simultaneous information on time-resolved artery-selective blood flow as well as the vessel walls integrity.



Fontan Patients Exhibit Altered CBF and ATT Measurements in Gray and White Matter: an ASL Study.

Emma Carpenter¹, Clio González-Zacarías^{1,2}, Sneha Verma¹, Jian Shen^{1,3}, Botian Xu^{1,3}, Soyoung Choi⁴, Silvie Suriyany¹, Koen Baas⁵, Anand Joshi², Richard Leahy², Peter Chiarelli⁶, and John Wood^{1,7}

¹Cardiology, Children's Hospital Los Angeles, Los Angeles, CA, United States, ²Ming Hsieh Department of Electrical and Computer Engineering, University of Southern California Viterbi School of Engineering, Los Angeles, CA, United States, ³Department of Biomedical Engineering, University of Southern California, Los Angeles, CA, United States, ⁴Institute of Imaging Science, Vanderbilt University, Nashville, TN, United States, ⁵Department of Radiology and Nuclear Medicine, Amsterdam UMC, Amsterdam, Netherlands, ⁶Pediatric Neurosurgery, Children's Hospital Los Angeles, Los Angeles, CA, United States, ⁷Pediatrics CHLA, Keck School of Medicine of USC, Los Angeles, CA, United States

Keywords: Blood Vessels, Arterial spin labelling, Fontan, CBF, ATT, Oxygen Delivery


Motivation: Patients with Fontan palliation of single ventricular heart disease have significant cognitive deficits that may result from their chronically low cardiac output.

Goal(s): To determine whether global and regional brain oxygen delivery is normal in young adults after Fontan palliation.

Approach: We measured cerebral blood flow (CBF) and arterial transit time (ATT) in 28 young adult Fontan patients and 31 age and sex matched control subjects using pseudocontinuous time-encoded arterial spin labeling (PCASL).

Results: CBF and arterial transit time were increased, in Fontan subjects compared with controls. Oxygen delivery was decreased in the anterior and middle cerebral artery distribution.

Impact: These data suggest that physiologic compensation to the low cardiac output state produced by Fontan circulation is insufficient to maintain cerebral oxygen delivery. Time-encoded PCASL potential provides an important biomarker to judge surgical and medical interventions in these patients.



Longitudinal Imaging of Spinal Cord Myelin Following C5 Hemisection Lesions with 3D Ultrashort Echo Time (UTE) Magnetization Transfer MR Imaging

Qingbo Tang^{1,2}, Yajun Ma¹, Qun Cheng³, Jiang Du¹, Paul Lu³, and Eric Y Chang^{1,4}

¹Radiology, UCSD Health, La Jolla, CA, United States, ²Research Service, Veterans Affairs San Diego Healthcare System, San Diego, CA, United States, ³Neuroscience, UCSD Health, La Jolla, CA, United States, ⁴Radiology Service, Veterans Affairs San Diego Healthcare System, San Diego, La Jolla, CA, United States

Keywords: Spinal Cord, White Matter


Motivation: To characterize the dynamic spinal myelin changes in rats following C5 hemisection lesions, and to monitor the efficacy of stem cells or other remyelination treatments

Goal(s): To detect myelin degeneration or regeneration in the spinal cord after SCI

Approach: The rats were imaged post-injury noninvasively and longitudinally with a UTE-MT sequence for MT ratio (MTR) measurement¹. White matter was approximated by thresholding the MTR maps using values from the intact left (contralateral) side of spinal cord.

Results: A decrease in the white matter was observed on the right (ipsilateral) side caudal to the lesions, consistent with known myelin changes following spinal cord injury

Impact: Myelin changes in the rat spinal cord following hemisection lesions can be monitored non-invasively and longitudinally with MT ratio measurement. Such techniques can be used to detect myelin degeneration or regeneration in the spinal cord after SCI.



Detection of intracranial hemorrhage in healthy neonatal mice by T2*-weighted 7T MRI

Rena Kono¹, Maiko Ono², Raj Kumar Parajuli^{2,3}, Ryuta Koyama¹, and Yuhei Takado²

¹Graduate School of Pharmaceutical Sciences, The University of Tokyo, Tokyo, Japan, ²Institute for Quantum Life Science, National Institutes for Quantum Science and Technology, Chiba, Japan, ³Sydney Imaging Core Research Facility, The University of Sydney, Sydney, Australia

Keywords: Blood Vessels, Normal development, high-field MRI

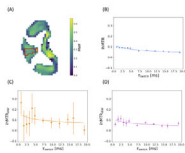
Motivation: Neonatal brain hemorrhage, which are observed in premature and even in full-term infants, could cause adverse neurological damage, however, the mechanism of hemorrhages is unknown and the validated information for neonatal hemorrhages, especially in asymptomatic neonates, is lacking.

Goal(s): Our goal was to detect hemorrhages in the brains of untreated postnatal mice and evaluate the spatiotemporal information.

Approach: T2*-weighted MR images were obtained from records of C57BL/6j mice at P0-1 and acquired hemorrhages were cross-validated by histological analysis.

Results: We found that hemorrhages occur throughout the brain of healthy neonatal mice.

Impact: In vivo MRI of untreated postnatal mice may serve as a useful tool to further investigate asymptomatic hemorrhages in full-term infants and will deepen our understanding of not only the mechanism of neonatal hemorrhages but also the brain development.



Combining Inhomogeneous Magnetization Transfer and Myelin Water Imaging at 9.4T: Methodology and Limitations

Masha Novoselova^{1,2,3}, Andrew Yung^{2,3}, and Piotr Kozlowski^{1,2,3}

¹Physics & Astronomy, University of British Columbia, Vancouver, BC, Canada, ²Radiology, University of British Columbia, Vancouver, BC, Canada, ³UBC MRI Research, Vancouver, BC, Canada

Keywords: White Matter, Spinal Cord

Motivation: Myelin imaging techniques are often qualitative and lack specificity, hindering precise understanding of white matter and neurodegenerative diseases.

Goal(s): This study aimed to enhance myelin imaging by combining Inhomogeneous Magnetization Transfer (ihMT) and Myelin Water Imaging (MWI) at 9.4T.

Approach: Incorporating ihMT saturation pulses with the multi-echo spin-echo MWI readout acquisition facilitates myelin quantification through multi-contrast mechanisms. ihMT images protons with extended dipolar relaxation times, while MWI extracts myelin water contributions from T_2 distributions.

Results: Results revealed irregularities due to high-field-induced shortening of myelin water T_2 values. Therefore, full T_2 distributions could not be resolved, impeding further analyses such as myelin quantification.

Impact: This study presents a myelin-specific imaging approach through the fusion of two quantitative techniques at 9.4T. Unresolved myelin water T_2 peaks caused by the high field strength present a challenge, underscoring the need for further exploration at lower field strengths.

Table 1. APT values of bilateral WM in T2DM patients and healthy controls.

	Healthy Controls	T2DM Patients	t	P
Right WM	1.21	1.14	-0.306	0.361
Left WM	1.09	0.99	-0.617	0.542
Right WM	0.92	0.90	-0.100	0.919
Left WM	0.89	0.86	-0.067	0.948
Right WM	1.03	1.07	0.108	0.917
Left WM	1.02	1.07	0.122	0.907
Right CP	0.97	0.77	-1.248	0.219
Left CP	1.00	0.72	-1.7	0.092

Amide Proton Transfer Magnetic Resonance Imaging of Type 2 Diabetes Mellitus: A Preliminary Study

Hongjun Jiang¹, Shuncheng Yu¹, Langxuan Yu¹, Peng Sun², Liangjie Lin², and Weiwei Wang¹

¹Radiology department, The first affiliated hospital of Dalian medical university, Dalian City, China, ²Clinical & Technical Support, Philips Healthcare (Beijing), China, Beijing, China

Keywords: Other Neurodegeneration, Diabetes, APT T2DM

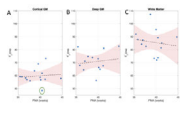
Motivation: APT imaging has been used to study neurodegenerative diseases, T2DM is also known to be associated with cognitive decline and brain structural changes, so, it is interesting to explore the cerebral metabolic alternation of T2DM.

Goal(s): This study investigated the feasibility of APT to monitor the condition of T2DM patients.

Approach: Twenty T2DM patients and Twenty age- and sex-matched healthy controls (HCs) underwent conventional MR and APT scanning. The image analysis of APT was performed by 3D Slicer software.

Results: The results showed that the APT values in the left temporal white matter of T2DM patients were lower and significantly different from healthy controls.

Impact: By APT technique, temporal lobe white matter APT signal values were found to be lower in T2DM patients than in healthy controls, which can provide more information on cerebral metabolic changes in T2DM patients.



Characterisation of brain T₂* Values across the neonatal period at 7 Telsa

Elisabeth Sarah Pickles^{1,2}, Jucha Willers Moore^{3,4}, Philippa Bridgen^{1,2}, Alena Uus³, Jo V Hajnal^{2,3}, Maria DePrez³, Anthony Price^{1,3}, Tomoki Arichi^{1,3,4}, and Shaihan Malik^{2,3}

¹Guy's and St Thomas' NHS Foundation Trust, London, United Kingdom, ²London Collaborative Ultra high field System (LoCUS), London, United Kingdom, ³Centre for the Developing Brain, King's College London, London, United Kingdom, ⁴Centre for Neurodevelopmental Disorders, King's College London, London, United Kingdom

Keywords: Neonatal, Brain, High-field MRI, Neuro, Relaxometry

Motivation: Brain T₂* values can provide information about tissue specific maturation, and can also provide knowledge important for optimising echo times for fMRI acquisition.

Goal(s): To characterise tissue specific T₂* values in the neonatal brain at 7T.

Approach: Whole brain T₂* maps from 14 neonates were generated using a 3D multi-echo acquisition.

Results: Median T₂* values were: cortical grey matter: 58 ms, deep grey matter: 70 ms and white matter: 86 ms. Values differ markedly from those described in adults and measured at standard field strengths.

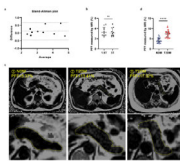
Impact: We describe tissue-specific T₂* values in the neonatal brain at 7T, which may provide new information about brain development in health and disease, and provide a basis for optimising fMRI sequences for neonates at 7T.

Analysis Methods

Exhibition Hall (Hall 403)

Wednesday 9:15 - 10:15

4984



Pancreatic Fat Quantification in Human Diabetes and Its Relationship with β -Cell Reduction

Na Zhang¹, Dingxia Liu², Caixia Fu³, Jiaxin Zhang¹, Ruonan Zhang¹, Ke Hu¹, Yumei Yang¹, Baomin Wang¹, Jing Ma¹, Yi Chen¹, Runyue Yang¹, Xiuzhong Yao², and Xiaomu Li¹

¹Department of Endocrinology and Metabolism, Zhongshan Hospital, Shanghai, China, ²Department of Radiology, Zhongshan Hospital, Shanghai, China, ³Siemens Shenzhen Magnetic Resonance Ltd, Shenzhen, China

Keywords: Radiomics, Endocrine, Data acquisition, diabetes, metabolism, pancreas

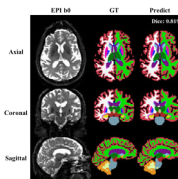
Motivation: Patients with type 2 diabetes have more pancreatic fat, but its impact on β -cells is unclear.

Goal(s): Our goal is to explore the impact of pancreatic fat on β -cells.

Approach: We employed 6-point Dixon MRI to confirm the pancreatic fat fraction (PFF) in patients with type 2 diabetes. Histologic analysis was conducted to validate our findings and immunohistochemical staining was performed to observe changes in β -cells.

Results: We found a negative relationship between β -cell mass and PFF in patients with type 2 diabetes. This suggested that the increased pancreatic fat observed in type 2 diabetes might contribute to reducing the number of β -cells.

Impact: This study provided evidence that increased pancreatic fat in type 2 diabetes was associated with a decreased number of β -cells. These findings suggested targeting pancreatic fat accumulation could be a potential therapeutic approach for improving glycemic control in diabetic patients.



Validation of U-Net models for direct EPI Segmentation of brain MRI: towards faster and accurate diffusion Analysis

Yu-Chen Liao¹, Teng-Yi Huang¹, Jia-Xiu Chen¹, and Jui-Jung Yu¹

¹National Taiwan University of Science and Technology, Taipei City, Taiwan

Keywords: Segmentation, Brain

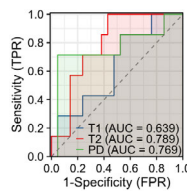
Motivation: Brain sub-region segmentation from MRI scans aids in detailed structural analysis. We attempt to directly segment EPI to simplify diffusion metric analysis, potentially allowing for swift regional analysis of diffusion metrics.

Goal(s): Our primary goal is to develop deep learning U-Net models for EPI segmentation, aiming to circumvent the necessity for T1 images and to simplify the segmentation workflow.

Approach: We collected 3182 datasets from public MRI databases, enhancing ground-truth labels through distortion correction methods.

Results: The ASEG model achieves the highest Dice coefficient (0.709), reducing execution time significantly. Subsequent analyses show ASEG model's diffusion results correlate highly with conventional template registration.

Impact: The results enhanced speed and precision in EPI segmentation, promising substantial advancements in clinical and research domains through rapid acquisition of brain structural information. The anticipated open-source availability of this methodology stands to greatly facilitate clinical research involving regional brain analysis.



Evaluation of pituitary tumor texture using Synthetic MRI

Luqiang Cao¹, Weiyin Vivian Liu², Lin Xu³, Wen Chen³, Yu Zhang⁴, and Zhongyan Xiao⁵

¹Department of Radiology, Taihe Hospital, Hubei University of medicine, Shiyan, Hubei, China, ²GE Healthcare, MR Research, Beijing, China, ³Department of Radiology, Taihe Hospital, Hubei University of Medicine, Shiyan, Hubei, China, ⁴Department of Nuclear Medicine, Taihe Hospital, Hubei University of Medicine, Shiyan, Hubei, China, ⁵Hubei University of Medicine, Shiyan, Hubei, China

Keywords: fMRI Analysis, Quantitative Imaging


Motivation: Surgery selection mainly relies on texture of pituitary adenomas. There is rarely a non-invasive imaging method to identify texture of pituitary adenomas that greatly determines surgical selection and outcomes.

Goal(s): To explore the predictive performance of synthetic MRI in types of pituitary tumors.

Approach: T1, T2 and PD values of every tumor were measured and divided into the solid and soft tumor groups according to the histology results of surgical samples.

Results: Synthetic MRI-computed T2 and PD values were significantly higher in the soft pituitary tumor group than in the solid group ($P < 0.05$) with cutoff values of 110.83 ms and 87.3 p.u., respectively.

Impact: Both T2 and PD value can assist surgeons in determination of surgical treatments (e.g. transsphenoidal resection or craniotomy) and prediction of surgical outcomes, such as resection completeness, indicating synthetic MRI could a strong imaging marker.



Scout and guidance line-based retrospective motion correction for susceptibility-weighted-imaging (SWI).

Jeanette Carmen Deck^{1,2}, Daniel Polak², Daniel Nicolas Splitthoff², Bryan Clifford³, Yan Tu Huang⁴, Wei-Ching Lo³, Susie Y. Huang⁵, John Conklin⁵, Lawrence L. Wald⁶, and Stephen Cauley³

¹Ruprecht-Karls-Universität Heidelberg, Heidelberg, Germany, ²Siemens Healthineers, Erlangen, Germany, ³Siemens Medical Solutions, Boston, MA, United States, ⁴Siemens Shenzhen Magnetic Resonance Ltd., Shenzhen, China, ⁵Massachusetts General Hospital, Boston, MA, United States, ⁶A. A. Martinos Center for Biomedical Imaging, Boston, MA, United States

Keywords: Motion Correction, Motion Correction

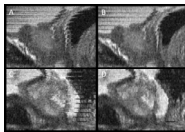
Motivation: Motion artifacts are a common source of artifacts in clinical brain imaging.

Goal(s): To facilitate efficient retrospective motion correction for susceptibility-weighted-imaging (SWI).

Approach: A 2 sec motion-free pre-scan and the repeated acquisition of additional k-space encoding lines (guidance lines) were implemented into an GRE-based SWI. Guidance lines are played as an additional gradient-echo before the imaging echo which retains the original scan efficiency. Scout and guidance lines are then used for very rapid, fully separable motion trajectory estimation and correction.

Results: *In vivo*, reduced motion artifacts and increased image sharpness is demonstrated across several scans with instructed subject motion.

Impact: Scout and guidance-lines based retrospective motion correction is introduced for SWI. Our approach enables efficient motion artifact mitigation while being minimally disruptive to standard clinical protocols and should improve the robustness and reproducibility of clinical brain imaging.



Detection and Correction of Spurious Motion Within Overlapped Multi-Slice Prostate T2-Weighted Acquisitions

Eric A. Borisch¹, Armita Kazemi², Roger C. Grimm¹, Phillip J. Rossman¹, and Stephen J. Riederer¹

¹Radiology, Mayo Clinic, Rochester, MN, United States, ²Century High School, Rochester, MN, United States

Keywords: Motion Correction, Motion Correction

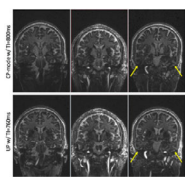
Motivation: Motion frequently impairs T2 weighted prostate imaging; in the multi-pass acquisitions that are common this results in an objectionable stair-step artifact, and can lead to additional scans and increased exam time.

Goal(s): Reduce the impact of motion occurring in a subset of the multi-pass acquisition.

Approach: Automatic detection of motion (through a mutual-information metric) coupled with replacement of corrupted slices via averaging of neighbors. In the described case, adjacent slices are intentionally overlapped, leading to reasonable results from this approach.

Results: Improvements are clearly visible in both motion-controlled phantom and a subset of volunteer examinations.

Impact: The ability to automatically repair a portion of motion-corrupted exams may enable reduction of supplemental / repeat scans, improving overall exam times. The described technique is not computationally complex, and could be performed inline after scan completion.



Assessing the Effect of Universal Pulses on EDGE-MP2RAGE at 7T

Joelle E. Sarlls¹, Gael Saib¹, Franck Mauconduit², Vincent Gras², and S Lalith Talagala¹

¹NINDS, National Institutes of Health, Bethesda, MD, United States, ²CEA, NeuroSpin, Universite Paris-Saclay, Gif-sur-Yvette, France

Keywords: Parallel Imaging, High-Field MRI


Motivation: To optimize an EDGE-MP2RAGE acquisition at 7T for epilepsy studies.

Goal(s): To determine if it is beneficial to use Universal Pulses within EDGE-MP2RAGE at 7T and to find the optimum T11 to produce the best visualization of the gray-white matter boundary.

Approach: Collect EDGE-MP2RAGE data with conventional RF and Universal Pulses and analyze the gray and white matter signal across the brain.

Results: Overall, it does seem to be beneficial to use Universal Pulses within EDGE-MP2RAGE, although it does not produce more consistent gray and white matter signal in all brain regions.

Impact: Utilizing Universal Pulses within EDGE-MP2RAGE with the determined optimum T11=760ms at 7T can improve continuity of the gray-white matter boundary compared to conventional RF pulses, which may allow for detection of focal cortical dysplasia in epilepsy patients.



Diffusion artefact appearance in MRI with ultra-high spatial resolution

Thomas Hufen¹, Fabian Bschorr¹, and Volker Rasche¹

¹Ulm University, Ulm, Germany

Keywords: Artifacts, Artifacts

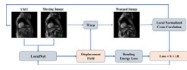
Motivation: Effect of free diffusion introduced image blur is well known but measurable samples always have solid boundaries which results in non-blur like artefacts in ultra-high-resolution images.

Goal(s): Demonstration of diffusion introduced artefact behavior near impermeable barriers.

Approach: A Monte Carlo simulation of particles undergoing a random walk was performed and CTI specific point spread functions (PSFs) and 1D images determined.

Results: It was demonstrated that the PSF yields asymmetric blur and signal enhancement in direct vicinity of the barrier. Simulations clearly indicating the PSF to be dependent on spatial resolution and gradient strength.

Impact: These results will help to prohibit misinterpretation of MR images of small structures with ultra-high-resolution MRI.



Improving the Accuracy of Cardiac T1 Maps with a Deep Learning-Based System: Virtual MOLLI Target and LocalNet

Jui-Jung Yu¹, Nai-Yu Pan¹, Wu Ming-Ting², Teng-Yi Huang¹, Jia-Xiu Chen¹, and Yu-Chen Liao¹

¹Department of Electrical Engineering, National Taiwan University of Science and Technology, Taipei, Taiwan, ²Department of Radiology, Kao-Hsiung Veterans General Hospital, Kao-Hsiung, Taiwan

Keywords: Motion Correction, Motion Correction, MOLLI, registration

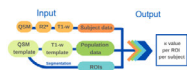Motivation: Accurate cardiac T1 mapping is crucial for diagnosing heart conditions, yet patient motion can cause misaligned images. We aimed to address this with an automatic registration system.

Goal(s): Develop and validate a high-precision automatic registration system for aligning MOLLI cardiac images.

Approach: We created a system that integrates a GAN-generated virtual MOLLI target (VMT) and a deep-learning-based multi-modal registration method (DL) and applied it to a dataset, using the fitting quality index (FQI) for assessment.

Results: Our findings indicate that while all three tested registration methods improved alignment. Our VMT+DL system consistently performed well in datasets with significant motion, while traditional methods faltered.

Impact: The VMT+DL system offers a robust alternative for cardiac T1 mapping in clinical settings, where patient movement can compromise image registration. It ensures the reliability of diagnostic imaging, which is crucial for patient care in cardiology.



A Fully Automated Pipeline for the Determination of the Iron Microstructure Coefficient (IMC) from Multi-Echo GRE Data

Saleha Mir¹, Fahad Salman¹, Dejan Jakimovski¹, Cheryl McGranor², Robert Zivadinov^{1,2}, and Ferdinand Schweser^{1,2}

¹Buffalo Neuroimaging Analysis Center, Department of Neurology, Jacobs School of Medicine and Biomedical Sciences, University at Buffalo, The State University of New York, Buffalo, NY, United States, ²Center for Biomedical Imaging, Clinical and Translational Science Institute, University at Buffalo, The State University of New York, Buffalo, NY, United States

Keywords: Quantitative Imaging, Quantitative Susceptibility mapping

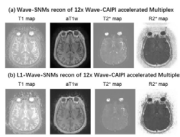
Motivation: This work aims to automate analysis of the newly introduced Iron Microstructure Coefficient (IMC) to facilitate understanding of iron cellular distribution in neurological diseases for large cohort studies.

Goal(s): The goal is to develop and test an automated and widely applicable pipeline for IMC analysis using quantitative susceptibility and R_2^* maps obtained from the same multi-echo GRE sequence.

Approach: The pipeline inputs magnetic susceptibility and R_2^* maps, T1-w data, templates, and regions of interest (ROIs). The output is the IMC value per ROI per subject.

Results: The pipeline successfully executed in 50 minutes without segmentation failure for a cohort of 28 test subjects.

Impact: The automated pipeline accelerates data processing for IMC, providing enhanced standardization in a robust, reproducible, and user-friendly manner. It facilitates large-scale research, driving significant advancements in our understanding of neurological diseases, with the goal of improving accurate diagnosis for patients.



Accelerating multiparametric imaging(MTP) by 12-fold using 64 channel head coil and CS Wave reconstruction

chunlin jiao¹, Sen Jia², Jiaying Zhao³, Jing Cheng², Zhuoxu Cui², Yongquan Ye⁴, Yongquan Ye⁴, Ye Li², Xin Liu², Hairong Zheng², Qiyu Jin¹, and Dong Liang²

¹Inner mongolia university, Hohhot, China, ²Shenzhen Institute of Advanced Technology, Shenzhen, China, ³Shenzhen Institute of Advanced Technology, University of Chinese Academy of Sciences, Beijing, China, ⁴UIH America, Houston, TX, United States

Keywords: Quantitative Imaging, Quantitative Imaging


Motivation: The MULTIPLEX technique could quantify the T1/T2*/PD/Susceptibility maps in a single 3D scan but leads to a long scan time.

Goal(s): This study aimed to develop sparsity regularized Wave-SNMs reconstruction methods to address the issue of slow 3D scanning of the MULTIPLEX technique.

Approach: This work is based on a SNMs reconstruction method with the addition of a sparsity regular term of L1, which utilizes nulling maps with a short calibration time to achieve a 12-fold accelerated imaging.

Results: Sparsity regularized Wave-SNMs reconstruction with Multi-Dimensional Integration quantification accelerate MULTIPLEX by 12-fold into a single scan of 2 minutes.

Impact: The L1 regularized Wave-SNMs reconstruction could benefits the Mutli-Dimensional Integration (MDI) quantification to achieve comparable accuracy and robustness as the reference scan with 70% reduction of scan time.



'Repeat it with me' 2022-23 Reproducibility Team Challenge: Sensitivity Analysis of the Bloch Equations

Ebony R. Gunwhy¹, Jemima H. Pilgrim-Morris¹, Nick Scholand^{2,3}, and Martin Uecker^{2,3}

¹Division of Clinical Medicine, School of Medicine and Population Health, University of Sheffield, Sheffield, United Kingdom, ²Institute of Biomedical Imaging, Graz University of Technology, Graz, Austria, ³German Centre for Cardiovascular Research, Göttingen, Germany

Keywords: Quantitative Imaging, Validation, Reproducibility, model-based reconstruction, sensitivity analysis, state-transition matrix, nonlinear inversion, Bloch equations, quantitative MRI

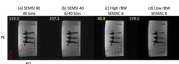
Motivation: Inverse problems in MRI require estimation of the Bloch equation partial derivatives, however robust computation is challenging. Sensitivity analysis offers accurate and numerically stable derivatives to overcome this.

Goal(s): To replicate and validate previous work, and examine functionality of the BART toolbox and use of collaborative platforms such as GitHub for reproducing research.

Approach: A direct replication was attempted following methodology from a previous ISMRM abstract, and an accompanying preprint and GitHub repository.

Results: Both replicators successfully recreated all abstract figures. Replication of difference quotient and sensitivity analysis derivatives was achieved within the predefined normalised root mean square error tolerances.

Impact: Successful replication further validates novel work in computing partial derivatives of the Bloch Equations. Collaborative platforms such as GitHub can improve existing software and resources when reproducing research. This enables wider dissemination, enhancing ease-of-use for other researchers in future applications.



Towards Practical SEMSI at 0.55 Tesla

Bochao Li¹, Kübra Keskin², Sophia Cui³, Brian A. Hargreaves⁴, and Krishna S. Nayak^{1,2}

¹Department of Biomedical Engineering, University of Southern California, Los Angeles, CA, United States, ²Department of Electrical and Computer Engineering, University of Southern California, Los Angeles, CA, United States, ³Siemens Healthcare USA, Los Angeles, CA, United States, ⁴Department of Radiology, Stanford University, Stanford, CA, United States

Keywords: Artifacts, Low-Field MRI


Motivation: Spectrally-encoded multi-spectral imaging (SEMSI) is an approach for distortion-free MRI around metallic implants, but requires multiple-readouts per TR to be clinically feasible.

Goal(s): To determine the benefits of SEMSI over SEMAC at 0.55T, using parameters that are consistent with a future multi-readout SEMSI implementation.

Approach: We used single-readout SEMSI to prospectively mimic the performance of multi-readout SEMSI with high slew rate and readout bandwidth.

Results: We observe that SEMSI simultaneously achieves the expected SNR improvement and artifacts reduction compared to SEMAC.

Impact: SNR improvement is important at 0.55T to examine the tissues near the metallic implants. This prospective study confirms the improvement performance of multi-readout SEMSI which will further improve SNR and scan efficiency.



Multi-center, multi-vendor validation of PDFFF and T1 mapping in an optimized PDFFF-T1 phantom

Jitka Starekova¹, Sebastian Weingartner², David Rutkowski³, Won Bae⁴, Hung Do⁵, Ananth Madhuranthakam⁶, Vadim Malis⁴, Sujoy Mukherjee⁶, Sheng Qing Lin⁶, Suraj Serai⁷, Takeshi Yokoo⁶, Scott B. Reeder^{1,8,9,10,11}, Jean H. Brittain³, and Diego Hernando^{1,8}

¹Radiology, University of Wisconsin-Madison, Madison, WI, United States, ²Imaging Physics, Delft University of Technology, Delft, Netherlands, ³Calimetrix, Madison, WI, United States, ⁴University of California, San Diego, San Diego, CA, United States, ⁵Canon Medical Systems, Tustin, CA, United States, ⁶Radiology, University of Texas-Southwestern Medical Center, Dallas, TX, United States, ⁷Radiology, Children's Hospital of Philadelphia, Philadelphia, PA, United States, ⁸Medical Physics, University of Wisconsin-Madison, Madison, WI, United States, ⁹Biomedical Engineering, University of Wisconsin-Madison, Madison, WI, United States, ¹⁰Medicine, University of Wisconsin-Madison, Madison, WI, United States, ¹¹Emergency Medicine, University of Wisconsin-Madison, Madison, WI, United States

Keywords: Quantitative Imaging, Precision & Accuracy, Phantoms, PDFFF, T1, Multi-center, Multi-vendor

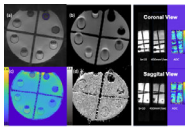
Motivation: Chemical-shift-encoded (CSE)-based proton-density fat-fraction (PDFFF) is a highly validated biomarker of liver fat. T1 mapping has been proposed as a biomarker of hepatic fibrosis. However, the reproducibility of PDFFF and T1 in the setting of concomitantly varying fat and T1 is poorly understood.

Goal(s): To validate the reproducibility of CSE-based PDFFF and MOLLI-based T1 mapping with concomitantly varying fat and T1.

Approach: We conducted a four-center, four-vendor validation study using a quantitative PDFFF-T1 phantom.

Results: CSE-based PDFFF had good reproducibility, although with increased bias and variability at long T1 values. The reproducibility of MOLLI-based T1 was affected substantially by the presence of fat.

Impact: CSE-based PDFFF demonstrated good reproducibility across four centers/vendors, at both 1.5T and 3T. Increased T1 and increased PDFFF led to reduced MOLLI-based T1 reproducibility. This multi-center multi-vendor PDFFF-T1 phantom validation approach may enable evaluation of improved quantitative MRI methods.



Advancing 3D DWI Imaging with the 3D Radial-EPI(RAZER) Trajectory.

Seong-Eun Kim¹, Henrick Carl Axel Odeen¹, Micheal Micheal Malmberg¹, and Dennis L Parker¹

¹UCAIR, Department of Radiology and Imaging Sciences, University of Utah, Salt Lake City, UT, United States

Keywords: Pulse Sequence Design, Atherosclerosis, 3D DWI


Motivation: Non-Cartesian sampling offers advantages in motion robustness and speed, crucial in 3D DWI.

Goal(s): We aimed to improve 3D DWI using RAZER trajectory to improve the 3D DWI imaging with reducing scan time while preserving imaging quality.

Approach: We implemented 3D DW RAZER sequence with integrated radial and EPI sampling and conducted 3D DWI studies in a phantom and human carotid arteries.

Results: The RAZER DWI sequence offered a clearer depiction of the carotid arterial structure and reliable ADC measurements without geometric distortion when compared to 2D ss-DW EPI, all within a scan time of less than two minutes.

Impact: This study introduces a motion-robust 3D DWI with faster imaging capabilities, potentially improving vulnerable plaque identification. It addresses conventional DWI limitations, providing a valuable resource for the detection of possible events and improved patient outcomes in ischemic stroke.



Quiet Fat-suppressed T1-weighted MRI by Dual-IR PETRA

Yulin Wang¹, Jie Zeng¹, Jichang Zhang², Yuliang Zhu¹, Shiyong Ke¹, Shengyang Niu¹, Lili Lin¹, Chendie Yao¹, and Chengbo Wang^{1,3}

¹Faculty of Science and Engineering, University of Nottingham Ningbo China, Ningbo, China, ²Xingaoyi Medical Equipment Co. Ltd, Ningbo, China, ³Nottingham Ningbo China Beacons of Excellence Research and Innovation Institute, Ningbo, China

Keywords: Pulse Sequence Design, Brain

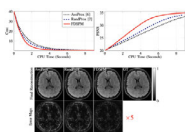
Motivation: MRI produces considerable acoustic noise. PETRA sequence can solve this problem but has limited contrast.

Goal(s): This study improves PETRA sequence by magnetization preparation to achieve widely used T1-weighted imaging with fat suppression and sound reduction.

Approach: Double asymmetric adiabatic RF pulses are designed to invert aqueous tissues for T1-weighted contrast creation and invert lipidic tissues for fat suppression and combined with PETRA gradient trajectories.

Results: The brain and knee experiments are conducted to verify the feasibility of the proposed sequence. The fat is decreased by above 70%. The gray-to-white matter contrast and knee cartilage visualization are enhanced compared with non-prepared PETRA sequence.

Impact: The significantly reduced SPL of 67.4 dBA using limited gradient switching, providing better patient scanning comfort, can promote its acceptance to pediatric imaging. The double RF preparation design improves the limited contrast of PETRA.



A Fast Double Stochastic Proximal Method for CS-MRI Reconstruction with Multiple Wavelets

Tao Hong¹, Luis Hernandez-Garcia¹, and Jeffrey Fessler²

¹Department of Radiology, University of Michigan, Ann Arbor, Ann Arbor, MI, United States, ²Department of Electrical and Computer Engineering, University of Michigan, Ann Arbor, Ann Arbor, MI, United States

Keywords: Image Reconstruction, Sparse & Low-Rank Models

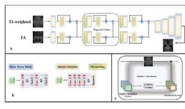
Motivation: Gu et al. [3] showed one can obtain comparable performance as the physics-guided deep learning (PG-DL) networks [4] for CS-MRI reconstruction by using multiple wavelets as the regularizers.

Goal(s): Develop an efficient numerical algorithm for CS-MRI reconstruction with multiple wavelets.

Approach: Study a fast double stochastic proximal method (FDSPM) for compressed sensing MRI (CS-MRI) reconstruction.

Results: Our experiments demonstrate that FDSPM converges in less CPU time than classical CS algorithms for image reconstruction.

Impact: Exploring efficient algorithms for multiple regularizers CS-MRI reconstruction can motivate new efficient network structures that are easy to train.



ASN: Adaptive Segmentation Network for Visual Pathway Identification in Multi-parametric MR Images

Alou Diakite^{1,2}, Cheng Li¹, Lei Xie³, Yuanjing Feng³, Hua Han¹, Hairong Zheng¹, and Shanshan Wang^{1,4,5}

¹Paul C Lauterbur Research Center for Biomedical Imaging, Shenzhen Institute of Advanced Technology, Chinese Academy of Sciences, Shenzhen, China, ²University of Chinese Academy of Science, Beijing, China, ³Zhejiang University of Technology, Hangzhou, China, ⁴Guangdong Provincial Key Laboratory of Artificial Intelligence in Medical Image Analysis and Application, Guangzhou, China, ⁵Peng Cheng Laboratory, Shenzhen, China

Keywords: Machine Learning/Artificial Intelligence, Visualization, Adaptive convolution, visual pathway segmentation, deep learning

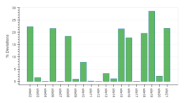Motivation: Accurate visual pathway (VP) segmentation is critical for clinical diagnosis and surgical planning. Current deep learning-based methods struggle to capture significant context information, impacting the segmentation precision.

Goal(s): Improve multi-parametric MRI-based VP segmentation by designing an Adaptive Segmentation Network (ASN).

Approach: ASN uses adaptive convolution (AC) to dynamically adjust the kernel based on complementary context, facilitating the integration of contextual information. A spatial attention block selectively extracts relevant regions' features in each MRI sequence and fuses them.

Results: ASN's effectiveness is validated by segmenting the VP in MR images from two MRI sequences. It surpasses state-of-the-art techniques in VP segmentation.

Impact: The introduction of ASN, a new multi-parametric MR images segmentation approach, demonstrates superior performance in visual pathway (VP) segmentation in MR images, surpassing existing state-of-the-art techniques. This novel method effectively incorporates context information, leading to improved segmentation performance.



Digging deeper into the pervasive problem of non-compliance in MR datasets

Harsh Sinha¹ and Pradeep Reddy Raamana¹

¹University of Pittsburgh, Pittsburgh, PA, United States

Keywords: Data Acquisition, Software Tools, Protocol Compliance

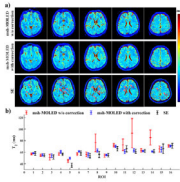
Motivation: Large MRI datasets from multiple sites are not monitored for protocol compliance and dataset integrity.

Goal(s): We previously demonstrated the pervasiveness of protocol non-compliance in MR datasets using our open source tool mrQA. We aim to produce deeper insights with vertical audit and analyze the common patterns of non-compliance.

Approach: We processed the large and open ABCD study verifying relationships between sequences in their protocol.

Results: We observed issues on non-compliance in coil, shim setting, and pixel spacing. We also observed significant disparities across vendors, scanners and sites. This underscores the necessity for tools such as mrQA that can identify non-compliance across vendors/sites.

Impact: Non-compliance in acquisition parameters is a pervasive problem in MR datasets. It is impractical to "hope" for protocol compliance across sites, and scanners. Our tool, mrQA can enable researchers to continuously monitor and identify non-compliant scans in a practical manner.



Deep-learning-based flow-artifact correction for multi-shot multiple overlapping-echo detachment imaging (msh-MOLED)

Ying Lin¹, Qizhi Yang¹, Ming Ye¹, Jianfeng Bao², Zhong Chen¹, Liangjie Lin³, Congbo Cai¹, and Shuhui Cai¹

¹Xiamen University, Xiamen, China, ²Department of Magnetic Resonance Imaging, the First Affiliated Hospital of Zhengzhou University, Zhengzhou, China, ³MSC Clinical & Technical Solutions, Philips Healthcare, Shenzhen, China

Keywords: Artifacts, Data Acquisition, Image Reconstruction


Motivation: Multi-shot overlapping-echo detachment imaging (msh-MOLED), a msh-EPI-based quantitative MR sequence, quantifies tissue T_2 rapidly without the need of separately acquiring images with different TEs, but its results could be contaminated by flow-induced inter-shot phase variations.

Goal(s): To implement an instantaneous referenceless flow-artifact correction for msh-MOLED.

Approach: Flow-related features were added to the training data, and the trained network fulfilled T_2 mapping free from flow artifacts without dear computational costs or additional reference data.

Results: After correction, the Pearson's correlation coefficient/mean absolute error was changed from 0.6332/6.5328 (uncorrected) to 0.8808/2.7623 (corrected).

Impact: The proposed correction could be used to retain the mapping accuracy of msh-MOLED regardless of shot numbers, or to refine the reference data in high-spatial-resolution diffusion mapping potentially.



Quality assessment of MR images: Does deep learning outperform machine learning with handcrafted features on new sites?

Prabhjot Kaur¹, John S Thornton^{2,3}, Frederik Barkhof^{1,2,4}, Tarek A. Yousry^{2,5}, Sjoerd Vos^{1,2,6}, and Hui Zhang¹

¹Centre for Medical Image Computing and Department of Computer Science, University College London, London, United Kingdom, ²Neuroradiological Academic Unit, UCL Queen Square Institute of Neurology, University College London, London, United Kingdom, ³Queen Square Centre for Neuromuscular Diseases, Department of Neuromuscular Diseases, UCL Queen Square Institute of Neurology, London, London, United Kingdom, ⁴Radiology & Nuclear Medicine, VU University Medical Center, Amsterdam, Netherlands, ⁵Queen Square Centre for Neuromuscular Diseases, Department of Neuromuscular Diseases, UCL Queen Square Institute of Neurology, London, United Kingdom, ⁶Centre for Microscopy, Characterisation, and Analysis, The University of Western Australia, Nedlands, Australia

Keywords: Artifacts, Brain, Quality, Deep learning, Quality Assessment


Motivation: Deep learning (DL) outperforms conventional machine learning (ML) that relies on handcrafted feature-based in many vision tasks, but its superiority in assessing brain MRI image quality for new sites/scanners is unclear.

Goal(s): Compare DL and conventional ML for quality assessment of brain MRI images from new sites/scanners.

Approach: One popular and widely accepted DL and one conventional ML method are evaluated on a multi-site dataset using leave-one-site-out approach using a binary quality label (good/bad).

Results: Averaged balanced accuracy (BA) for the DL and conventional ML approaches are comparably poor (0.60±0.12 and 0.54±0.12, respectively) and does not exceed 0.76, suggesting room for improvement.

Impact: Widespread adoption of automated quality assessment of brain MRI images is limited by a lack of generalizability. By comparing popular DL and conventional ML approaches, we find comparable but limited generalizability. This underscores the need for future algorithm development.



Susceptibility anisotropy imaging from single-orientation MRI with a training-free physics-informed autoencoder

Thomas Jochmann^{1,2}, Ahmad Omira¹, Niklas Kügler¹, Robert Zivadinov^{2,3}, Jens Hauelsen¹, and Ferdinand Schweser^{2,3}

¹Department of Computer Science and Automation, Technische Universität Ilmenau, Ilmenau, Germany, ²Buffalo Neuroimaging Analysis Center, Department of Neurology at the Jacobs School of Medicine and Biomedical Sciences, University at Buffalo, The State University of New York, Buffalo, NY, United States, ³Center for Biomedical Imaging, Clinical and Translational Science Institute, University at Buffalo, The State University of New York, Buffalo, NY, United States

Keywords: Quantitative Imaging, Quantitative Susceptibility mapping, Susceptibility Tensor Imaging

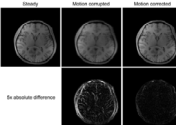
Motivation: To overcome the clinical limitations of susceptibility tensor imaging (STI) due to the requirement for multiple head orientations.

Goal(s): Develop a method to isolate χ_{13} and χ_{23} of the magnetic susceptibility tensor, from a single head orientation, enhancing the clinical viability of STI.

Approach: Employing a deep learning-based autoencoder, calibrated via STI and optimized for each dataset to separate the tensor components without the need for training or data rotation.

Results: The method successfully extracted χ_{13} and χ_{23} components comparable to the gold standard multi-orientation STI, showing potential for improved brain tissue characterization in conditions like multiple sclerosis.

Impact: We present a simplified STI approach, extracting critical tensor components from a single orientation scan. The new technique allows to assess structural tissue integrity, particularly in white matter. Requiring only a single orientation renders it clinically feasible.



Fast and Generalized Motion Correction in Brain MRI using 3D Radial Trajectory and Projection Moment Analysis

Bowen Li¹ and Huajun She¹

¹School of Biomedical Engineering, Shanghai Jiao Tong University, Shanghai, China

Keywords: Motion Correction, Motion Correction, 3D radial, projection moment, center-of-mass

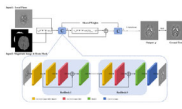
Motivation: Traditional projection moment analysis in 3D radial MRI failed to get specific rigid-body motion parameters with stationary multichannel coils.

Goal(s): Our goal was to develop a method to extract rigid-body motion parameters directly through projection moment analysis.

Approach: A PCA-based coil compression, together with projection information from different channels were used to estimate rigid-body motion parameters. A recursive least-squares model was used to recursively estimate motion parameters for every single spoke. Simulation and scanning of moving object were performed to demonstrate its capability in brain scan.

Results: The proposed method can correct motion in brain successfully and quickly.

Impact: The proposed method provides an easy, robust, and time-efficient tool for motion correction in brain MRI, which may benefit clinical diagnosis of uncooperative patients like children, in addition to many other applications including extremity MRI.



Nonlinear Susceptibility Inversion Deep Learning Model for Robust Quantitative Susceptibility Mapping

Hongyu Guo^{1,2} and Zheng Zhang¹

¹College of Electrical Engineering, Shenyang University of Technology, Shenyang, China, ²Neusoft Medical System, Shanghai, China

Keywords: Quantitative Imaging, Quantitative Susceptibility mapping, Susceptibility Inversion, Deep Learning

Motivation: Quantitative susceptibility mapping (QSM) estimates the spatial distribution of tissue susceptibility by solving a challenging ill-posed dipole inversion problem, which heavily affects the accuracy of tissue susceptibility quantification.

Goal(s): To generate high-quality QSM images.

Approach: In this study, we present a deep learning method for susceptibility inversion that utilizes a nonlinear susceptibility inversion model, NSIDL. Our approach integrated the Proximal Gradient Descent (PGD)^[1] algorithm and embedding the physical model in the network.

Results: NSIDL was compared to traditional and deep learning methods, and it was found that NSIDL can effectively suppress streaking artifacts, mitigate noise amplification, and prevent excessive smoothing.

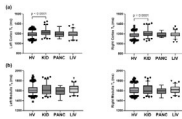
Impact: This study introduced the NSIDL deep learning method, which improved the accuracy of tissue magnetic sensitivity quantification. The improvement of QSM performance can help clinical doctors make more informed decisions based on reliable sensitivity measurements.

Image Processing & Analysis: Body Applications

Exhibition Hall (Hall 403)

Wednesday 14:30 - 15:30

5007



Automated analysis of the UK Biobank MRI data for the assessment of multi-organ involvement in disease

Eleanor F Cox^{1,2}, Zhendi Gong³, Martin Craig^{1,2}, Ali-Reza Mohammadi-Nejad^{1,2,4}, Guruprasad Padur Aithal^{2,5}, Iain D Stewart⁶, Louise V Wain^{7,8}, Gisli Jenkins⁶, Dorothee P Auer^{1,2,4}, Stamatios N Sotiropoulos^{1,2,4}, Xin Chen^{2,3}, Susan T Francis^{1,2}, and The DEMISTIFI Consortium⁹

¹Sir Peter Mansfield Imaging Centre, University of Nottingham, Nottingham, United Kingdom, ²NIHR Nottingham Biomedical Research Centre, Nottingham University Hospitals NHS Trust and the University of Nottingham, Nottingham, United Kingdom, ³School of Computer Science, University of Nottingham, Nottingham, United Kingdom, ⁴Mental Health and Clinical Neurosciences, School of Medicine, University of Nottingham, Nottingham, United Kingdom, ⁵Nottingham Digestive Diseases Centre, Translational Medical Sciences, School of Medicine, University of Nottingham, Nottingham, United Kingdom, ⁶National Heart & Lung Institute, Faculty of Medicine, Imperial College London, London, United Kingdom, ⁷Department of Population Health Sciences, University of Leicester, Leicester, United Kingdom, ⁸NIHR Leicester Respiratory Biomedical Research Centre, Glenfield Hospital, Leicester, United Kingdom, ⁹Lead Research Organisation: Imperial College London, London, United Kingdom

Keywords: Kidney, Kidney


Motivation: To understand organ changes in multimorbidity (fibrosis in two or more organs).

Goal(s): To use the MRI data in the UK Biobank (UKBB) to study multi-organ changes.

Approach: An automated pipeline to analyse the UKBB kidney MRI data, including deep learning for kidney cortex and medulla segmentation from T₁ maps, alongside segmentation of the liver, spleen and pancreas to assess their T₁. Analysis of 500 healthy volunteers and 235 participants with kidney, pancreas and liver disease.

Results: Multi-organ changes in addition to the primary diseased organ. For example, elevation in cortical T₁ in kidney disease together with increased pancreatic and liver T₁.

Impact: The automated multi-organ analysis of abdominal MRI data to study multi-organ fibrosis. In the future, this will allow investigations related to the epidemiology, risk factors (genetic and environmental) and natural history of fibrotic multimorbidity.



Use of distortion correction combined with deep learning reconstruction in DWI: how does image quality compare to conventional acquisition?

Alessandro M Scotti¹, Michael Vinsky², Thomas Schrack³, Arnaud Guidon⁴, and Melany Atkins³

¹GE HealthCare, Blacklick, OH, United States, ²GE HealthCare, Washington, DC, United States, ³Fairfax Radiological Consultants, Fairfax, VA, United States, ⁴GE HealthCare, Boston, MA, United States

Keywords: Prostate, Machine Learning/Artificial Intelligence

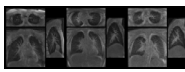
Motivation: The use of deep learning reconstruction, combined with Multiplexed Sensitivity Encoding (MUSE), can extend the benefit of distortion robustness in prostate DWI to poor SNR conditions while maintaining a large spatial matrix.

Goal(s): The purpose of this study is to evaluate the quantitative image quality improvement provided by combining MUSE and DLR in DWI of the prostate.

Approach: Quantitative analysis including SNR, CNR and ADC were compared through ROI analysis of MUSE DWI with conventional and DL reconstruction in 50 prostatic cancer patients.

Results: DLR images demonstrated a significantly higher SNR and CNR. ADC values were consistent among methods.

Impact: Deep learning reconstruction in combination with MUSE can be exploited for better prostate DWI image quality in cases of low SNR, or traded for increased resolution or reduced scan time.



3D MR spirometry in healthy volunteers at 1.5 T using a UTE sequence with a flexible k-space sampling pattern

Anna Reitmann^{1,2}, Aurélien Massire², Franck Mauconduit³, Nathalie Barrau¹, Adrien Duwat¹, Anne-Laure Brun⁴, François Mellot⁴, Alexandre Vignaud³, Philippe Ciuciu⁵, Philippe Grenier⁴, and Xavier Maitre¹

¹Université Paris-Saclay, CEA, CNRS, Inserm, BioMaps, Orsay, France, ²Siemens Healthcare SAS, Courbevoie, France, ³Université Paris-Saclay, CEA, CNRS, BAOBAB, NeuroSpin, Gif-sur-Yvette, France, ⁴Department of Radiology, Foch Hospital, Suresnes, France, ⁵Université Paris-Saclay, CEA, CNRS, Inria, MIND, NeuroSpin, Gif-sur-Yvette, France

Keywords: Lung, Lung, Acquisition Methods, Biomarkers, New Trajectories & Spatial Encoding Methods

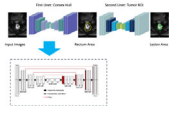
Motivation: To study lung function using 3D MR spirometry.

Goal(s): To optimize 3D dynamic lung MRI with flexible k-space sampling for UTE acquisition.

Approach: A non-Cartesian UTE sequence is developed to execute arbitrary trajectories stored in a readily available external gradient file library. 3D MR spirometry was then performed on freely-breathing healthy volunteers at 1.5 T.

Results: High-quality 4D lung images are obtained, enabling the extraction of relevant respiratory biomarkers. Image quality can then be optimized by directly playing back the shapes and durations of the readout gradients from the files.

Impact: A non-Cartesian, center-out MR sequence that allows out-of-the-box UTE capabilities with flexible k-space trajectories is developed. The result is high-quality 4D lung imaging in free-breathing and supine conditions. The lung functional biomarkers are expected to be sensitive to pathology.



Deep Learning Based Rectal Tumor Localization and Segmentation on Multi-parametric MRI

Yang Zhang^{1,2}, Liming Shi³, Xiaonan Sun³, Ning Yue⁴, Min-Ying Su², and Ke Nie⁴

¹Radiation Oncology, University of California, Irvine, CA, United States, ²Radiological Sciences, University of California, Irvine, CA, United States, ³Radiation Oncology, Sir Run Run Shaw Hospital, Zhejiang University School of Medicine, Hangzhou, China, ⁴Radiation Oncology, Rutgers-The State University of New Jersey, New Brunswick, NJ, United States

Keywords: Cancer, Cancer

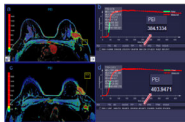
Motivation: The study is motivated by need to improve rectal cancer treatment planning through deep-learning-based analysis of multiparametric MRI, replacing inconsistent and labor-intensive manual tumor delineation.

Goal(s): The study aims to develop a deep-learning algorithm for automated rectal cancer segmentation in MRI images to improve treatment response predictions.

Approach: A two-tiered U-net architecture with attention gates, optimized through cross-validation, was applied to multi-parametric MRI data from 198 patients.

Results: This approach outperformed existing models, with the highest accuracy achieved by combining different MRI sequences. The results indicate that incorporating functional MRI data with anatomical imaging significantly enhances tumor delineation, potentially informing personalized treatment strategies.

Impact: This deep-learning model significantly improves rectal cancer MRI segmentation, offering a path to more accurate and personalized treatment strategies, potentially leading to better patient outcomes and streamlined workflows in oncological imaging and radiation therapy planning.



Ultrafast breast MRI for predicting lymph node metastases in breast cancers

Yang Li¹, Haifa Liu¹, Qi Wang¹, Qian Xu¹, Mengzhu Wang², Robert Grimm³, and Mingwei Qi¹

¹The Fourth Affiliated Hospital of Hebei Medical University, Shijiazhuang, China, ²MR Research Collaboration, Siemens Healthineers Ltd, Beijing, China, ³MR Application Predevelopment, Siemens Healthineers AG, Erlangen, Germany

Keywords: Breast, Breast, breast tumor; dynamic contrast-enhanced magnetic resonance imaging (DCE-MRI); Ultrafast Breast MRI


Motivation: Studies of ultrafast dynamic contrast-enhanced (DCE)-MRI were previously focused primarily on differentiating between benign and malignant breast tumors, with little research on lymph node metastases.

Goal(s): We searched for noninvasive biomarkers to predict lymph node metastases in patients with breast cancer using ultrafast DCE-MRI.

Approach: Ultrafast DCE-MRI was performed using a GRASP sequence, and the proprietary kinetic indicators were calculated to quantitatively diagnose lymph node metastases.

Results: The relative peak enhancement of patients with lymph node metastasis was significantly higher than that of those without metastasis (area under the curve: 0.671)

Impact: In this feasibility study, we preliminarily explored the role of ultrafast breast MRI in diagnosing lymph node metastasis in patients with infiltrating ductal carcinoma. We found that relative peak enhancement can be used to predict lymph node metastasis.



Evaluation of AI Based Reconstruction to Improve image Quality of T2w Images of the Breast

Christopher M Walker¹, Megha Madhukar Kapoor², Ray Cody Mayo III², Jia Sun³, R Jason Stafford¹, and Huong T Le-Petros²

¹Imaging Physics, MD Anderson Cancer Center, Houston, TX, United States, ²Breast Imaging, MD Anderson Cancer Center, Houston, TX, United States, ³Biostatistics, MD Anderson Cancer Center, Houston, TX, United States

Keywords: Breast, Breast

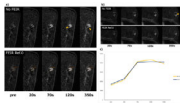
Motivation: Breast MRI has exceptional sensitivity but is limited by image quality and several artifacts. Advancements in AI-based reconstruction hold promise for improved image quality and efficiency.

Goal(s): This study assesses the impact of applying a vendor AI-based reconstruction on breast MRI at 3T.

Approach: This study retroactively reconstructed 45 series using a commercially available AI-based reconstruction. Three board-certified radiologists scored traditional and reconstructed sequences for quality and improvement.

Results: AI reconstruction showed more conspicuous margins as well as an enhanced noise texture. 54 cases showed improvement, 63 showed no change, and 15 exhibited degraded quality. Higher-quality exams were associated with the greatest improvement.

Impact: A retrospective analysis of a recent FDA approved AI based reconstruction method to improve MRI image quality for breast studies.



Improvement of motion-related misalignments in dynamic contrast-enhanced breast MRI using advanced 3D fast elastic image registration

Mana Kato¹, Masami Yoneyama², Michinobu Nagao³, Yasutomo Katumata², Javier Sánchez-González⁴, Jaladhar Neelavalli⁵, Johannes M Peeters⁶, Sven Kabus⁷, Kazuo Kodaira¹, Takumi Ogawa¹, Yutaka Hamatani¹, Isao Shiina¹, Yasuhiro Goto¹, Yasuyuki Morita¹, and Shuji Sakai³

¹Department of Radiological Services, Tokyo Women's Medical University, Tokyo, Japan, ²Philips Japan, Tokyo, Japan, ³Department of Diagnostic Imaging and Nuclear Medicine, Tokyo Women's Medical University, Tokyo, Japan, ⁴Philips Healthcare Iberia, Madrid, Spain, ⁵Philips India, Bangalore, India, ⁶Philips Healthcare, Best, Netherlands, ⁷Philips Research, Humburg, Germany

Keywords: Breast, Breast

Motivation: Motion and breathing artifacts in DCE breast MRI can cause misalignment among each dynamic, resulting in inaccurate tumor assessment.

Goal(s): Our goal was to demonstrate the feasibility of advanced fast elastic image registration (FEIR) for correction of misalignment in breast DCE MRI.

Approach: FEIR was applied and evaluated in 11 patients who underwent breast DCE examinations.

Results: Advanced FEIR clearly improved misalignments among dynamic scans and provided improved accuracy of time intensity curves (TICs).

Impact: FEIR improves motion related misalignments among respective dynamic scans in DCE breast MRI, it could improve the TICs more accurately.

Multiplexed sensitivity-encoding (MUSE) DWI with deep learning-based reconstruction in breast MR imaging: A comparison with conventional DWI

Yitian Xiao¹, Fan Yang¹, Jiayu Sun¹, Bo Zhang², and Huilou Liang²

¹West China Hospital of Sichuan University, Chengdu, China, ²GE HealthCare MR Research, Beijing, China

Keywords: Breast, Diffusion/other diffusion imaging techniques

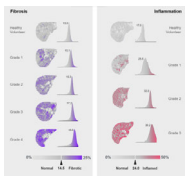
Motivation: Conventional DWI has limitations due to low spatial resolution and geometry distortion. Multiplexed sensitivity-encoding (MUSE) DWI can obtain images with higher resolution and less distortion but require longer acquisition time.

Goal(s): Our aim was to apply deep-learning based reconstruction (DLR) in MUSE DWI for breast imaging, and to investigate if DLR can shorten the scan time while maintaining image quality of MUSE.

Approach: We compared quantitative parameters and subjective image quality of MUSE, MUSE-DLR, and conventional DWI.

Results: MUSE-DLR showed improved image quality than MUSE with slightly longer acquisition time compared to conventional DWI.

Impact: MUSE DWI with deep-learning based reconstruction can enhance the accuracy of clinical breast imaging while maintaining an acceptable scanning time, and also has the potential to improve diffusion imaging in other parts of the human body.



LiverMap®: the choice for screening the onset and progression of chronic liver conditions

Wanida Chua-anusorn¹, Hilton Leao Filho², and Paul Clark³

¹Body Digital Pte Ltd, Singapore, Singapore, ²Institute of Radiology - Abdominal Imaging, University of Sao Paulo, Sao Paulo, Brazil, ³MRI Studio Pty Ltd, Perth, Australia

Keywords: Liver, Liver


Motivation: MRI methods for screening onset of fatty liver disease are lacking owing to the inability to isolate the earliest grades of inflammation, ballooning and fibrosis.

Goal(s): To demonstrate the validity and reproducibility of liver multi-component relaxometry (LiverMap®) in screening onset of liver pathologies at both 1.5T and 3.0T.

Approach: Patient cohorts comprised a validation cohort with 106 biopsy-proven MASLD patients and 16 healthy volunteers, and a reproducibility cohort of 30 volunteers with and without MASLD.

Results: LiverMap® distinguished the onset of liver pathologies with AUROCs above 0.94, a repeatability CoV of 1.7%, and a reproducibility CoV of 3.5%.

Impact: LiverMap® is a new approach to screen and monitor progression of chronic liver conditions in ~10 minutes scan time. In metabolic associated steatohepatitis, LiverMap® reliably distinguishes the onset of five key liver pathologies - fat, iron, inflammation, ballooning and fibrosis.



Predictive value of Intravoxel incoherent motion diffusion-weighted MR imaging in different expression states of HER2 in breast cancer

Siqi Zhao¹, Lina Zhang¹, Yuanfei Li¹, Yueqi Wu¹, Ning Ning¹, Hongbing Liang¹, Lizhi Xie², Haonan Guan², Qingwei Song¹, and Ailian Liu¹

¹First Affiliated Hospital of Dalian Medical University, Dalian, China, ²GE Healthcare, MR Research China, Beijing, China

Keywords: fMRI Analysis, Breast, Breast cancer;HER2;IVIM

Motivation: This study aimed to predict HER2 expression states in breast cancer patients using IVIM imaging, offering valuable guidance for anti-HER2 treatment.

Goal(s): To categorize patients into HER2-positive, HER2-low, and HER2-zero groups, analyze IVIM parameters, and assess their relationship with clinicopathological features.

Approach: 67 breast cancer patients were retrospectively analyzed, with IVIM imaging and data collection. Statistical tests were employed to compare the groups.


Results: While no significant differences emerged in clinicopathological features, ADC_{fast} values differed significantly. Both HER2-positive and HER2-low subgroups exhibited higher ADC_{fast} values than HER2-zero cases. ADC, ADC_{slow}, and f showed no significant variations.

Impact: This study demonstrates that ADC_{fast} can predict HER2 expression noninvasively, assisting in personalized treatment planning and prognosis assessment for breast cancer patients pre-surgery, providing valuable insights for clinical decision-making.

All You Want To Know About Psychiatry with MRI

Exhibition Hall (Hall 403)

Wednesday 14:30 - 15:30



Multimodal MR identifies the prefrontal cortex as central hub of stress-induced brain alterations in rats

Carl-Lennart Junker¹, Jonathan Reinwald¹, Alexander Sartorius¹, and Wolfgang Weber-Fahr¹

¹RG Translational Imaging, Central Institute of Mental Health, Medical Faculty Mannheim, University of Heidelberg, Mannheim, Germany

Keywords: Psychiatric Disorders, Preclinical

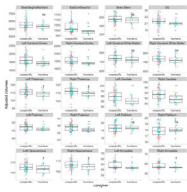
Motivation: Chronic unpredictable mild stress (CUMS) is utilized to model depression-like symptoms in rodents. Although the prevalence of depression is twice as high in women, 97% of CUMS studies focused on male animals.

Goal(s): We aimed to comprehensively phenotype the effect of CUMS in female rats using MRI.

Approach: Thus, we assessed a CUMS-induced depression-like phenotype with various behavioral tests and multimodal MRI specifically in females.

Results: We found prominent prefrontal and striatal volume loss, together with prefrontal glutamate reduction, and decreased top-down prefrontal control of the nucleus accumbens, corroborating the high sensibility of the PFC to chronic stress in the female population.

Impact: We identified the prefrontal cortex as the central hub of chronic stress-induced changes in brain function in a female population of animals using multimodal MRI, thus creating a model for further investigation of distinct effects in possible treatments.



The detrimental lifelong impacts of early life adversity on brain

Akiko Uematsu¹, Chihiro Yokoyama², Akihiro Kawasaki¹, Chiho Takeda¹, Tomoko Ishibuchi¹, and Takuya Hayashi¹

¹Laboratory of Brain Connectomics, RIKEN BDR, Kobe, Japan, ²Nara Woman's University, Kobe, Japan

Keywords: Psychiatric Disorders, Brain

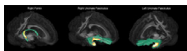
Motivation: Early life adversities (ELAs) have long-lasting detrimental impacts on physical and mental health across life course, insisting the experience of ELAs disturb healthy neuronal brain development.

Goal(s): Our goal is to investigate on the underlying mechanism of the long-lasting ELAs impacts on brain.

Approach: We examined the brains of non-human primate experienced with the ELAs of social separation from conspecific caregivers from our non-human primate MRI database in retrospective manner.

Results: Non-human primate brain with caregiver adversities (i.e. ELAs) exerts underdevelopment of multiple brain regions in both cortical and subcortical regions.

Impact: Our study demonstrates the lifelong detrimental impact of the early life adversities on brains, proving that the early life experiences, especially social ones, are the important factor for structuring brain during development.



Medial temporal lobe grey and white matter differences in late-life depression: a combined structural and multi-shell diffusion MRI analysis

Akihiro Takamiya¹, Ahmed Radwan¹, Daan Christiaens¹, Margot Van Cauwenberge¹, Thomas Vande Casteele¹, Maarten Laroy¹, Stefan Sunaert¹, Jan Van den Stock¹, Filip Bouckaert¹, Mathieu Vandenbulcke¹, and Louise Emsell¹

¹KU Leuven, Leuven, Belgium

Keywords: Psychiatric Disorders, Diffusion/other diffusion imaging techniques

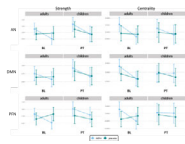
Motivation: Multi-tissue characterization of structural alterations in late-life depression (LLD) is mainly based on structural MRI and diffusion tensor imaging.

Goal(s): To investigate medial temporal lobe (MTL)-related structural alterations using advanced diffusion MRI (dMRI) models and their association with MTL grey matter (GM) volume.

Approach: Multi-shell dMRI using constrained spherical deconvolution probabilistic tractography, diffusion kurtosis imaging and fixel-based analysis to investigate alterations in the uncinate fasciculus, cingulum bundle, and fornix.

Results: Compared to controls, LLD patients showed differences in multiple dMRI metrics, with lower mean kurtosis in the uncinate fasciculus and fornix being correlated with lower MTL GM volume.

Impact: Advanced multi-shell diffusion MRI modelling can identify subtle white matter microstructural differences in late-life depression. Using multimodal MRI to investigate grey and white matter differences holistically in the same population can further our understanding of the neurobiology of psychiatric disorders.



Effects of short-term methylphenidate treatment on functional network connectivity in attention-deficit hyperactivity disorder

Eline Vansina¹, Zarah van der Pal¹, Daphne Boucherie¹, Antonia Kaiser², Linda Douw³, Liesbeth Reneman¹, and Anouk Schrantee¹

¹Radiology and Nuclear Medicine, Amsterdam University Medical Center, Amsterdam, Netherlands, ²Animal Imaging and Technology core, CIBM Center for Biomedical Imaging, École polytechnique fédérale de Lausanne (EPFL), Lausanne, Switzerland, ³Department of Anatomy and Neurosciences, Amsterdam UMC, Vrije Universiteit Amsterdam, Amsterdam Neuroscience, Amsterdam, Netherlands

Keywords: Psychiatric Disorders, Brain Connectivity

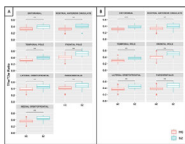
Motivation: Long-term treatment with methylphenidate for ADHD may not sustain initial treatment gains, potentially attributed to the development of tolerance over time. However, the underlying neural mechanisms remain unexplored.

Goal(s): To investigate how methylphenidate treatment alters functional connectivity changes to an acute methylphenidate challenge within three resting-state networks implicated in ADHD dysfunction.

Approach: Resting-state fMRI before and after the challenge was collected in children and adults with ADHD, at baseline and after 16-week treatment with methylphenidate or placebo.

Results: Functional connectivity measures in the frontoparietal network in children became more similar to that of controls after 4-months of methylphenidate treatment.

Impact: Methylphenidate has long-lasting effects on within-frontoparietal network connectivity, but lack of change in response to MPH-challenge after treatment suggests that there is no tolerance in this neurobiological parameter. Future investigations require long term follow-up to investigate neurobiological and symptom tolerance.



Increased Intracortical T1w/T2w Ratio in Patients with Chronic Schizophrenia

Gayatri Maria Schur^{1,2,3,4}, Ruoyu Luie Wang^{2,3,5}, Ryn Flaherty^{2,3,4}, Yu Veronica Sui^{2,3,4}, and Mariana Lazar^{2,3}

¹Medical Scientist Training Program, New York University. Grossman School of Medicine, New York, NY, United States, ²Bernard and Irene Schwartz Center for Biomedical Imaging, Department of Radiology, New York University Grossman School of Medicine, New York, NY, United States, ³Center for Advanced Imaging Innovation and Research (CAI2R), Department of Radiology, New York University Grossman School of Medicine, New York, NY, United States, ⁴Vilcek Institute of Graduate Biomedical Sciences, New York University Grossman School of Medicine, New York, NY, United States, ⁵SUNY Downstate Health Sciences University, New York, NY, United States

Keywords: Psychiatric Disorders, Psychiatric Disorders, Schizophrenia

Motivation: While dysmyelination is known to occur in white matter in schizophrenia, studies characterizing intracortical myelin *in vivo* are limited.

Goal(s): Our goal was to quantify intracortical myelin in chronic schizophrenia (SZ) vs. healthy controls (HC), and to correlate myelination with volumetric changes.

Approach: We used T1w/T2w ratio to map cortical myelin.

Results: We found decreased cortical volume but increased T1w/T2w ratio in frontal and temporal regions in SZ vs. HC. Apart from potentially increased ectopic myelin content, increased T1w/T2w in patients may also reflect iron deposition or presence of glial cells which contain high intracellular iron.

Impact: Characterizing intracortical myelin will help refine the dysmyelination hypothesis of schizophrenia. Our results in a chronic schizophrenia group support this hypothesis and further suggest potential abnormalities in cortical iron and glial cells.

¹Department of Biomedical Engineering, Columbia University, New York, NY, United States, ²Department of Psychiatry, Columbia University, New York City, NY, United States, ³Division of Molecular Imaging and Neuropathology, New York State Psychiatric Institute, New York City, NY, United States, ⁴Department of Electrical Engineering, Columbia University, New York City, NY, United States

Keywords: Psychiatric Disorders, Psychiatric Disorders, Mental health, Suicide Bereavement, Grief

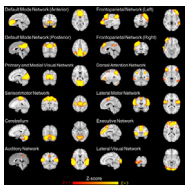
Motivation: Losing of a loved one to suicide is a uniquely difficult form of grief, often affecting a person's ability to cope. It remains unclear what neural processes may cause intrusive thoughts to happen.

Goal(s): To understand the processes that contribute to intrusive and spontaneous thoughts of loss.

Approach: We trained a decoder to identify fMRI voxel-patterns associated with deceased-related attention and mental representations, which we then applied to another dataset acquired during mind-wandering to understand how these processes contribute to the occurrence of thoughts of loss.

Results: Engagements of attention and memory increased during blocks where subjects reported having thought about their loss.

Impact: The identification of attention and memory neural patterns in suicide related bereavement has the potential to recognize patients experiencing a poorer grief outcome and to help them improve grief trajectories



Objective Depression Diagnosis derived from Effective Connectivity through Dynamic Causal Modelling

Sjir Schielen¹, Dmitrii Stepanov¹, Ramona Cîrstian², Albert Aldenkamp^{1,3}, and Svitlana Zinger^{1,3}

¹Electrical Engineering, Eindhoven University of Technology, Eindhoven, Netherlands, ²Donders Centre for Cognitive Neuroimaging, Donders Institute for Brain, Cognition and Behaviour, Radboud University, Nijmegen, Netherlands, ³Epilepsy Center Kempenhaeghe, Heeze, Netherlands

Keywords: Psychiatric Disorders, fMRI (resting state), Neuropsychiatric disorders, effective connectivity, neurodynamics

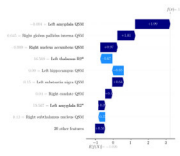
Motivation: The diagnosis of major depressive disorder (MDD) currently involves subjectivity, but an objective test based on a measurement is desired.

Goal(s): To obtain effective connections between brain networks from functional MRI that both allow MDD to be diagnosed and offer clinically relevant insight.

Approach: Stochastic Dynamic Causal Modelling is applied to the time series of resting-state networks. The most discriminative connections are found through Bayesian Model Reduction and Chi-Square feature selection. These connections are used for classification using machine learning.

Results: Eight clinically relevant effective connections result in 94% leave-one-out cross-validation accuracy, which resulted in 100% accuracy on a separate test set.

Impact: The discriminative ability of the eight resulting effective connections aid understanding of MDD's pathophysiology. Furthermore, the results may inspire researchers to investigate the eight most discriminative connections on other datasets, which can lead to an objective diagnostic biomarker for MDD.



SHAP Interpretation of a Tree-Based Model for Deep Gray Matter QSM and R2* in First Episode Psychosis Patients and Their Response to Antipsychotics

Pamela Franco^{1,2,3,4}, Cristian Montalba^{1,2,5}, Raul Caulier-Cisterna⁶, Alonso González^{7,8}, Juan Undurraga⁹, Nicolás Crossley^{1,2,7}, and Cristian Tejos^{1,2,10}

¹Biomedical Imaging Center, Pontificia Universidad Católica de Chile, Santiago, Chile, ²Millennium Institute for IntelligentHealthcare Engineering - iHEALTH, Pontificia Universidad Católica de Chile, Santiago, Chile, ³Department of Physics, Faculty of Science, Universidad de Santiago de Chile, Santiago, Chile, ⁴School of of Civil Engineering, Computer Science and Telecommunications, Faculty of Engineering, Universidad Finis Terrae, Santiago, Chile, ⁵Radiology Department, School of Medicine, Pontificia Universidad Católica de Chile, Santiago, Chile, ⁶Department of Informatics and Computing, Faculty of Engineering,, Universidad Tecnológica Metropolitana, Santiago, Chile, ⁷Department of Psychiatry, School of Medicine, Pontificia Universidad Católica de Chile, Santiago, Chile, ⁸School of Medicine, Universidad Finis Terrae, Santiago, Chile, ⁹Department of Neurology and Psychiatry, Universidad del Desarrollo, Santiago, Chile, ¹⁰Department of Electrical Engineering, School of Engineering, Pontificia Universidad Católica de Chile, Santiago, Chile

Keywords: Psychiatric Disorders, Psychiatric Disorders

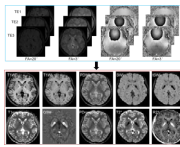
Motivation: Several studies have demonstrated altered neurochemicals in psychosis. QSM quantify susceptibility changes, which have been associated with iron concentrations in dopamine pathways.

Goal(s): Identify the strongest predictive QSM and R2* in first-episode psychosis (FEP) patients and their response to antipsychotics using a tree-based model.

Approach: A tree-base model to discriminate between treatment-responsive (RS) and treatment-resistant (TRS) FEP patients by looking at tissue susceptibilities.

Results: Our model classifies RS and TRS patients: 96.67 ± 1.38 % accuracy. Also, TRS could be classified by QSM: left amygdala, right globus pallidus interna, and nucleus accumbens, which have been associated with decreased dopamine in TRS patients.

Impact: The proposed features could be used in future studies to early detect TRS-FEP patients and promptly adopt adequate treatment. This intervention may improve their clinical outcomes and minimize the functional disability and social burden resulting from prolonged psychosis.



Improved depiction of habenua with optimized high-resolution STAGE

Binyang Bian¹, Lei Zhang¹, E. Mark Haacke², Lin Hou¹, Yueluan Jiang³, and Tao Li⁴

¹radiology department, Bethune First Hospital of Jilin University, Changchun, China, ²Department of Biomedical Engineering, Wayne State University, Detroit, Michigan, MI, United States, ³MR Scientific Marketing, Diagnostic Imaging, Siemens Healthineers Ltd, Beijing, China, ⁴School of Nursing, Jilin University, Changchun, China

Keywords: Psychiatric Disorders, Psychiatric Disorders, habenua; depressive disorder; STAGE

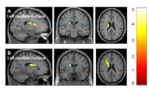
Motivation: The visualization and identification of humans habenua is particularly challenging in vivo MR imaging due to its subcortical location and small size

Goal(s): To achieve visualization and quantitative analysis of the habenua

Approach: In this work we performed a high-resolution strategically acquired gradient echo protocol at 3T for visualization habenua

Results: We achieved high-definition visualization of habenua, and provided a quantitative multi-parametric characterization of the habenua microstructure in vivo

Impact: We performed an optimized high-resolution sequence, which used to guide future studies optimizing the visualization of habenua. The standardized nature of quantitative MR measurements also provide a baseline from a healthy cohort against which to assess pathological differences.



Motor inhibition in functional paralysis – a task-based fMRI study.

Vanessa Vallesi^{1,2}, Elia Hurni^{1,2}, Jothini Sritharan^{1,2}, Anke Scheel Sailer^{3,4,5}, Inge Eriks Hoogland^{4,5,6}, Michaela Gegusch⁷, Johannes Slotboom⁸, Rajeev Verma^{1,2}, and Giuseppe Zito^{1,2}

¹Advanced Imaging Research (AIR) Group, Swiss Paraplegic Research, Nottwil, Switzerland, ²Department of Radiology, Swiss Paraplegic Centre, Nottwil, Switzerland, ³Department of Paraplegia, Rehabilitation and Quality Management, Swiss Paraplegic Centre, Nottwil, Switzerland, ⁴Faculty Health Science and Medicine, University Lucerne, Lucerne, Switzerland, ⁵Health Services Research, Swiss Paraplegic Research, Nottwil, Switzerland, ⁶Outpatient Care Unit, Swiss Paraplegic Centre, Nottwil, Switzerland, ⁷Clinic for Neurology, Cantonal Hospital St.Gallen, St. Gallen, Switzerland, ⁸Institute for Diagnostic and Interventional Neuroradiology, University Hospital and Inselspital, Bern, Switzerland

Keywords: Psychiatric Disorders, Neuroscience, Functional Neurological Disorder

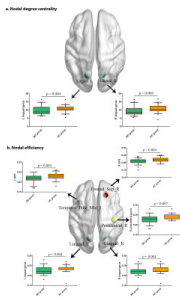
Motivation: In functional neurological disorders (FND), symptoms (including paralysis) occur despite intact anatomical pathways. The pathophysiology of FND is poorly understood, making diagnosis, treatment and prognosis uncertain.

Goal(s): Assuming that higher cognitive functions may play a role in the manifestation of symptoms, this study investigates motor inhibition in FND.

Approach: Using task-based fMRI, this observational study investigates the blood oxygenation level dependent (BOLD) response of the brain during a motor inhibition task.

Results: Preliminary results indicate reduced behavioral performance and lower BOLD activity in the left caudate nucleus, a key node for motor inhibition, suggesting a disrupted neural pathway in FND.

Impact: Our task-based fMRI results suggest impaired motor inhibition in functional neurological disorders and open new avenues for further investigation on its role in symptom production and potential treatment options.



Association of peripheral inflammation with disrupted brain functional network topology in bipolar disorder

Guixian Tang¹, Guanmao Chen¹, Wei Cui², and Ying Wang¹

¹First Affiliated Hospital of Jinan University, Guangzhou, China, ²MR Research, GE Healthcare, Beijing, China, Guangzhou, China

Keywords: Psychiatric Disorders, Neuroinflammation

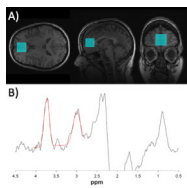
Motivation: Increasing evidences show that inflammation might be involved in bipolar disorder (BD), but the association between abnormal brain function and inflammation in BD patients is still unclear.

Goal(s): In this study, we tried to explore the disrupted brain functional network topology, peripheral cytokines and their correlations to demonstrate the role of inflammation in brain functional network topology in BD.

Approach: Graph theory analysis.

Results: The current study demonstrated disrupted topological organization in the whole brain and regional connectivity was associated with inflammatory cytokines of the IL-4, IL-8 and IL-10 levels in BD.

Impact: Our study provided preliminary evidence of the association between disrupted brain functional network topology and neuroinflammation in BD.



Effects of intermittent Theta Burst Stimulation and adjunctive D-Cycloserine on GABA levels in the medial Prefrontal Cortex

Marilena M DeMayo¹, Jaeden L Cole¹, Signe L Bray¹, Ashley D Harris¹, and Alexander McGirr¹

¹University of Calgary, Calgary, AB, Canada

Keywords: Psychiatric Disorders, Brain


Motivation: Non-invasive brain stimulation is an evidenced based treatment for major depression. Change in GABA in the medial prefrontal cortex (mPFC) has been suggested as a mechanism of antidepressant effect of brain stimulation, including intermittent Theta Burst Stimulation (iTBS).

Goal(s): Investigate the effect of iTBS combined with adjunctive D-Cycloserine on magnetic resonance spectroscopy measured GABA levels in the mPFC.

Approach: Participants were randomized to receive adjunctive D-Cycloserine or placebo in addition to two weeks of iTBS treatment, with assessments at baseline and after two weeks of intervention.

Results: There was no effect of iTBS, adjunctive D-Cycloserine or responder status on GABA levels.

Impact: This study provides evidence of dissociation between GABA change and clinical response following the delivery of intermittent Theta Burst Stimulation (iTBS) in major depression. The antidepressant effects of iTBS may not rely on change in GABA within the mPFC.



Pretreatment brain magnetic resonance imaging outperforms clinical ratings in predicting major depressive disorder treatment outcomes

Fenghua Long¹, Yufei Chen¹, Qian Zhang¹, Yaxuan Wang¹, Yitian Wang¹, Qian Li¹, Youjin Zhao¹, and Fei Li¹

¹Department of Radiology and Huaxi MR Research Center (HMRRC), Functional and Molecular Imaging Key Laboratory of Sichuan Province, West China Hospital, Sichuan University, Chengdu, China

Keywords: Psychiatric Disorders, MR Value

Motivation: It is clinically needed to explore predictive potential of pretreatment features in major depressive disorder (MDD) treatment outcomes to guide personalized medicine approaches.

Goal(s): To evaluate and compare overall predictive performance of clinical and brain magnetic resonance imaging (MRI) features for treatment outcomes and assess performance of distinct modalities and interventions in MRI studies.

Approach: We conducted separate meta-analyses on clinical and MRI studies followed with subgroup meta-analyses and meta-regression.

Results: MRI studies outperformed clinical studies in sensitivity. Within MRI group, resting-state functional MRI exhibited higher specificity than task-based functional MRI. No significant differences were found among remaining modality and intervention subgroups.

Impact: Our findings highlight the potential of utilizing pretreatment brain MRI data to predict treatment outcomes for MDD. This is valuable for using MRI features to early identify patients' treatment outcomes, potentially assisting clinicians in considering alternative treatment options.

EP	Metric	P5	G3	G14
MD				
AD				
SZ	Metric	P3	P4	YMBS
BD				
MD				
AD				
FA				
RA				
D ₁				
C ₁				

White Matter Microstructure Alterations and Their Link to Symptomatology in Early Psychosis and Schizophrenia

Tommaso Pavan^{1,2}, Yasser Alemán-Gómez^{1,2}, Pascal Steullet¹, Zoe Schilliger^{1,3}, Daniella Dwir¹, Raoul Jenni^{1,3}, Martine Cleusix¹, Luis Alameda^{1,3}, Kim Q. Do^{1,3}, Philippe Conus¹, Paul Klauser^{1,3}, Patric Hagmann¹, and Ileana Jelescu¹

¹Lausanne University Hospital (CHUV), Lausanne, Switzerland, ²University of Lausanne, Lausanne, Switzerland, ³University of Lausanne (UNIL), Lausanne, Switzerland

Keywords: Psychiatric Disorders, White Matter, Neuroinflammation, DKI, DTI, DWI, Psychosis


Motivation: Schizophrenia features complex symptomatology. Increased dMRI measures specificity is the key to capture the relation of white matter microstructure alterations with patients psychopathology.

Goal(s): We aim to better characterize WM pathology and, thus, understand its relation with the symptomatology of early-psychosis and schizophrenia.

Approach: Diffusion Kurtosis Imaging and White Matter Tract Integrity-Watson were estimated in 275 individuals. Whole-brain WM estimates were compared between patients and controls, and associated with patients psychopathology.

Results: dMRI patterns suggest that WM alterations are already present and widespread in EP. Two trends of WM deterioration with concomitant demyelination vs neuroinflammation were found associated with clinical scales regression analysis.

Impact: Our findings possibly provide a missing link between specific symptoms and underlying pathology. The association between patients' psychopathology and advanced dMRI metrics may spark further interest in linking specific symptom in psychiatry diseases to microstructure alterations.



Neuromelanin-sensitive MRI of the substantia nigra distinguishes bipolar from unipolar depression

Xinping Kuai¹, Dandan Shao², Shengyu Wang², Pu-Yeh Wu³, Yan Wu⁴, and Xuexue Wang⁵

¹Department of Radiology, Shanghai Municipal Hospital of Traditional Chinese Medicine, Shanghai University of Traditional Chinese Medicine, Shanghai, China, ²Department of Radiology, Ruijin Hospital, Shanghai Jiao Tong University School of Medicine, Shanghai, China, ³GE Healthcare, Beijing, China, ⁴Division of Mood Disorders, Shanghai Mental Health Center, Shanghai Jiao Tong University School of Medicine, Shanghai, China, ⁵Department of Radiology, Shanghai Mental Health Center, Shanghai Jiao Tong University School of Medicine, Shanghai, China

Keywords: Psychiatric Disorders, Psychiatric Disorders

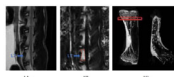
Motivation: Depression in bipolar disorder (BD-II) is frequently misdiagnosed as unipolar depression (UD), leading to inappropriate treatment and downstream complications.

Goal(s): We aimed to evaluate neuromelanin (NM) MRI signal and volume changes in substantia nigra (SN) in HC, BD and UD patients.

Approach: NM MRI was acquired and analyzed.

Results: We found that compared with HC, patients with BD-II and UD had decreased CNR and increased volume on bilateral SN. The NM volume in BD-II group was increased compared to UD group. Furthermore, left and right NM volume exhibited the largest AUC for discriminating patient from HC, and BD from UD, respectively.

Impact: Our findings revealed that abnormally decreased CNR and increased volume in SN region might underlie predisposition to BD-II and UD. NM MRI techniques can discriminate BD-II from UD and can be a useful clinical tool in evaluation of mental disorders.



Evaluation of bone marrow fat content and fatty acid composition using quantitative MRI combined with metabonomics in diabetic rabbits

Tian Zhang¹, Lei Hu¹, Ziyang Fei¹, Yufan Gao¹, Yan Wang¹, Yuchen Yan¹, Weiyin Vivian Liu², and Yunfei Zha¹

¹Renmin Hospital of Wuhan University, Wuhan, China, ²GE Healthcare, Beijing, China

Keywords: Bone, Diabetes

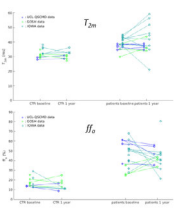
Motivation: Bone marrow is a key target for diabetes mellitus.

Goal(s): Quantitative assessment of fat content in lumbar bone marrow and trabecular microstructural changes in alloxan-induced diabetics rabbits.

Approach: Iterative decomposition of water and fat with echo asymmetry and least-squares estimation quantitation sequence (IDEAL-IQ), micro computed tomography (Micro-CT), and gas chromatography-mass spectrometry (GC-MS) were employed.

Results: IDEAL-IQ and GC-MS techniques are capable of detecting changes in fat content and variations in fatty acid composition during the early stages of diabetic bone marrow.

Impact: The fat content and fatty acid composition in the bone marrow plays an important role in bone metabolism in diabetic patients.



T2 relaxometry of foot muscles in young patients with Charcot-Marie-Tooth disease: comparison between centres and scanner vendors

Nick Zafeiropoulos¹, Carolynne M Doherty¹, Howard Paige², Stephen Wastling¹, Riccardo Zuccarino^{2,3}, Evelin Milev⁴, Tina Banks⁴, Sachit Shah⁵, Katherine Stephens², Tiffany Grider², Shawna M Feely², Peggy Nopoulos², Mariola Skorupinska¹, Menelaos Pipis¹, Emma J Nicolaisen², Amy McDowell¹, Luke O'Donnell¹, Alex M Rossor¹, Laura Matilde¹, Francesco Muntoni¹, Tarek Yousry¹, Daniel Thedens², Jasper M Morrow¹, Michael E Shy², Mary M Reilly¹, David Thomas¹, and John Thornton¹

¹University College London, London, United Kingdom, ²University of Iowa, Iowa, IA, United States, ³Centro Clinico NeMO Trento, Trento, Italy, ⁴Great Ormond Street Hospital, London, United Kingdom, ⁵National Hospital for Neurology and Neurosurgery, London, United Kingdom

Keywords: Muscle, Relaxometry, T2 mapping


Motivation: Current clinical use of quantitative MRI biomarkers for the assessment of neuromuscular disease is limited by accuracy and reliability

Goal(s): To develop a robust processing strategy for multi-vendor muscle-water T₂ mapping (T_{2m}) in foot muscle

Approach: A multi-component CPMG extended phase graph signal model was used to determine T_{2m} and apparent fat fraction (ff_a) in fat-infiltrated foot muscle using maximum likelihood estimation

Results: Stable estimates of foot muscle T_{2m} and ff_a were obtained in patients with Charcot-Marie-Tooth disease and healthy controls, at baseline and 1 year follow up. In patients, T_{2m} and ff_a were both elevated at each time point

Impact: T_{2m} and ff_a obtained from CPMG images using extended phase graph modelling and maximum likelihood estimation may be sensitive measures of neuromuscular pathology



How temperature and immersion liquid affect the relaxation properties in articular cartilage samples?

Olli Nykänen^{1,2}, Iida Rätty³, Henri Leskinen¹, Nina Hänninen^{1,4}, and Mikko J Nissi¹

¹Department of Technical Physics, University of Eastern Finland, Kuopio, Finland, ²Oulu University Hospital, Oulu, Finland, ³A.I. Virtanen Institute for Molecular Sciences, University of Eastern Finland, Kuopio, Finland, ⁴Imaging Center, Kuopio University Hospital, Kuopio, Finland

Keywords: Cartilage, Cartilage

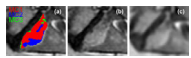
Motivation: Preclinical measurement series of articular cartilage samples are often time-consuming. Thus, knowledge about changes in relaxation properties of cartilage during measurements and depending on the sample handling is important.

Goal(s): To study the effect of storage temperature and immersion liquid on the relaxation properties of articular cartilage.

Approach: T1, T2, and adiabatic T1rho relaxation times were measured for 28 cartilage-bone samples at five timepoints and analyzed by linear regression.

Results: T1 and adiabatic T1rho relaxation times increased over time, while T2 varied. Immersion in phosphate-buffered saline instead of signal-free perfluoropolyether increased the relaxation times in superficial cartilage.

Impact: The study increases understanding on how the relaxation properties within ex vivo cartilage samples change over time. The results obtained here should be considered when planning future studies utilizing such samples.



Per-voxel classification of Modic changes in conventional MRI

Christian Waldenberg^{1,2}, Harald Foss¹, Hanna Hebelka³, Helena Brisby⁴, and Kerstin Lagerstrand^{1,2}

¹Department of Medical Radiation Sciences, University of Gothenburg, Gothenburg, Sweden, ²Department of Medical Physics and Biomedical Engineering, Sahlgrenska University Hospital, Gothenburg, Sweden, ³Department of Radiology, University of Gothenburg, Gothenburg, Sweden, ⁴Department of Orthopaedics, University of Gothenburg, Gothenburg, Sweden

Keywords: Bone, Data Analysis, Spine

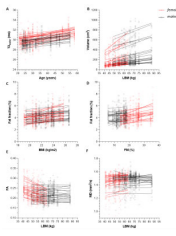
Motivation: Modic Changes (MCs) are often heterogeneous and difficult to classify objectively. Hence, new diagnostic tools are required to improve MC classification.

Goal(s): This study aims to develop a data-driven model for the classification of MC lesions on a per-lesion and per-voxel level from conventional MR images.

Approach: Conventional MR images from 12 patients were used to create an MC classification model by fitting three multivariate normal distribution functions to the MRI MC data which was subsequently used for MC classification.

Results: The model reached high accuracy (74-100%), enabling a detailed classification on a per-voxel level and longitudinal tracking of MC transitions.

Impact: This study introduces a data-driven model for classifying Modic changes in vertebral bone marrow using MR images. The model achieves high accuracy, enabling detailed classification and tracking of Modic change transitions, potentially improving patient diagnosis and care.



The MOTION study – First quantitative muscle MRI results in a large cross-sectional cohort of healthy subjects

Linda Heskamp¹, Roosmarijn Brenninkmeijer², Lara Schlauffke³, Bart Bartels², and Martijn Froeling¹

¹Radiology, UMC Utrecht, Utrecht, Netherlands, ²Child Development and Exercise Center, UMC Utrecht, Utrecht, Netherlands, ³Department of Neurology, BG-University Hospital Bergmannsheil gGmbH, Bochum, Germany

Keywords: Muscle, Muscle, Quantitative Imaging

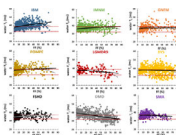
Motivation: The overall aim of our ongoing study MOTION is to connect whole leg quantitative MRI (qMRI) and muscle structure to function and lifestyle in 162 healthy volunteers.

Goal(s): Preliminary analysis of 31 subjects to identify potential covariates that may impact qMRI measurements.

Approach: Muscle fat fraction (FF), mean diffusivity (MD), fractional anisotropy (FA) and T_{2water} were determined in 20 muscles from tendon to tendon bilaterally, and related to age, gender, and body composition.

Results: Muscle FF is higher in heavier subjects with more body fat. FA is lower and MD and volume are higher in larger subjects. T_{2water} depends on age and gender.

Impact: Accounting for covariates describing body composition (BMI, lean body mass and body fat mass) on top of gender and age is crucial for proper interpretation of quantitative muscle MRI in clinical studies on neuromuscular disease patients and healthy controls.



Water T₂ mapping from low to high fat fraction values in lower limb skeletal muscles of different neuromuscular disorders

Harmen Reyngoudt¹, Pierre-Yves Baudin¹, Ericky Caldas de Almeida Araujo¹, and Benjamin Marty¹

¹NMR Laboratory, Neuromuscular Investigation Center, Institute of Myology, Paris, France

Keywords: Muscle, Modelling, biomarkers, neuromuscular, water T₂, fat fraction

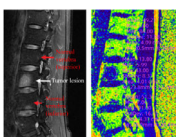
Motivation: Muscle water T₂ is an interesting quantitative MRI biomarker in neuromuscular disorders but its interpretation is influenced by the presence of fat.

Goal(s): We investigated how this water T₂-fat relationship differed between nine different neuromuscular disorders.

Approach: We looked at linear and 2nd degree polynomial fits, all obtained with the same 3-T system, sequence and post-processing pipeline.

Results: Polynomial fitting describes the data better and the water T₂-fat relationship needs to be interpreted in a disease-specific context, especially when there is a known inflammatory component and/or if water T₂ is increased before the occurrence of any muscle fat replacement.

Impact: The relationship between MRI biomarkers water T₂, reflecting active muscle damage, and fat fraction, reflecting disease progression, should be interpreted in the context of the disease, whether or not there is inflammation or extensive active muscle damage.



Feasibility of echo asymmetry and least squares estimation (IDEAL-IQ) in differentiation of atypical spinal hemangiomas from metastases

Qizheng Wang¹, Ke Xu¹, Xiaoxi Ji¹, and Ning Lang¹

¹Peking University Third Hospital, Beijing, China

Keywords: Skeletal, Skeletal

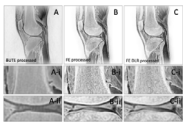
Motivation: It is common for patients with primary tumors to find abnormal signals in the spine, which may be initially reported as “metastases cannot be rule out”. For these cases, differential diagnosis has a significant impact on patient staging and management, which may result in misdiagnosis or additional imaging, ultimately biopsy, and unnecessary costs.

Goal(s): To investigate chemical shift-encoded sequence (IDEAL-IQ) for differential diagnosis of spinal tumors.

Approach: Single-center prospective study.

Results: This work highlights the benefits of adding proton density fat fraction (PDF) maps yield from IDEAL-IQ to improve diagnostic accuracy of spinal metastases and hemangiomas without contrast agents.

Impact: IDEAL-IQ provides reliable quantification of spinal tumor bone marrow infiltration pattern in clinical settings, which is comparable to the quantitative parameters of DCE-MRI. It may be a valuable tool for providing information for early differential diagnosis in a non-invasive way.



Bone Imaging of the Knee Using delta UTE (δ UTE) and Field Echo Imaging

Won C Bae^{1,2}, Vadim Malis¹, Yuichi Yamashita³, Anya Mesa¹, Diana Vucevic¹, and Mitsue Miyazaki¹

¹University of California, San Diego, La Jolla, CA, United States, ²VA San Diego Healthcare System, San Diego, CA, United States, ³Canon Medical Systems Corporation, Tochigi, Japan

Keywords: Bone, Bone, UTE, Knee, Osteoarthritis

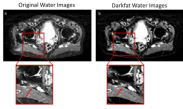
Motivation: Bony structures of the human knee play important roles in the stability and normal function and show alterations in morphology with diseases such as osteoarthritis.

Goal(s): Advance MR imaging of the bone.

Approach: Three techniques utilizing delta ultrashort echo time (δ UTE), field echo (FE), and FE with deep learning reconstruction (DLR) with simple post-processing was developed to image knees of volunteers. SNR and CNR were determined.

Results: We demonstrate that FE DLR, compared to δ UTE, was advantageous for greater signal to noise ratio for the cortical bone, as well as higher resolution that depicted trabecular structures.

Impact: This study advances MR imaging of the bone, for specific use cases such as morphologic evaluation. The FE technique in particular is immediately translatable using existing sequences to help evaluate knee bone in the clinical settings.



Efficient and Complete Fat Suppression in 2-point Dixon MRI for Improved Qualitative and Quantitative Assessment of Lumbar Plexus

Sheng Qing Lin¹, Durga Udayakumar^{1,2}, Avneesh Chhabra¹, and Ananth J Madhuranthakam^{1,2}

¹Radiology, UT Southwestern Medical Center, Dallas, TX, United States, ²Advanced Imaging Research Center, UT Southwestern Medical Center, Dallas, TX, United States

Keywords: Other Musculoskeletal, Fat, Fat Suppression, Dixon


Motivation: The use of 2-point Dixon is prevalent for fat/water separation in MRI, but suffers from incomplete fat suppression, leading to residual fat signal in the water image. We have previously developed a "Darkfat" post-processing technique that can reduce this residual signal.

Goal(s): This retrospective study aims to evaluate Darkfat processing in clinical lumbar plexus images.

Approach: Retrospective 2-point T2-weighted lumbar images from 30 patients were processed using Darkfat and evaluated through qualitative and quantitative assessment.

Results: Water-only images from Darkfat processing had significantly better fat suppression ($P < 0.0001$), and subjectively better image quality ($P < 0.005$) compared to original water images from 2-point T2-weighted Dixon acquisition.

Impact: Darkfat image processing significantly improves fat suppression in clinical 2-point T2-weighted lumbar images enabling enhanced anatomical visualization. This could potentially improve pathological visualization.



Evaluation of the change in magnetic susceptibility values of knee joint cartilage in patients with osteoarthritis using UTE-QSM

Jing Li¹, Shaoxin Xiang², Xianqi Wang³, Xiaohong Tian¹, Bing Ji¹, Shanshan Hu¹, Ming Zhang⁴, Yu Xin Yang², Hongjiang Wei^{4,5}, and Wei Chen³

¹Department of Radiology, Southwest Hospital, Army Medical University (Third Military Medical University), Chongqing, China, Chongqing, China, ²MR Collaboration, United Imaging Research Institute of Intelligent Imaging, Beijing, China, Beijing, China, ³7T Magnetic Resonance Imaging Translational Medical Center, Southwest Hospital, Army Medical University (Third Military Medical University), Chongqing, China, Chongqing, China, ⁴School of Biomedical Engineering, Shanghai Jiao Tong University, Shanghai, China, Shanghai, China, ⁵The National Engineering Research Center of Advanced Magnetic Resonance Technologies for Diagnosis and Therapy (NERC-AMRT), Shanghai Jiao Tong University, Shanghai, China., Shanghai, China

Keywords: Cartilage, Joints, UTE-QSM

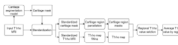Motivation: Quantitative susceptibility mapping (QSM) may be a useful tool for studying the characteristics of collagen fibers in knee cartilage. The susceptibility quantification using GRE with fat saturation and relatively long TE may be further improved using UTE-QSM.

Goal(s): To measure the change in susceptibility values of knee cartilage in patients with different grades of OA using UTE-QSM.

Approach: A total of 13 knees from 10 patients who underwent both X-ray and MRI-UTE were enrolled.

Results: Our results show that in the posterior regions of the medial femoral condyle and lateral femoral condyle, the magnetic susceptibility value significantly decreases with the increase of OA grade.

Impact: UTE-QSM can promote osteoarthrologists and radiologists to better understand knee OA from different dimensions, and can provide more imaging evidence for monitoring the progress of OA, formulating treatment plans, and evaluating treatment effects.



A systematic automated post-processing approach for quantitative analysis of 3D T1p knee MRI

Junru Zhong¹, Yongcheng Yao^{1,2}, Fan Xiao³, Michael Tim-Yun Ong⁴, Kevin Ki-Wai Ho⁴, Queenie Chan⁵, James F Griffith¹, and Weitian Chen¹

¹Department of Imaging and Interventional Radiology, The Chinese University of Hong Kong, Sha Tin, NT, Hong Kong, ²School of Informatics, University of Edinburgh, Edinburgh, United Kingdom, ³Department of Radiology, Shanghai Sixth People's Hospital Affiliated to Shanghai Jiao Tong University School of Medicine, Shanghai, China, ⁴Department of Orthopaedics & Traumatology, The Chinese University of Hong Kong, Sha Tin, NT, Hong Kong, ⁵Philips Healthcare, Sha Tin, NT, Hong Kong

Keywords: Cartilage, Software Tools

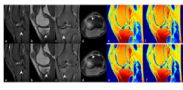
Motivation: To address the global healthcare challenge of knee osteoarthritis.

Goal(s): Develop and validate an automated post-processing method for quantitative 3D T1p knee imaging analysis. The proposed post-processing pipeline accelerates the process while preserving a user-friendly and clinical-related output.

Approach: We proposed a post-processing pipeline that combines parcellation, ROIs selection, T1rho fitting, and regionally averaged outputs. We evaluated our approach on 30 OA patients and 10 healthy controls.

Results: The proposed post-processing approach achieved satisfactory performance on automatic ROI selection compared to the manually labelled ROIs and provided quantitative T1p analysis with clinical promise.

Impact: Our proposed pipeline enables automated post-processing for T1p imaging with deep learning, pushing this promising technique to the clinics to provide sensitive and quantitative knee OA diagnostics.



Clinical value of a 10-minute deep-learning reconstruction fast spinecho knee magnetic resonance imaging protocol including T2 mapping

Xi Xia Wu¹, Weiyin Vivian Liu², and Yunfei Zha¹

¹Renmin Hospital of Wuhan University, Wu Han, China, ²GE Healthcare China, Beijing, Beijing, China

Keywords: Cartilage, Quantitative Imaging

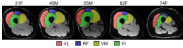
Motivation: T2 mapping is difficult to be implemented in clinics for long scan time.

Goal(s): To propose a 10-minute fast spin echo knee MRI protocol including quantitative T2 map and morphologic images in identifying cartilage injury or grading cartilage degeneration.

Approach: To subjectively and objectively assess the clinical value of knee imaging with different acceleration factor of 2 and 3 as well as using conventional and deep learning reconstruction algorithms (CR, DLR).

Results: Both FSE_{DLR} and DL-based quantitative T2 map with either an acceleration factor of 2 or 3 elevated diagnostic accuracy using a senior rater as a final diagnosis.

Impact: A knee protocol including deep-learning based FSE structure imaging and quantitative T2 map could be facilitated in clinical application further elevating the diagnostic accuracy and performance.



MRI metrics can help explain the loss of functional strength in aging

Mary Elizabeth Hall¹, Yael Vainberg¹, Jessica Asay¹, Jennifer Hicks², Julie Muccini¹, Garry Gold¹, and Valentina Mazzoli³

¹Radiology, Stanford University, Stanford, CA, United States, ²Bioengineering, Stanford University, Stanford, CA, United States, ³Bernard and Irene Schwartz Center for Biomedical Imaging, Department of Radiology, New York University, New York, NY, United States

Keywords: Muscle, Aging

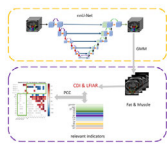
Motivation: There is a need to investigate the relationship between age-related muscle atrophy and functional strength.

Goal(s): To explore the relationship between volumes of individual knee extensor muscles relative to total volume of the quadriceps as measured by MRI and sit to stand performance.

Approach: Participants performed a sit to stand test while being recorded by a markerless motion capture system and underwent an MRI exam that included a Dixon scan, which was used to calculate muscle volumes in the quadriceps.

Results: There were correlations between age and vastus intermedius and vastus lateralis volume. Rectus femoris volume was correlated with sit to stand performance.

Impact: We utilized a novel experimental design using smartphone-based markerless motion capture and MRI metrics to study the relationship between functional strength and age-related muscle atrophy. This work could inform design of physical therapy programs for the elderly.



Use An Automated Pipeline to Quantify Erector Spinae Muscle Asymmetry and Correlate It with Quality of Life in Adult Degenerative Scoliosis

Qi Zhang¹, Chenglong Wang¹, Chengxiu Zhang¹, Haijie Wang², Yang Song³, Jun Zhao⁴, and Guang Yang¹

¹Shanghai Key Laboratory of Magnetic Resonance, East China Normal University, Shanghai, China, ²Institute of Research and Clinical Innovations, Neusoft Medical Systems Co., Ltd., Beijing, China, ³MR Research Collaboration Team, Siemens Healthineers Ltd., Shanghai, China, ⁴Department of Radiology, The First Affiliated Hospital, Army Medical University, Chongqing, China

Keywords: Muscle, Data Analysis

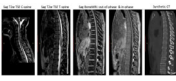
Motivation: To explore the influence of erector spinae muscle asymmetry to adult degenerative scoliosis (ADS) on patients' quality of life.

Goal(s): To develop a pipeline for automated quantification of the normalized FCSA difference index (CDI) and left-right fat Infiltration asymmetry ratio (LFIAR) from MRI images for assessment of ADS.

Approach: We used nnU-Net for precise anatomical segmentation on T2 images. Then, CDI and LFIAR were calculated and correlated to ADS scales.

Results: The automated model adeptly delineated paravertebral muscle groups, which were used to calculate CDI and LFIAR. Noteworthy correlations between CDI, LFIAR, and ADS scales were found among male subjects.

Impact: This research streamlines clinical workflows, imparts valuable insights into the severity of ADS, and equips clinicians with crucial data for informed clinical decision-making.



A multipurpose Adolescent Idiopathic Scoliosis specific short MRI protocol: feasibility study in volunteers.

Yulia M Shcherbakova¹, Peter P.G. Lafranca², Wouter M Foppen³, Tijl A van der Velden^{1,4}, Rene M. Castelein², Keita Ito^{2,5}, Tom P.C. Schlosser², and Peter R Seevinck^{1,4}

¹Department of Radiology, Image Sciences Institute, UMC Utrecht, Utrecht, Netherlands, ²Department of Orthopaedics, UMC Utrecht, Utrecht, Netherlands, ³Department of Radiology, Division Image and oncology, UMC Utrecht, Utrecht, Netherlands, ⁴MRIguidance B.V., Utrecht, Netherlands, ⁵Department of Biomedical Engineering, Eindhoven University of Technology, Eindhoven, Netherlands

Keywords: Skeletal, Skeletal, Scoliosis, MSK, Spine, sCT, synthetic CT

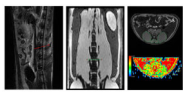
Motivation: To date, there is no description of an optimal MRI protocol for detection of early changes in the scoliotic spine.

Goal(s): The goal is to assess the feasibility of the multi-purpose short MRI protocol based on the MR data of adult volunteers.

Approach: Based on the checklist of relevant landmarks, assessment of the volunteer MR data and identification of the landmarks was performed by 3 readers.

Results: We have demonstrated that the proposed MRI protocol, covering almost the entire spine in 14 min, is efficient for detection of relevant landmarks for: scoliosis assessment, screening for neural axis abnormalities, and surgical planning and navigation.

Impact: A short MRI protocol is developed for accurate assessment of spinal deformity in AIS patients, facilitating the treatment management, monitoring and surgical planning, and simplifying the clinical workflow.



DTI-MRI as a non-invasive assessment of extracellular matrix remodeling in lumbar paravertebral muscles of rats with sarcopenia

Xinchen Huang¹ and Bo He¹

¹The First Affiliated Hospital of Kunming Medical University, kunming, China

Keywords: Muscle, Aging

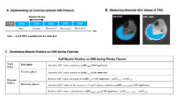Motivation: The evaluation of extracellular matrix levels in skeletal muscle often requires tissue biopsy, which is difficult for patients to accept in clinical practice

Goal(s): We evaluated the extracellular matrix level of skeletal muscle using non-invasive magnetic resonance imaging technology and conducted pathological verification using skeletal muscle samples from rats with sarcopenia

Approach: We constructed a classic sarcopenic rat model, scanned the lumbar paravertebral muscles with a 3.0T MRI-based DTI sequence, and validated through histological experiments

Results: FA and CSA of sarcopenic rats were significantly reduced compared to the normal control group, and there was a strong correlation between them and pathological related parameters

Impact: Our study provides a non-invasive tool for evaluating the extracellular matrix levels of skeletal muscles in sarcopenia



Muscle Kinetics on Diffusion-weighted Imaging during Plantar Flexion for Assessing Sex Differences in Age-related Muscle Quality

Xinyue Zhang¹, Pei Xiang¹, Kan Deng², and Zhaohui Zhang¹

¹First affiliated hospital of SYSU, Guangzhou, China, ²Philips Healthcare, Guangzhou, China

Keywords: Muscle, Aging

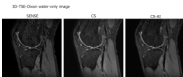
Motivation: The exercise-tailored diffusion-weighted imaging (DWI) protocol has never been implemented to assess sex differences in age-related muscle quality in the healthy population.

Goal(s): To investigate the feasibility of muscle kinetics on DWI during exercise for assessing sex differences in age-related muscle quality.

Approach: This study recruited 87 healthy participants with 174 legs imaged and assessed muscle kinetics on DWI during exercise for assessing sex differences in age-related muscle quality.

Results: Males and females showed different age-related pattern with muscle kinetics on DWI during plantar flexion.

Impact: An exercise-tailored MR protocol can be implemented for assessing the muscle quality.



3D high-resolution isotropic multi-contrast knee MRI using 3D mDixon TSE with deep learning constrained Compressed SENSE

Yasuyuki Morita¹, Michinobu Nagao¹, Masami Yoneyama², Mana Kato¹, Takumi Ogawa¹, Kazuo Kodaira¹, Yutaka Hamatani¹, Isao Shiina¹, Yasuhiro Goto¹, and Shuji Sakai¹

¹Tokyo Women's Medical University Hospital, Tokyo, Japan, ²Philips Japan, Tokyo, Japan

Keywords: Cartilage, Artifacts

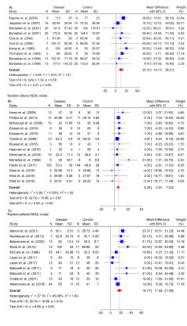
Motivation: Knee joint MRI requires m sequences involving multiple planes and with- and without fat suppression, which is time-consuming.

Goal(s): Provides detailed cartilage and ligament information in a short period of time and allows multiplanar reconstruction in any plane of any thickness from a single high-resolution isotropic imaging.

Approach: CS-AI 3D mDixon TSE images were compared with conventional SENSE and CS images.

Results: It indicated that 3D mDixon CS-AI can provide more accurate image information of cartilage and ligaments with high reproducibility and robustness.

Impact: This technique may be helpful to further assess knee pathology.



31P-MRS measured phosphocreatine recovery kinetics in human muscles during health and disease: a meta-analysis

Maninder Singh¹, Aditya Jhajharia², Rajat Pruthi³, and Owen Carmichael⁴

¹Biomedical Imaging, Pennington Biomedical Research Center, Baton Rouge, LA, United States, ²University of Maryland Baltimore, Baltimore, MD, United States, ³Louisiana State University, Baton Rouge, LA, United States, ⁴Pennington Biomedical Research Center, Baton Rouge, LA, United States

Keywords: Muscle, Spectroscopy, Skeletal muscle metabolism


Motivation: ³¹P-MRS methodology is notoriously laboratory-specific, leading to uncertainty about the normal range of PCr recovery kinetics among healthy individuals, as well correlations with disease and demographic factors.

Goal(s): Our aim was to characterize the normal range of PCr recovery measurements from ³¹P-MRS in human skeletal muscles, as well as correlations with age and end-of-exercise pH.

Approach: Included studies focused on exercise-induced skeletal muscle PCr recovery kinetics in healthy or diseased individuals, using 31P-MRS.

Results: PCr recovery time is consistent across three skeletal muscle groups in healthy individuals from diverse MRI centers. Greater age and more acidic pH increase PCr recovery time.

Impact: These results will set the indexes for PCr recovery kinetic measures across different human skeletal muscles.



The application of 3D-ZTE technique in ex vivo ankle cortical bone MRI of adolescent pigs: A comparison with CT examination

Wanjing Bai¹, Xian Xiong¹, Yaqi Li¹, Lingjun Jiang¹, Xiyang Song¹, Xiaoxuan Li¹, and Huilou Liang²

¹West China Second University Hospital, Sichuan University, Chengdu, China, ²GE HealthCare MR Research, Beijing, China

Keywords: Bone, MSK, ZTE

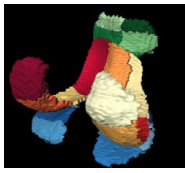
Motivation: Exploring non-ionizing radiation alternatives to CT examination for diagnosing bone diseases in children is clinically desirable.

Goal(s): To compare the visualization of the bone cortex around ankle joints of adolescent pig between 3D-ZTE MRI and CT techniques.

Approach: A total of 12 specimens were subjected to both 3D-ZTE MRI and CT examination. The thicknesses of bone cortex were measured and compared between MRI and CT images.

Results: There was no significant difference in the thicknesses of bone cortex in the inner and outer sides of tibia, fibula, and talus between 3D-ZTE and CT.

Impact: 3D-ZTE technique can obtain CT-like images that accurately measure the thickness of bone cortex without ionizing radiation. This technique holds the potential for clinical applications in children with bone diseases, providing a safe alternative to traditional CT imaging.



Quantitative MRI assessment of knee joint cartilage in pediatric hemophilic arthropathy using automated cartilage segmentation technique

Yangying Kuang¹, Hua Lai¹, Esther Raithel², and Yunzhu Wu³

¹Department of Radiology, Chengdu Women's and Children's Central Hospital, Chengdu, China, ²Siemens Healthineers AG, Forchheim, Germany, ³MR Research Collaboration Team, Siemens Healthineers Ltd., Shanghai, China

Keywords: Rare Disease, Cartilage

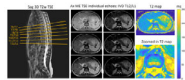
Motivation: To offer a quantitative imaging marker for monitoring of hemophilic joints.

Goal(s): To assess knee joint cartilage changes in children with hemophilic arthropathy(HA) using automated segmentation and explore their connection with Hemophilia Joint Health Scores(HJHS).

Approach: MRI were conducted on children with HA and healthy children using advanced techniques and automated cartilage segmentation to evaluate knee joint cartilage and their associations with HJHS.

Results: Significant differences in T1 and T2* values were found between HA and healthy controls, with positive correlations between T1 values in specific regions and HJHS, along with negative correlations between cartilage volume in specific regions and HJHS.

Impact: MRI techniques such as T1 mapping and T2* mapping hold promise for quantitatively assessing early-stage knee joint cartilage damage in HA, and show identifiable correlations with HJHS.



T2 relaxation times of the thoracic intervertebral discs in children 8 to 10 years old.

Yulia M Shcherbakova¹, Tijl A van der Velden^{1,2}, Peter P.G. Lafranca³, Rene M. Castelein³, Tom P.C. Schlosser³, Keita Ito^{3,4}, and Peter R Seevinck^{1,2}

¹Department of Radiology, Image Sciences Institute, UMC Utrecht, Utrecht, Netherlands, ²MR guidance B.V., Utrecht, Netherlands, ³Department of Orthopaedics, UMC Utrecht, Utrecht, Netherlands, ⁴Department of Biomedical Engineering, Eindhoven University of Technology, Eindhoven, Netherlands

Keywords: MSK, Relaxometry, IVD, Spine, MSK, T2, NP, adolescence

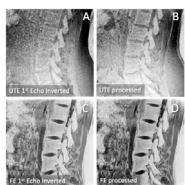
Motivation: T₂ relaxation time is a promising biomarker for the hydration and maturation state of the IVD in children, however, very little is known about it.

Goal(s): The goal is to provide the baseline for T₂ relaxation times in thoracic IVDs in children.

Approach: T₂ relaxometry performed in thoracic IVDs of 10 children.

Results: In children: highest T₂ values are in the core of Nucleus Pulposus (200-270 ms), T₂ values in the Nucleus Pulposus - Annulus Fibrosus transition zone (110-130 ms) are more similar to those in adult NP tissue. This result is consistent with higher water content expected in pediatric vs. adult NP tissue.

Impact: T₂ values of healthy subjects can be used for the assessment of IVDs in children, opening new avenues to monitor developmental spine disease, research lower back pain as well as potential treatments.



Ultrashort Echo Time and Fast Field Echo Imaging and Processing for Spine Bone Imaging in Spondylolysis

Diana Vucevic¹, Yuichi Yamashita², Vadim Malis¹, Anya Mesa¹, Suraj Achar³, Mitsue Miyazaki¹, and Won C Bae^{1,4}

¹University of California, San Diego, La Jolla, CA, United States, ²Canon Medical Systems Corporation, Tochigi, Japan, ³Family Medicine, University of California, San Diego, La Jolla, CA, United States, ⁴VA San Diego Healthcare System, San Diego, CA, United States

Keywords: MSK, Adolescents, Pars Interarticularis, UTE, FE, Image Processing

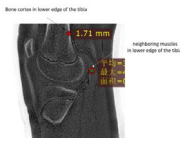Motivation: Fracture of pars interarticularis is a common injury in adolescent athletes, currently requiring CT scan for accurate diagnosis.

Goal(s): Advance MR imaging to depict spinal bone with high fidelity.

Approach: Two techniques utilizing multiecho ultrashort echo time (UTE) and field echo (FE) with simple post-processing were developed to image lumbar spinal bone. SNR and CNR were determined, and clinical utility was assessed in patients.

Results: Improvements in visual quality and bone contrast were achieved using multiecho processing as opposed to a single echo inversion. Both UTE and FE techniques provided good bone contrast, although FE provide significantly better resolution and bone-muscle contrast.

Impact: This study advances MR imaging of the pars interarticularis for evaluation of spondylolysis. We demonstrated clinical feasibility in a patient with a pars defect, depicted with clarity with the techniques described here.



AIR recon deep learning on oZTEo technique in cortical bone MRI: an ex vivo ankle joint of adolescent pig and a knee joint of adolescent child

Wanjing Bai¹, Xian Xiong¹, and Huilou Liang²

¹West China Second University Hospital, Sichuan University, Chengdu, China, ²GE HealthCare MR Research, Beijing, China

Keywords: MSK, MSK, oZTEo, DL

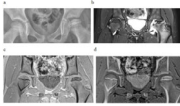
Motivation: Exploring oZTEo sequence with NEX=2 after AIR recon deep learning (DL) alternatives to 3D-ZTE for diagnosing bone diseases in children is clinically desirable.

Goal(s): To compare the image quality among different kinds of oZTEo sequences.

Approach: A specimen and a child were subjected to different oZTEo MRI with and without DL. The specimen was subjected to CT examination. The thicknesses of bone cortex and SNR of neighboring muscles were measured.

Results: The image quality of oZTEo CT-like with NEX=2 after AIR recon DL was superior than that with NEX=6 before AIR recon DL.

Impact: The oZTEo technique with NEX=2 after AIR recon DL, with shorter scanning time and without ionizing radiation, is a safer choice for diagnosing children bone diseases.



“Black Bone” MRI: a potential alternative to X-ray with three-dimensional reconstruction for the diagnosis of Legg-Calvé-Perthes disease

Xiamei Zhuang¹, Ke Jin¹, and Huiting Zhang^{1,2}

¹Hunan Children's Hospital, Changsha, China, ²MR Collaboration, Siemens Healthineers Ltd, Wuhan, China

Keywords: Bone, Bone

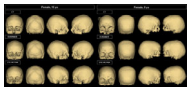
Motivation: Femoral head necrosis can be clearly displayed by Black Bone MRI.

Goal(s): This study aimed to investigate the diagnostic performance of MR imaging with Black Bone sequence in the lateral pillar classification and femoral head extrusion index of Legg-Calvé-Perthes disease (LCPD) in children.

Approach: The study included thirty-eight children with LCPD who underwent both X-ray and MR scans. The diagnostic performance of Black Bone MRI was assessed in comparison to X-ray.

Results: The results showed that Black Bone had no significant difference in measuring the femoral head extrusion index compared to X-ray. For Herring classification, Black Bone MRI performed very well.

Impact: Black Bone MRI can be used as a conventional sequence for the assessment of LCPD in children, allowing patients to avoid ionizing radiation.



Ultrashort Echo Time MRI for Pediatric Patients with Craniofacial Abnormalities

Nada Kamona^{1,2}, Jingtang J. Ng³, Yohan Kim³, Brian-Tinh D. Vu^{1,2}, Brandon C. Jones^{1,2}, Hyunyeol Lee⁴, Holly Corday³, Connor Wagner³, Hee Kwon Song¹, Sandhya Konar¹, Chamith S. Rajapakse^{1,5}, Scott P. Bartlett³, and Felix W. Wehrli¹

¹Department of Radiology, University of Pennsylvania, Philadelphia, PA, United States, ²Department of Bioengineering, University of Pennsylvania, Philadelphia, PA, United States, ³Division of Plastic, Reconstructive, and Oral Surgery, Children's Hospital of Philadelphia, Philadelphia, PA, United States, ⁴School of Electronics Engineering, Kyungpook National University, Daegu, Korea, Republic of, ⁵Department of Orthopaedic Surgery, University of Pennsylvania, Philadelphia, PA, United States

Keywords: MSK, Bone


Motivation: Ionizing radiation risk from CT remains a concern for pediatric patients with craniofacial abnormalities.

Goal(s): Use high-resolution bone-selective MRI for cranial bone imaging and evaluate feasibility in pediatric patients.

Approach: We quantitatively assessed a new echo-subtraction UTE sequence against clinical CT and another well-known MRI technique to assess their strengths and limitations.

Results: The proposed UTE sequence had high agreement with CT among the 3D rendered bone segmentations in terms of Dice similarity coefficient and quantification of clinical craniometric measurements. Furthermore, the bone-selective MR images clearly depict thin bone structures with attenuation of both soft-tissues and air.

Impact: Craniofacial imaging with the proposed ultrashort echo time sequence has high agreement with CT in pediatric patients. MRI can be a reliable non-ionizing and radiation-free modality for pediatric patients who are at increased risk of radiation malignancy.



The Quantitative Parameters Derived from IDEAL-IQ in the Lumbar Vertebrae of Healthy Children: A Pilot Study of Bone Development

Jie Yang¹, Hui-miao Sun¹, Hong Yang¹, Lei Hu¹, and Jin-liang Niu²

¹Children's Hospital of Shanxi, Women Health Center of Shanxi, Taiyuan, China, ²The Second Hospital of Shanxi Medical University, Taiyuan, China

Keywords: Normal Development, Microstructure

Motivation: Early childhood bone development affects that of bone disease in adolescence and adulthood. Many diseases can affect the cancellous bone or bone marrow. Therefore, it is of great significance to quantify the bone development of healthy children.

Goal(s): To quantify the normal bone development and provide a basis for further studies focusing on diseases involving lumbar vertebrae.

Approach: This study was conducted to quantify the fat and cancellous bone content of lumbar vertebrae in healthy children based on IDEAL-IQ.

Results: As the age increased, the average PDFF and R2* both increased significantly. No association was found between the gender and PDFF, R2*.

Impact: As the age increased, the average PDFF and R2* of lumbar vertebrae both increased significantly in healthy children. These findings will probably improve our understanding of the bone development and enable differential diagnosis other diseases of children's bone.

A prospective cohort study of Nusinersen in the treatment of spinal muscular atrophy in children with type 2 and 3 on quantitative muscle MRI

Yang Huang^{1,2}, Ying-Yi Hu^{1,3}, Taiya Chen^{1,3}, Kan Deng⁴, and Queenie Chan⁵

¹Shenzhen Children's Hospital, Shenzhen, China, ²Shenzhen Pediatrics Institute of Shantou University Medical College, Shenzhen, China, ³China Medical University, Shenzhen, China, ⁴Philips Healthcare, Guangzhou, China, ⁵Philips Healthcare, Hongkong, China

Keywords: Muscle, Pediatric, neuromuscular disease

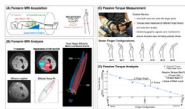
Motivation: A biomarker to assess the efficacy of Nusinersen is needed as it enhances motor function and prolongs survival in SMA patients.

Goal(s): We investigated whether qMRI could monitor the efficacy of Nusinersen in the treatment of SMA.

Approach: Patients underwent measurements of thigh qMRI (mDixon-Quant, T2 mapping and DTI) and Hammersmith Functional Motor Scale Expanded (HFMSSE) before and after nusinersen treatment, X-ray exams to obtain Cobb angle were performed at baseline.

Results: After treatment, the mean thigh FF and FA decreased over time, and the HFMSSE increased, while T2 values and ADC remain stable.

Impact: qMRI can evaluate the treatment outcomes of SMA patients. The younger patients with less scoliosis more likely to have minimum clinically significant difference at 6 months after treatment.



Investigating the relationship between diffusion MR measures and passive torques of finger flexor muscles in individuals with cerebral palsy

Divya Joshi^{1,2}, Afsheen Sajjadi^{1,2}, Julius PA Dewald^{1,2,3}, Ana Maria Acosta², Alexandra Hruby^{1,2}, and Carson Ingo^{2,4}

¹Department of Biomedical Engineering, Northwestern University, Chicago, IL, United States, ²Department of Physical Therapy and Human Movement Sciences, Northwestern University Feinberg School of Medicine, Chicago, IL, United States, ³Department of Physical Medicine and Rehabilitation, Northwestern University Feinberg School of Medicine, Chicago, IL, United States, ⁴Department of Neurology, Northwestern University Feinberg School of Medicine, Chicago, IL, United States

Keywords: Muscle, Diffusion Tensor Imaging, cerebral palsy, passive torques


Motivation: Individuals with cerebral palsy (CP) often experience atypical biomechanical properties in the hand, yet little is known regarding the *in vivo* microstructural mechanisms in the muscle that underlie these impairments.

Goal(s): This study aimed to establish the relationship between diffusion MRI measures in forearm muscles and biomechanical features of the fingers.

Approach: Diffusion MR and torque measurements were acquired in five individuals with CP. Correlations between MR measures and the passive torque at the finger joints were investigated.

Results: Passive torque was significantly correlated with muscle volume ($r=0.68, p=0.045$) and FA ($r=0.69, p=0.040$), but FA and muscle volume were not significantly correlated with one another.

Impact: Diffusion MR-derived metrics such as FA and muscle volume have potential to be clinically translatable measures for identifying altered biomechanics in individuals with cerebral palsy and other populations with neuromuscular pathologies.



Total tumor apparent diffusion coefficient histogram parameters identify ISS stages in multiple myeloma with diffuse infiltration

Jiao Li¹, Qin Wang¹, Junde Zhou¹, Dong Liu¹, Jinxia Zhu², Robert Grimm³, Huadan Xue¹, and Zhengyu Jin¹

¹Peking Union Medical College Hospital, Beijing, China, ²MR Collaboration, Siemens Healthineers Ltd, Beijing, China, ³MR Application Predevelopment, Siemens Healthcare GmbH, Erlangen, Germany

Keywords: Diffusion Analysis & Visualization, Hematologic, multiple myeloma, whole-body diffusion-weighted imaging

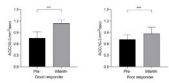
Motivation: Is there any difference in the ttADC histogram parameters at different ISS stages in multiple myeloma patients with diffuse infiltration visually?

Goal(s): The goal was to explore the difference in ttADC histogram parameters and clinical indicators in multiple myeloma patients with diffuse infiltration at different ISS stages.

Approach: The ttADC histogram parameters were obtained by sketching the lesions of the whole body on WB-DWI images using MRTTL software.

Results: Age, hemoglobin, creatinine, and ttADC_5% were different at different ISS stages.

Impact: Diffuse infiltration is generally thought to be associated with a poorer prognosis for MM patients. Our study shows that although all patients have diffuse infiltration, different ttADC histogram parameters may result in different prognosis.



Utility of diffusion-weighted magnetic resonance imaging in predicting treatment response to radiotherapy in locally advanced cervical cancer

Chunyu Liang¹, Zhiyuan Xu², and Xinping Shen¹

¹Department of Medical Imaging, Radiology Center, The University of Hong Kong-Shenzhen Hospital, Shenzhen, China,

²Department of Clinical Oncology, The University of Hong Kong-Shenzhen Hospital, Shenzhen, China

Keywords: DWI/DTI/DKI, Tumor, cervical cancer; radiotherapy; diffusion-weighted imaging; apparent diffusion coefficient


Motivation: Radiotherapy (RT) is regarded as standard therapy for locally advanced cervical cancer. To date there are no accepted modalities that can reliably predict treatment response.

Goal(s): Present study aimed to explore the baseline and interim-ADC as well as change in ADC for predicting treatment outcomes.

Approach: 80 patients underwent pelvis MRI at least three times: before treatment, during the course of RT and after completion of RT. Following values were calculated: Pre-ADC, Interim-ADC, Δ ADC and $\Delta\%$ ADC. Treatment outcome was assessed by RECIST.

Results: Pre-treatment tumor size and interim-ADC could be potential biomarkers for predicting treatment outcomes in cervical cancer patients referred for RT.

Impact: The results of present study can evaluate the early efficacy of RT, in order to allow for the timely adjustment of treatment plans, improve the efficacy and prognosis, and provide a reference for the clinical individualized treatment of cervical cancer.



Application of Cellular Microstructural Mapping (Cell size imaging) by Time-Dependent Diffusion MRI in rectal lesions: a preliminary study

Peisi Kou¹, Liangjie Lin², Ying Li¹, Kun Zhang¹, Wenhua Zhang¹, Juan Li¹, Yong Zhang¹, and Jingliang Cheng¹

¹The First Affiliated Hospital of Zhengzhou University, Zhengzhou, China, ²Advanced Technical Support, Philips Healthcare, Beijing, China

Keywords: Microstructure, Cancer

Motivation: Preoperative evaluation of rectal lesions remains challenging, we need better methods to evaluate malignant and benign lesions, and to estimate prognostic factors for rectal cancer.

Goal(s): To explore the application value of cellular microstructural mapping by td-dMRI in evaluating the histological type and prognostic factors of rectal lesions.

Approach: Sixty-six patients with rectal lesions were enrolled in this study. MRI was performed on a 3T scanner (Ingenia Elition, Philips Healthcare, Best, the Netherlands). All subjects underwent conventional MRI, oscillating gradient spin-echo (OGSE) and pulse gradient spin-echo (PGSE).

Results: Our preliminary results illustrated that td-dMRI are useful in preoperative evaluation of rectal lesions.

Impact: Cellular microstructural mapping by time-dependent diffusion MRI has great potential in preoperative evaluation of rectal lesions. The results illustrated that it could be helpful in differentiating malignant and benign lesions, distinguishing AC from MC, and in predicting the TB status.

Quantitative parameters of bone marrow segmentation on WB-DWI in the prognostic staging of R-ISS II multiple myeloma

Junde Zhou¹, Qin Wang¹, Jiao Li¹, Shuang Xia¹, Haibo Zhang¹, Jinxia Zhu², Robert Grimm³, Alto Stemmer³, Huadan Xue¹, and Zhengyu Jin¹

¹Peking Union Medical College Hospital, Beijing, China, ²MR Research Collaboration, Siemens Healthineers Ltd, Beijing, China, ³MR Application Predevelopment, Siemens Healthcare GmbH, Erlangen, Germany

Keywords: DWI/DTI/DKI, Diffusion/other diffusion imaging techniques

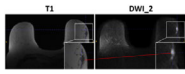
Motivation: Revised International Staging System stage II multiple myeloma (R-ISS II MM) patients have considerable prognostic heterogeneity.

Goal(s): Use quantitative parameters of bone marrow segmentation on whole-body diffusion-weighted imaging (WB-DWI) for risk stratification among R-ISS II MM patients.

Approach: Univariate and multivariate analyses of clinical features and quantitative parameters of bone marrow segmentation extracted from MR Total Tumor Load software were used to identify predictors of progression-free survival and overall survival (OS).

Results: On multivariate analysis, mean apparent diffusion coefficient (odds ratio=1.003, p=0.029, 95% confidence interval [95%CI]: 1.000-1.003) and albumin (odds ratio=0.942, p=0.051, 95%CI: 0.888-1.000) were independent predictors of OS.

Impact: Quantitative parameters of bone marrow segmentation on WB-DWI can predict OS in R-ISS II MM patients, suggesting that these parameters can facilitate prognostic assessment of R-ISS II MM patients.



How to best match voxels – evaluating different sequential co-registration strategies for ultra-high b-value DWI in multiparametric breast MRI

Luise Brock^{1,2}, Andrzej Liebert¹, Hannes Schreiter¹, Chris Ehring¹, Jessica Eberle¹, Frederik Laun¹, Michael Uder¹, Lorenz A. Kapsner^{1,3}, Sabine Ohlmeyer¹, Florian Knoll², and Sebastian Bickelhaupt¹

¹Radiology, University hospital Erlangen, Erlangen, Germany, ²Department of Artificial Intelligence in Biomedical Engineering (AIBE), Friedrich-Alexander-University Erlangen-Nuernberg, Erlangen, Germany, ³Chair of Medical Informatics, Friedrich-Alexander-University Erlangen-Nuernberg, Erlangen, Germany

Keywords: DWI/DTI/DKI, Breast

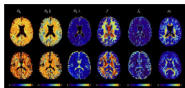
Motivation: Breast MRI increasingly includes ultra-high b-value DWI, but technical and patient-related challenges can cause mismatches to morphologic sequences. Co-registration strategies are needed to reliably apply AI-algorithms to the data.

Goal(s): The study examines how different co-registration orders for ultra-high b-value acquisitions in multiparametric breast MRI impact co-localization to morphologic sequences, both quantitatively and qualitatively.

Approach: This IRB-approved retrospective study of 144 multiparametric breast MRI exams with ultra-high b-value DWI, assessed different co-registration algorithms using ANTs library methods quantitatively and qualitatively.

Results: The sequential arrangement of contrasts used during co-registration significantly affects cross-sequence congruence of lesions in multiparametric breast MRI incorporating ultra-high b-value DWI.

Impact: The study highlights the relevance of considering different sequential arrangements used during co-registration in ultra-high b-value DWI.



Potential for white matter microstructure quantification on a clinical 7T system

Saina Asadi¹, Tommaso Pavan¹, Andreea Hertanu¹, Helene Lajous¹, Patric Hagmann¹, and Ileana Jelescu¹

¹Department of Radiology, Lausanne University Hospital (CHUV) and University of Lausanne (UNIL), Lausanne, Switzerland

Keywords: Diffusion Modeling, High-Field MRI, Microstructure

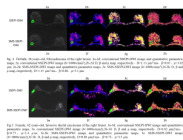
Motivation: The potential of dMRI microstructure mapping at 7 Tesla is largely unexplored, due to ultra-high field challenges related to spatial distortions and uneven excitation.

Goal(s): Assessing 7T dMRI for white matter microstructure estimation at 7T and examining the impact of acquisition protocol on model estimates.

Approach: Standard Model parameter maps were derived from two acquisition protocols ($b_{max}=3$ vs $b_{max}=13$ $ms/\mu m^2$), to further investigate the relationship between parameter estimates both at ROI and voxel level.

Results: We report high contrast-to-noise ratio microstructure maps. Our results highlight stronger region-wise and voxel-wise correlations between SM parameters in the higher b-value protocol.

Impact: The diffusion microstructure field can greatly benefit from clinically-approved high-field systems with strong gradients, with flexibility to balance SNR, spatial resolution, and $q-t$ sampling.



Differentiation of benign and malignant breast lesions using DWI with a fractional-order calculus(FROC) model based on SMS technique

Fei Wang¹, Yinan Sun¹, Qin Yang¹, Baoti Zhang¹, Mengxiao Liu², and Juan Zhu¹

¹Anqing Municipal Hospital, Anqing, China, ²MR scientific Marketing, Diagnostic Imaging, Siemens Healthineers Ltd., Shanghai, China

Keywords: Diffusion Modeling, Breast

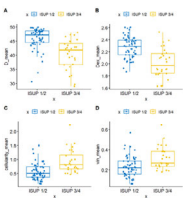
Motivation: This study focus on improving imaging time and image quality while accurately distinguishing between benign and malignant breast lesions.

Goal(s): To assess the diagnostic capabilities of the FROC diffusion model combined with SMS technology for breast lesions.

Approach: Compare two diffusion model, the traditional single-index DWI model and the FROC, and then evaluate their diagnostic performance, image quality, and the consistency of results using SMS technology.

Results: FROC combined with SMS offered a feasible and effective approach for distinguishing benign and malignant breast lesions, while the diagnostic performance of D and β values from FROC was potentially superior to the traditional ADC values.

Impact: The research introduces an innovative approach that combines the FROC-DWI model with SMS technology to enhance the efficiency and diagnostic capabilities of breast imaging, potentially improving patient outcomes and reducing unnecessary invasive procedures.



Associations between time-dependent diffusion MRI parameters and WHO/ISUP grade of clear cell renal cell carcinoma

Chunlei He¹, Yuntian Chen¹, Xiaoxiao Zhang², and Bin Song¹

¹Radiology, West China Hospital of Sichuan University, Chengdu, China, ²Department of Clinical, Philips Healthcare, China, Chengdu, China

Keywords: Microstructure, Kidney

Motivation: OGSE-MRI provides more information on kidney cancer prognosis, metastasis possibility, specific survival rate in the future.

Goal(s): To explore whether parameters derived from OGSE can demonstrate microstructure in clear cell renal cell carcinoma

Approach: Patients suspected of ccRCC who underwent diffusion-weighted imaging were employed to quantify the time-dependent diffusion MRI-based microstructural parameters cell diameter (D), intracellular volume fraction (vin), cellularity, and diffusivities (Dex).

Results: ccRCC with high WHO/ISUP grade show higher cellularity and vin, while lower D and Dex parameters.

Impact: The OGSE MRI parameters correlates with pathologic grades and demonstrates promise for characterizing renal carcinoma.



The Fuzzy MAD Glioma Conjecture, using Fuzzy C Means to classify Multimodal Apparent Diffusion for glioma stratification

Frederick C. Damen¹, Changliang Su², Thomas Anderson¹, Jay Tsuruda³, Rifeng Jiang⁴, and Kejia Cai¹

¹Radiology, University of Illinois at Chicago, Chicago, IL, United States, ²State Key Laboratory of Oncology in South China; Collaborative Innovation Center for Cancer Medicine, State Key Laboratory of Oncology in South China; Collaborative Innovation Center for Cancer Medicine, Guangzhou, Guangdong, China, ³Department of Radiology, USC Keck School of Medicine, Los Angeles, CA, United States, ⁴Radiology, Fujian Medical University Union Hospital, Fuzhou, Fujian, China

Keywords: Microstructure, Brain


Motivation: Gliomas are a very heterogeneous primary brain tumor. Their heterogeneity lies not only at the microscopic (genetic / biochemical) level, but at the mesoscopic (cellular morphology) level and macroscopic (tissue pathology) level.

Goal(s): To better understand the underpinnings of the glioma heterogeneity.

Approach: We applied the Multimodal Apparent Diffusion (MAD) method and Fuzzy C Means to multi b-value diffusion weighted magnetic resonance imaging, up to b-value of 10K s/mm², on 54 glioma patients.

Results: We discerned 15 normal appearing tissue types and 19 lesion types, including 3 voracious solid tumor, 5 recruiting solid tumor, 3 edema, and 7 b₀ attenuated types.

Impact: Each stage in the glioma's progression manifests in unique changes in MAD parameter signatures. The ability to more precisely understand the heterogeneous microstructure involved can be used to improved diagnosis and prognosis of gliomas.



Bayesian methods accurately predict ADC bias resulting from clinical diffusion-encoding gradients: Validation through simulation studies.

Matthew David Blackledge¹, Imogen Thrussell¹, and Sheng Yu¹

¹Radiotherapy and Imaging, Institute of Cancer Research, London, United Kingdom

Keywords: Simulation/Validation, Diffusion/other diffusion imaging techniques, Bayesian Analysis

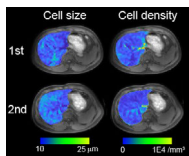
Motivation: Measurement of ADC in body DWI is typically assumed to be isotropic and therefore the use of single-direction diffusion encoding imaging is commonplace. Estimation of induced bias by this assumption is needed.

Goal(s): To determine whether Bayesian estimation of ADC measurement bias from DTI data suffers from any systematic errors and thus can be used reliably in clinical datasets.

Approach: We use simulation studies over a range of true fractional-anisotropy (FA), signal-to-noise ratio (SNR) and mean-diffusivity parameters, and investigate the accuracy of Bayesian estimation approaches.

Results: Bayesian estimation of ADC bias appears accurate over the range of tested parameters.

Impact: Accurate estimation of ADC bias from single-direction diffusion-encoding schemes is possible using Bayesian approaches in combination with data acquired using a multi-directional diffusion-encoding scheme. This enables pixel-wise estimation of bias and could negate the need for directly acquiring paired datasets.



Repeatability of MRI cytometry of the liver on clinical 3T scanners

xiaoyu jiang¹, Junzhong Xu², and John Gore²

¹Vanderbilt University Medical Center, Nashville, TN, United States, ²Vanderbilt University Medical Center, nashville, TN, United States

Keywords: Microstructure, Diffusion/other diffusion imaging techniques

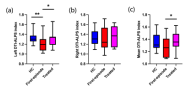
Motivation: Noninvasive measurement of liver cell sizes and densities is clinically important.

Goal(s): Assess the repeatability of liver cell size and density mapping using MRI cytometry, a diffusion MRI-based imaging technique.

Approach: In vivo MRI cytometry was repeated twice with intervals of 2-7 days for six healthy subjects.

Results: MRI-derived liver cell size and density exhibited high repeatability, with significant correlations ($r^2 = 0.89$ and 0.91 for cell size and cell density, respectively; [$P < 0.0001$]).

Impact: Our findings indicate that a liver MRI cytometry protocol can be implemented on standard clinical 3T scanners with satisfactory repeatability in under 12 minutes, thus affirming the potential for broader clinical adoption in the future.



Impact of rTMS on the glymphatic system in patients with first-episode depression before and after treatment

Ma Laiyang¹, Huang Wenjing¹, Hu Wanjun¹, Zhang Jing¹, and Yuhui Xiong²

¹Lanzhou University Second Hospital, Lanzhou, China, ²GE HealthCare MR Research, Beijing, China, Beijing, China

Keywords: Diffusion Reconstruction, Tractography & Fibre Modelling, rTMS, first-episode depression

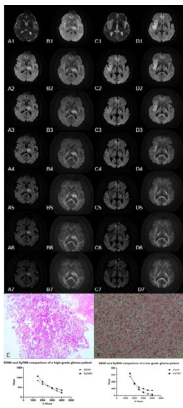
Motivation: The neuropathological mechanisms of repetitive transcranial magnetic stimulation (rTMS) for the treatment of depression are unclear.

Goal(s): The aim of this study was to explore the effects of rTMS on the brain glymphatic system using Diffusion MR Technique in patients with first-episode depression before and after treatment.

Approach: Diffusion tensor image analysis along the perivascular space (DTI-ALPS) as a non-invasive method for evaluating the activity of the glymphatic system in human brain by using diffusion images.

Results: The left ALPS index of patients with first-episode depression is lower than that of healthy people, and it is increased after rTMS treatment.

Impact: This study demonstrated the DTI-ALPS method to assess lymphatic system activity in first-episode depression patients before and after rTMS treatment. The abnormality of ALPS index may provide a potential biomarker for explaining depression, and rTMS can cause changes in ALPS.



Synthetic high-b-value MUSE DWI in preoperative differentiation of high-grade glioma from low-grade glioma

ZiYang Chen¹, Weiyin Vivian Liu², EnFu Du¹, Wen Chen¹, and Ru Tong¹

¹Department of Radiology, Taihe Hospital, Hubei University of Medicine, Shiyan 442000, China, ShiYan, China, ²GE Healthcare, MR Research China, Beijing, TaiWan, China

Keywords: DWI/DTI/DKI, Diffusion/other diffusion imaging techniques

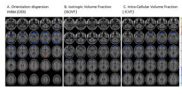
Motivation: High-b-value diffusion weighted imaging (DWI) and apparent diffusion coefficient (ADC) with b value = 3000 s/mm² are independent predictors of overall survival.

Goal(s): To explore the feasibility of synthetic high-b-value DWI and ADC values in diagnosis of glioma using actually scanned ones as standard reference.

Approach: To assess scanned and synthetic multiple high-b-value MUSE DWI and ADC of 5 patients with low-grade glioma and 3 patients with high-grade glioma.

Results: All synthetic high-b-value DWIs had superior image quality and diagnostic efficacy of glioma to all scanned DWIs. The scanned and synthetic ADC were significantly different between different b values.

Impact: Synthetic high-b-value MUSE DWI can provide better image quality and diagnostic efficiency of grading glioma without consuming extra scan time, encouraging us to promote the utility of setting up synthetic high-b-value MUSE DWI as routine.



Microstructural Abnormalities of Grey Matter and White Matter in Children with Basic-type Intermittent Exotropia using NODDI Technology

Huixin Li¹, Qinglei Shi², Jie Hong¹, Jie Hao¹, Zhengyong Chen³, Mengdi Zhou⁴, Haoran Zhang³, Xianchang Zhang⁵, Xiang Wan⁶, Zhaohui Wan⁴, and Jing Fu¹

¹Beijing Tongren Hospital, Beijing Eye Center, Beijing, China, ²Chinese University of Hong Kong (Shenzhen) School of Medicine, Shenzhen Research Institute of Big Data, Hong Kong, China, ³Chinese University of Hong Kong (Shenzhen) School of Data Science, Hong Kong, China, ⁴Department of Radiology, Beijing Tongren Hospital, Beijing, China, ⁵MR Research Collaboration, Siemens Healthineers Ltd., Beijing, China, ⁶Shenzhen Research Institute of Big Data, Hong Kong, China

Keywords: Microstructure, Diffusion/other diffusion imaging techniques, NODDI; intermittent exotropia; microstructural changes; TBSS; binocular function


Motivation: Intermittent exotropia (IXT) is quite common in children. The exact pathogenesis is not clear, which makes it difficult to make early diagnosis and evaluate progression.

Goal(s): To investigate the microstructural changes in vivo in children with IXT and explore the potential neuropathological mechanisms.

Approach: 31 IXT children and 37 controls were enrolled. Brain gray matter (GM) and the white matter (WM) regions extracted from their whole-brain MRI data were compared using the NODDI technology and TBSS method.

Results: Microstructural changes in GM and WM between the two groups were found, located in the visual perception and oculomotor control associated areas.

Impact: The parameters derived from NODDI can demonstrate the microstructural abnormalities in primary, advanced visual center and oculomotor center pathway, which maybe a potential tool in diagnosis and evaluation the IXT patients.



Diffusion-relaxation correlation spectroscopic imaging for evaluating change of white matter of X-linked adrenoleukodystrophy

Xingang Wang¹, Ru Wen¹, Shaoxin Xiang², Wang Zhe³, Yuxin Yang², Liang Tan¹, and Chen Liu¹

¹Army Medical University (Third Military Medical University), Chongqing, China, ²United Imaging Research Institute of Intelligent Imaging, Beijing, China, ³United Imaging Healthcare Group, Shanghai, China

Keywords: Diffusion Analysis & Visualization, Diffusion/other diffusion imaging techniques

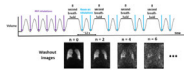
Motivation: Diffusion-relaxation correlation spectroscopic imaging (DR-CSI) may be a useful tool for advancing our understanding of X-linked adrenoleukodystrophy (ALD) and its impact on white matter.

Goal(s): To measure the changes in white matter composition and microenvironment in ALD patients using DR-CSI.

Approach: Recruited four groups of participants. DR-CSI was utilized with a multi-parametric approach, considering both diffusion and relaxation properties to provide a comprehensive view of the tissue microenvironment. Data analysis was performed to quantify changes in white matter composition.

Results: In the context of ALD, DR-CSI can effectively differentiate between the diverse tissue compartments by examining diffusion and relaxation characteristics.

Impact: This is of significant relevance for the diagnosis and treatment strategies of this rare disease. Moreover, the study results offer information regarding differences among ALD phenotypes, which holds potential value for individualized treatment and management development.



Feasibility of Volumetric Multiple-Breath Washout ^{19}F -Perfluoropropane Ventilation Mapping of the Lung in Healthy Children

Faiyza Shoaib Alam^{1,2}, Brandon Zanette², Daniel Li², Sharon Braganza², Mary A. Neal³, Peter E. Thelwall³, Felix Ratjen^{2,4}, and Giles Santyr^{1,2}

¹Medical Biophysics, University of Toronto, Toronto, ON, Canada, ²Translational Medicine, The Hospital for Sick Children, Toronto, ON, Canada, ³Newcastle University, Newcastle upon Tyne, United Kingdom, ⁴Division of Respiratory Medicine, The Hospital for Sick Children, Toronto, ON, Canada

Keywords: Non-Proton, Pediatric, lung


Motivation: Multiple-breath washout (MBW) MRI following exhalation of a tracer gas results in regional maps of fractional ventilation (FV). Using perfluoropropane (PFP) gas allows for long washout experiments which may provide useful clinical insight on slow-filling regions of diseased lungs, particularly in children.

Goal(s): Test feasibility of MBW PFP-MRI in pediatric healthy participants, investigate gravitational dependence of FV.

Approach: 3 healthy pediatric participants were imaged using 3D broad-banded ^{19}F -MRI and the following MBW maneuver: 6 inhalations of PFP gas mixture, then wash-out with room air with 8s MR-images every second breath.

Results: MBW PFP-MRI was feasible in children. The gravitational gradient was as expected.

Impact: The ability of PFP to be mixed with oxygen and the fact that it is thermally polarized makes longer MBW studies possible and thus has the potential to improve tolerance by younger subjects and those with more advanced lung disease.



The effect of $[6,6'\text{-}^2\text{H}_2]$ glucose dose on human brain deuterium metabolic imaging at 7T

Narjes Ahmadian¹, Maaïke Konig², Mark Gosselink², Ayhan Gursan², Sigrid Otto³, Kiki Tesselaar³, Pieter van Eijdsden⁴, Dennis Klomp², Jeanine Prompers², and Evita Wiegers²

¹Radiology and Neurosurgery, UMC Utrecht, Utrecht, Netherlands, ²Radiology, University Medical Center Utrecht, Utrecht, Netherlands, ³CTI Lab support, University Medical Center Utrecht, Utrecht, Netherlands, ⁴Neurosurgery, University Medical Center Utrecht, Utrecht, Netherlands

Keywords: Deuterium, Spectroscopy

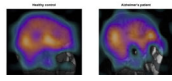
Motivation: Deuterium metabolic imaging (DMI) is used to study metabolic processes, but the effect of varying substrate doses on DMI data in the brain is not yet known

Goal(s): Comparing different doses aims to reduce cost, while still achieving sufficient sensitivity for DMI

Approach: Three healthy participants received different doses of $[6,6'\text{-}^2\text{H}_2]$ glucose on two occasions and underwent dynamic 7T DMI scans

Results: In 120-minutes after ingesting $[6,6'\text{-}^2\text{H}_2]$ glucose, there is no clear difference in the signal of ^2H -glucose/ ^2H -Glx in the brain between the 0.50-0.75g/kg doses. However, there was an earlier decrease in the signal when using the 0.25g/kg dose in one subject.

Impact: We compared three different doses $[6,6'\text{-}^2\text{H}_2]$ glucose for Deuterium Metabolic Imaging of the brain, at 7T. Metabolite signals were comparable for the 0.50g/kg and 0.75g/kg doses, making 0.50g/kg a potential cost-saving alternative for clinical translation.



Comparison of Deuterium Metabolic Imaging and FDG-PET in Alzheimer's Disease

Nikolaj Bøgh¹, Malene Aastrup¹, Janne K Mortensen², Hanne Gottrup², Jakob Blicher³, Rolf F Schulte⁴, Per Borghammer¹, Mattias Hedegaard Kristensen¹, Esben Søvsø Szocska Hansen¹, Michael Vaeggemose^{1,4}, and Christoffer Laustsen¹

¹Aarhus University, Aarhus, Denmark, ²Aarhus University Hospital, Aarhus, Denmark, ³Aalborg University Hospital, Aalborg, Denmark, ⁴GE Healthcare, Munich, Germany

Keywords: Deuterium, Deuterium


Motivation: Distinguishing Alzheimer's Disease from other dementias is becoming increasingly important with the development of amyloid-targeting therapies. This requires extensive clinical and preclinical work-up, often including structural and molecular brain imaging.

Goal(s): To compare deuterium metabolic imaging (DMI) with routinely used clinical imaging technologies for the detection of Alzheimer's Disease.

Approach: We performed a prospective clinical trial of 5 healthy age-matched controls compared with 10 patients with Alzheimer's dementia.

Results: Deuterium metabolic imaging showed decreased metabolism in temporal and parietal brain regions in patients with Alzheimer's disease compared with healthy controls. This hypometabolic pattern correlated well with FDG-PET.

Impact: This preliminary study suggests that metabolic imaging in suspected dementia may be performed with DMI. This would allow simultaneous imaging of structural, vascular, and metabolic changes at a cost comparable to FDG-PET.



Physiological Interpretation of the AUC Ratio for Hyperpolarized [1-13C]-Pyruvate

Ryan Boyce^{1,2}, Collin Harlan^{1,3}, Qing Wang¹, and James Bankson^{1,3}

¹Imaging Physics, University of Texas MD Anderson Cancer Center, Houston, TX, United States, ²Department of Physics, University of Houston, Houston, TX, United States, ³UTHealth Graduate School of Biomedical Sciences, University of Texas MD Anderson Cancer Center, Houston, TX, United States

Keywords: Hyperpolarized MR (Non-Gas), Modelling

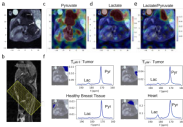
Motivation: The prevalence of the use of AUC ratio as a metric of anaerobic respiration in hyperpolarized pyruvate studies motivates a careful examination of its physiological interpretation.

Goal(s): We seek to characterize the lactate to pyruvate AUC ratio as a surrogate for aerobic glycolysis in cancer cells.

Approach: A simplified three-compartment kinetic model is proposed and analyzed. The AUC ratio is found from the model for interpretation.

Results: The simplified three-compartment model is shown to produce equivalent time curves to the full model. The AUC ratio, parametrized by the simplified model, varies non-linearly with the rate of intracellular lactate production.

Impact: The efficacy of hyperpolarized pyruvate as a probe of tumor metabolism relies on an accurate and reproducible quantification and interpretation of acquired signal. We critically examine one of the most commonly used methods of signal interpretation in hyperpolarized pyruvate studies.



In Vivo Imaging of Tumor Metabolic Heterogeneity Using [1-¹³C]Pyruvate-d₃ Hyperpolarized By Reversible Exchange With Parahydrogen

Stefan Petersen¹, Philipp Groß^{1,2}, Luca Nagel³, Robert Willing^{1,2}, Lisa Heß⁴, Julia Mitschke⁴, Nicole Klemm⁴, Christoph A. Müller⁵, Stephan Knecht⁵, Moritz Weigt¹, Michael Bock¹, Dominik von Elverfeldt¹, Maxim Zaitsev¹, Eduard Y. Chekmenev⁶, Jan-Bernd Hövener⁷, André F. Martins^{8,9}, Franz Schilling^{3,10}, Thomas Reinheckel^{2,4}, and Andreas B. Schmidt^{1,2,6}

¹Division of Medical Physics, Department of Diagnostic and Interventional Radiology, Faculty of Medicine, University of Freiburg, University Medical Center Freiburg, Freiburg 79106, Germany, ²German Cancer Consortium (DKTK), partner site Freiburg, German Cancer Research Center (DKFZ), Heidelberg 69120, Germany, ³Department of Nuclear Medicine, School of Medicine, Klinikum rechts der Isar, Technical University of Munich, Munich 81675, Germany, ⁴Institute of Molecular Medicine and Cell Research, Faculty of Medicine, University of Freiburg, Freiburg 79104, Germany, ⁵NVision Imaging Technologies GmbH, Ulm 89081, Germany, ⁶Department of Chemistry, Integrative Biosciences (Ibio), Karmanos Cancer Institute (KCI), Wayne State University, Detroit 48202, MI, United States, ⁷Sektion Biomedizinische Bildgebung, Molecular Imaging North Competence Center MOINCC, Klinik für Radiologie und Neuroradiologie, University Hospital Schleswig-Holstein, Kiel University, Kiel, Germany, ⁸Werner Siemens Imaging Center, Department of Preclinical Imaging and Radiopharmacy, Eberhard Karls University Tübingen, Tübingen 72076, Germany, ⁹German Cancer Consortium (DKTK), partner site Tübingen, German Cancer Research Center (DKFZ), Heidelberg 69120, Germany, ¹⁰German Cancer Consortium (DKTK), partner site Munich, German Cancer Research Center (DKFZ), Heidelberg 69120, Germany

Keywords: Hyperpolarized MR (Non-Gas), Contrast Agent

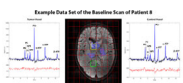
Motivation: Hyperpolarized [1-¹³C]pyruvate MRI is promising for studying cancer metabolism and assessing early therapy response but requires high-throughput and less complex hyperpolarization techniques for wide availability.

Goal(s): Demonstrating metabolic imaging in a genetic mouse model of metastasizing breast cancer (MMTV-PyMT) using purified [1-¹³C]-pyruvate-d₃ hyperpolarized via parahydrogen-based Signal Amplification By Reversible Exchange (SABRE).

Approach: Our rapid (6 min) and efficient hyperpolarization method yielded highly-polarized (>10%) [1-¹³C]-pyruvate-d₃ in safe aqueous solutions.

Results: Administered to two PyMT-mice, ¹³C chemical shift imaging detected the injected pyruvate and metabolized [1-¹³C]-lactate. Analysis revealed elevated lactate levels in tumors compared to healthy breast tissue, highlighting tumor compartments with distinct metabolic profiles.

Impact: We showcase our rapid, cost-effective SABRE hyperpolarization approach, yielding safe, highly-polarized pyruvate for inaugural cancer metabolic investigations. This innovation expands high-throughput preclinical HP-MRI research, enabling comprehensive exploration of tumor biology, metabolic processes, and therapeutic responses in cancer.



31P MRSI in Pediatric Low Grade Gliomas During Treatment at 7T

Philipp Lazen^{1,2}, Karleen T. Oonk³, Iris V. Obdeijn⁴, Dennis W. J. Klomp³, Sabine L. A. Plasschaert⁴, Maarten H. Lequin^{3,4}, Giorgio L. Porro⁵, Gilbert Hangel^{1,2}, Evita C. Wieggers³, and Jannie P. Wijnen³

¹Department of Neurosurgery, Medical University of Vienna, Vienna, Austria, ²Department of Biomedical Imaging and Image-guided Therapy, Medical University of Vienna, Vienna, Austria, ³Department of Radiology, University Medical Center Utrecht, Utrecht, Netherlands, ⁴Princess Máxima Center for Pediatric Oncology, Utrecht, Netherlands, ⁵Department of Ophthalmology, University Medical Center Utrecht, Utrecht, Netherlands

Keywords: Non-Proton, Pediatric, Brain tumor, 7T, Neuro, 31P

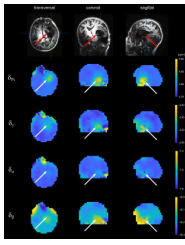
Motivation: Treatment monitoring in pediatric brain tumors is often challenging. Non-invasive tools are needed to assess tumor activity accurately.

Goal(s): To monitor changes in phospholipid metabolism (i.e., phosphomonoesters/phosphodiester [PME/PDE]) in pediatric low grade gliomas.

Approach: Eleven pediatric brain tumor patients underwent 31P-MRSI at 7T. PME/PDE in the tumor was compared to a normal-appearing brain voxel. Clinical outcomes were assessed, and results were compared between treatment and wait-and-scan groups.

Results: Tumors selected for treatment showed higher PME/PDE ratios at baseline, hinting at potential aggressiveness. These ratios decreased during treatment but remained stable in the wait-and-scan group.

Impact: Treatment monitoring in pediatric brain tumors is often challenging. Using 31P-MRSI we showed that tumors selected for treatment exhibited higher PME/PDE, signifying potential tumor aggressiveness. PME/PDE levels decreased during treatment, indicating potential for non-invasive assessment of treatment effects.



Analysis of ^{31}P chemical-shift signatures of high-energy phosphates in glioma patients measured at 7 Tesla

Vanessa L. Franke¹, Bela Seng^{1,2}, Justyna Platek^{1,2,3}, Nina Weckesser⁴, Heinz-Peter Schlemmer^{4,5}, Daniel Paech^{4,6}, Mark E. Ladd^{1,2,5}, Peter Bachert^{1,2}, and Andreas Korzowski¹

¹Division of Medical Physics in Radiology, German Cancer Research Center (DKFZ), Heidelberg, Germany, ²Faculty of Physics and Astronomy, Heidelberg University, Heidelberg, Germany, ³International Max Planck Research School for Quantum Dynamics in Physics, Chemistry, and Biology (IMPRS-QD), Max Planck for Nuclear Physics (MPIK), Heidelberg, Germany, ⁴Division of Radiology, German Cancer Research Center (DKFZ), Heidelberg, Germany, ⁵Faculty of Medicine, Heidelberg University, Heidelberg, Germany, ⁶Division of Neuroradiology, University Hospital Bonn, Bonn, Germany

Keywords: Non-Proton, Spectroscopy, Phosphorus, ^{31}P , pH, magnesium, glioma


Motivation: The detailed characterization of tumor micro-environment can be supported by ^{31}P MRSI enabling the non-invasive determination of pH and magnesium ion content (*Mg*).

Goal(s): The aim of this study was to investigate whether a discrimination between different glioma micro-environments might be possible based on the differences in ^{31}P chemical-shift signatures.

Approach: For this purpose, ^{31}P MRSI datasets from 12 patients with glioma acquired at 7T were analyzed and used to estimate the underlying pH and *Mg* values.

Results: For the analyzed cohort, different trends in ^{31}P chemical-shift signatures, as well as in pH and *Mg* values were observed for different tumor subtypes.

Impact: The analysis of ^{31}P chemical-shift signatures in glioma patients could potentially be used for stratifying tumor subtypes, and might help in the characterization of tumor microenvironments, e.g. by determining potential biomarkers such as pH and the magnesium ion content.



Robustness of Fitting Frequency-Domain Phased ^{129}Xe Magnetic Resonance Spectra versus Unphased Temporal Domain Free Induction Decays

Haoran Dai¹ and Bastiaan Driehuis^{1,2}

¹Medical Physics Graduate Program, Duke University, Durham, NC, United States, ²Department of Radiology, Duke University, Durham, NC, United States

Keywords: Hyperpolarized MR (Gas), Hyperpolarized MR (Gas)


Motivation: Hyperpolarized (HP) ^{129}Xe magnetic resonance (MR) spectroscopy provides useful biomarkers of gas exchange. Some groups analyze phased spectra in the frequency domain, while others employ time-domain fitting. However, these two approaches have never been compared to determine the reliability of the metrics resulting from each approach.

Goal(s): This study compares the feasibility, sensitivity, and repeatability of these two methodologies.

Approach: ^{129}Xe MRS acquired at 3 Tesla from 242 scans—include 55 repeated measurements of 110 scans—was evaluated using both methods.

Results: Time-domain fitting was applicable to all scans, yielded more physiologically plausible chemical shifts and were more repeatable.

Impact: Fitting ^{129}Xe spectra acquired at 3 Tesla in the temporal domain outperforms phase correcting and fitting spectra in the frequency domain.



Assessing Cross-Site Variability in ^{129}Xe Spectroscopy Measurements Across Major Scanner Platforms

Suphachart Leewiwatwong¹, Aryil Bechtel², David Mummy², Shuo Zhang², Junlan Lu³, Zackary Cleveland⁴, Matthew Willmering⁴, Juan Parra-Robles⁴, Sean Fain⁵, Andrew D Hahn⁵, and Bastiaan Driehuys^{1,2,3}

¹Biomedical Engineering, Duke University, DURHAM, NC, United States, ²Radiology, Duke University, DURHAM, NC, United States, ³Medical Physics Graduate Program, Duke University, DURHAM, NC, United States, ⁴Cincinnati Children's Hospital Medical Center, Cincinnati, OH, United States, ⁵Radiology, University of Iowa, Iowa City, IA, United States

Keywords: Hyperpolarized MR (Gas), Hyperpolarized MR (Gas)

Motivation: Hyperpolarized ^{129}Xe gas exchange magnetic resonance spectroscopy (MRS) lacks standardized healthy reference values.

Goal(s): To standardize ^{129}Xe gas exchange MRS biomarker reference values across different MRI systems and estimate a T2* for consistent analysis of ^{129}Xe gas exchange MRI.

Approach: Healthy 18-30 yr old non-smokers underwent ^{129}Xe MRS using the consortium recommended protocol across three research centers and three different MRI vendors.

Results: Findings indicated consistent RBC-to-membrane ratios across sites but slight differences in RBC shifts, oscillation amplitudes, and T2* values.

Impact: Establishing healthy reference values for multi-site ^{129}Xe spectroscopy will facilitate its incorporation into collaborative respiratory research.

Body: Contrast Mechanisms: Body Applications

Exhibition Hall (Hall 403)

Thursday 9:15 - 10:15

5085

Efficacy of gadopixelenol in contrast-enhanced MRI of the breast: a post-hoc analysis.

Christiane Kuhl¹ and Alex Merkulov²

¹Department of Diagnostic and Interventional Radiology, Aachen University Hospital, Aachen, Germany, ²University of Connecticut Health Center, Farmington, CT, United States

Keywords: Breast, Breast, gadopixelenol; MRI; breast

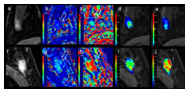
Motivation: Gadolinium dose reduction while maintaining MRI diagnostic efficacy is crucial.

Goal(s): Compare gadopixelenol (0.05 mmol/kg) and gadobutrol (0.1 mmol/kg) in breast MRI.

Approach: Post-hoc analysis on 70 patients with breast lesions from the PROMISE phase III study. Lesion visualization was qualitatively (border delineation, internal morphology, contrast enhancement) and quantitatively (enhancement percentage [E%], lesion-to-background ratio [LBR]) evaluated by three blinded readers. Three additional readers assessed diagnostic preference.

Results: Gadopixelenol was non-inferior to gadobutrol for all qualitative visualization parameters. E% was higher with gadopixelenol, while LBR was similar between the two GBCAs. Readers had in most cases no preference between images with the two GBCAs.

Impact: Gadopixelenol at half the gadolinium dose compared to current GBCAs can be particularly beneficial in patients receiving multiple lifetime doses, such as high-risk women undergoing breast cancer screening.



Comparative Quantitative Analysis in Ultrafast DCE Breast MRI: Population-Based Versus Individual Arterial Input Functions

Tianwen Xie^{1,2}, Qiufeng Zhao³, Caixia Fu⁴, Grimm Robert⁵, Marcel Dominik Nickel⁵, Weijun Peng^{1,2}, and Yajia Gu^{1,2}

¹Radiology, Fudan University Shanghai Cancer Center, Shanghai, China, ²Oncology, Shanghai Medical College, Fudan University, Shanghai, China, ³Radiology, Longhua Hospital, Shanghai University of Traditional Chinese Medicine, Shanghai, China, ⁴MR Applications Development, Siemens Shenzhen Magnetic Resonance Ltd., Shenzhen, China, ⁵MR Application Predevelopment, Siemens Healthineers AG, Erlangen, Germany

Keywords: Breast, Breast, Cancer

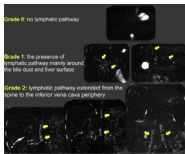
Motivation: CAIPIRINHA-Dixon-TWIST-VIBE (CDTV) ultrafast dynamic contrast-enhanced MRI helps in characterizing breast cancer.

Goal(s): However, no study has compared the accuracies of quantitative analysis using population-based arterial input function (P-AIF) and individual AIF (I-AIF) for diagnosing breast cancer.

Approach: This study aimed to evaluate and compare the diagnostic accuracies of the inline quantitative analysis with P-AIF and I-AIF in diagnosing breast cancer.

Results: It demonstrated a similarity in the quantitative analysis using P-AIF from CDTV and I-AIF in characterizing breast lesions.

Impact: This study transforms breast cancer diagnosis by validating P-AIF's efficiency in CDTV MRI, offering prospects for streamlined, faster clinical application. It encourages exploration into broader adaptations, aiming to provide the accurate diagnosis and prognosis through expedited, accessible testing methodologies.



Lymphatic congestion in Fontan circulation demonstrated by Gd-EOB-DTPA magnetic resonance lymphangiography.

Akihiro Inoue¹, Michinobu Nagao¹, Atsushi Yamamoto¹, Reiko Sakai¹, Satoru Morita¹, Masami Yoneyama², and Shuji Sakai¹

¹Tokyo Women's Medical University Hospital, Tokyo, Japan, ²Philips health care, Tokyo, Japan

Keywords: Liver, Contrast Agent, Fontan circulation

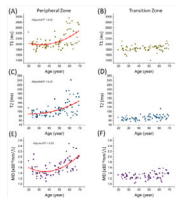
Motivation: In the Fontan circulation, congestive liver and lymphatic congestion caused by elevated central venous pressure become permanent. These complications (called as FALD) are considered poor prognostic factors as Fontan-associated liver disease, and hyperplasia of abnormal lymphatic pathway have often been seen.

Goal(s): We attempt to depict abnormal lymphatic pathway using Gd-EOB-DTPA MRI and propose a classification of their severity.

Approach: MR lymphangiography was scanned using three-dimensional heavily T2-weighted imaging with a 3-tesla scanner 10 minutes after Gd-EOB-DTPA administration. Patients were classified into the three grades.

Results: MR lymphangiography with Gd-EOB-DTPA, demonstrates the localization and extent of the abnormal lymphatic pathways in Fontan circulation.

Impact: In the Fontan circulation, the higher the lymphangiographic grade using MR lymphangiography with Gd-EOB-DTPA was, the more the adverse events were seen. The lymphangiographic grade is associated with the adverse events in Fontan-associated liver disease.



Quantitative MRI of the Prostate with Age: T1 Relaxation, T2 Relaxation, Mean Diffusivity, and Volume

Xiao Ma¹, Peter Seres², Adam Kinnaird³, Chris Fung², Alan Wilman^{1,2}, and Christian Beaulieu^{1,2}

¹Biomedical Engineering, University of Alberta, Edmonton, AB, Canada, ²Radiology and Diagnostic Imaging, University of Alberta, Edmonton, AB, Canada, ³Urology, University of Alberta, Edmonton, AB, Canada

Keywords: Prostate, Aging

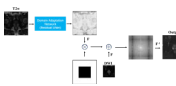
Motivation: T1 relaxation, T2 relaxation, mean diffusivity (MD) and volume can offer valuable information about prostate tissue remodeling that may occur with cancer and aging.

Goal(s): These age relationships are relevant for identification of cancer thresholds, but also provide insight on unique prostate zone changes with age.

Approach: 74 normal volunteers aged 19-69 years were scanned.

Results: T1, T2, MD and volume in the peripheral zone showed a positive quadratic association with age being mainly flat and then increasing after 45 years. In contrast, there were no such T1/T2/MD versus age correlations in the transition zone, despite a marked increase of volume with aging.

Impact: Quantitative T1/T2 relaxation and mean diffusivity demonstrate microstructural changes of the prostate, particularly in the peripheral zone and not the transition zone, with typical aging (19-69 years) which may provide a 'normative' benchmark for tumor identification.



Unsupervised Super Resolution of Diffusion Weighted Imaging Guided by High-Resolution Cross-Modality Prior

Zengtian Deng^{1,2}, Haoran Sun^{1,2}, Lixia Wang¹, Timothy J. Daskivich³, Hyung Kim³, Yibin Xie¹, and Debiao Li^{1,2}

¹Biomedical Imaging Research Institute, Cedars-Sinai Medical Center, Los Angeles, CA, United States, ²Department of Bioengineering, University of California Los Angeles, Los Angeles, CA, United States, ³Minimal Invasive Urology, Cedars-Sinai Medical Center, Los Angeles, CA, United States

Keywords: Prostate, Prostate, Super Resolution, Deep Learning, Unsupervised

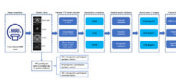Motivation: Existing supervised super-resolution is challenging for Diffusion Weighted Imaging (DWI) due to acquisition. However, the feature of T2 weighted imaging (T2w) could be utilized as a prior for unsupervised training.

Goal(s): To develop unsupervised super-resolution on DWI with the aid of high-resolution T2w images.

Approach: A UNet architecture is designed to perform same-resolution domain adaptation. During inference, the high frequency feature of the T2w images are used to fuse with the low frequency feature of original DWI in k-space to reconstruct high-resolution DWI.

Results: Our result shows improved SSIM score verified by paired student t-test. Our direct inference on HR DWI also exhibits improved sharpness.

Impact: This pilot work demonstrated that HR images (T2w) can be domain-adapted to provide high frequency prior to unsupervised super-resolution tasks using computationally efficient DL models.



Virtual gadolinium contrast enhancement MRI using deep learning GAN in rectal cancer: a proof-of-concept two-center study

Xinyi Gao¹ and Dening Ma²

¹Department of Radiology, Zhejiang Cancer Hospital, Hangzhou, China, ²Department of Colorectal Surgery, Zhejiang Cancer Hospital, Hangzhou, China

Keywords: Pelvis, Safety, rectal cancer, GBCAs, deep learning

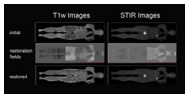
Motivation: It would be clinically beneficial if GBCAs enhancement could be accurately synthesized without any GBCAs administration though AI.

Goal(s): To evaluate the feasibility of deep learning in synthesizing VTE based on noncontrast rectal cancer MRIs obtained without the use of gadolinium.

Approach: Deep learning networks were trained and validated on nonenhanced conventional pelvic MRI (T1WI, T2WI, DWI-ADC) using GAN. MRI scans included 697 rectal cancer patients from two hospitals.

Results: Quantitative and qualitative evaluation of three-channel VTE was significantly better than that of two-channel and one-channel ($P < 0.001$). The T staging accuracy of VTE was comparable with that of RTE.

Impact: VTE synthesized by deep learning based on noncontrast MRI can overcome the limitations of RTE and aid in the clinical diagnosis and management of rectal cancer as a noninvasive, save, affordable and time-saving method that does not require GBCAs.



Restoration of Bi-contrast Whole Body MRI for Discontinuous Intensity Nonuniformities

Ismini Papageorgiou^{1,2}, Ansgar Malich¹, Lorenz Damian Rossknecht¹, and Stathis Hadjidemetriou³

¹Institute for Radiology, South Harz Hospital Nordhausen, Nordhausen, Germany, ²Institute for Diagnostic and Interventional Radiology, University Medicine of Jena, Jena, Germany, ³Department of Information Technologies, University of Limassol, Limassol, Cyprus

Keywords: Screening, Artifacts, bone metastases, signal restoration, cancer screening


Motivation: Whole-body MRI, a screening tool for bone metastatic disease, uses parallel coil imaging to cover a large Field of View. Signal inhomogeneities at the coil junction points create jump discontinuities in the signal intensity with a negative effect on serial image stitching.

Goal(s): To correct for signal jump discontinuities between coils using computer vision.

Approach: We engaged piecewise smooth intensity nonuniformities fields using anisotropic diffusion and quantified for improvement in image entropy (H).

Results: Our algorithm smoothens the signal intensity between parallel coils by 8% based on entropy metrics.

Impact: We implement a novel non-parametric methodology with piecewise smoothness to improve intensity non-uniformities between parallel coil images in whole-body MRI (WB-MRI). Optimized whole-body stitched images render WB-MRI into a one-stop-shop staging method.



Multiparametric MRI for Tumor Restaging of Locally Advanced Gastric Cancer Following Neoadjuvant Therapy

Ya-jun Hou¹, Zi-tong Sang¹, Qiong Li¹, Wei-yue Xu¹, Dominik Nickel², Yi-Cheng Hsu³, and Xi-sheng Liu¹

¹Department of Radiology, the First Affiliated Hospital with Nanjing Medical University, Nanjing, China, ²MR Application Predevelopment, Siemens Healthineers AG, Erlangen, Germany, ³MR Research Collaboration Team, Siemens Healthineers Ltd., Shanghai, China

Keywords: Digestive, Diffusion/other diffusion imaging techniques, DCE

Motivation: Accurate presurgical restaging of tumor invasion depth (ycT stage) is critical to determining appropriate therapies and evaluating outcomes for locally advanced gastric cancer after neoadjuvant therapy. Despite the reported advantages of computed tomography, its accuracy is low, with often heterogeneous results.

Goal(s): We tested the performance of multiparametric MRI for gastric cancer tumor restaging.

Approach: Three radiologists evaluated ycT stage based on T₂WI, DWI, ZOOMit DWI, and XD-VIBE DCE sequences.

Results: Multiparametric MRI provides accurate differentiation of restaging after neoadjuvant therapy. ZOOMit DWI and XD-VIBE achieved higher accuracy than did conventional T₂WI and DWI in assessing ycT stage.

Impact: Multiparametric MRI is expected to improve the accuracy of restaging gastric cancer after neoadjuvant therapy and guide decision making for clinical treatment.



Multiparametric MRI as a Diagnostic Tool for Metabolic Dysfunction-Associated Steatotic Liver Disease

Nienke P.M. Wassenaar^{1,2}, Koen C. van Son^{3,4,5}, Marian A. Troelstra¹, Stan Driessen^{3,4}, Anne Linde Mak^{3,4}, Elizabeth Shumbayawonda⁶, Max Nieuwdorp^{3,4}, Joanne Verheij^{4,7}, Aart J. Nederveen¹, Adriaan G. Holleboom^{3,4}, and Oliver J. Gurney-Champion^{1,2}

¹Radiology and Nuclear Medicine, Amsterdam University Medical Centers, Amsterdam, Netherlands, ²Imaging and Biomarkers, Cancer Center Amsterdam, Amsterdam, Netherlands, ³Vascular Medicine, Amsterdam University Medical Centers, Amsterdam, Netherlands, ⁴Amsterdam Gastroenterology Endocrinology Metabolism (AGEM) Institute, Amsterdam, Netherlands, ⁵Gastroenterology and Hepatology, Radboud University Medical Center, Nijmegen, Netherlands, ⁶Perspectum Ltd., Oxford, United Kingdom, ⁷Pathology, Amsterdam University Medical Centers, Amsterdam, Netherlands

Keywords: Liver, Quantitative Imaging, Biomarkers, Diagnosis, Elastography, IVIM, Liver

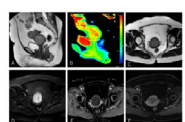
Motivation: The reference standard for diagnosing Metabolic-Dysfunction-Associated Steatotic Liver Disease (MASLD) is invasive liver biopsy. There is a need for non-invasive diagnostic methods to assess MASLD.

Goal(s): The goal was to determine if multiparametric MRI, including cT1-mapping, MR elastography, intravoxel incoherent motion diffusion-weighted MRI and proton-density fat fraction, can effectively diagnose metabolic-dysfunction-associated steatohepatitis (MASH).

Approach: The diagnostic potential of multiparametric MRI parameters was assessed in 75 MASLD patients from the ongoing Amsterdam MASLD cohort study ANCHOR.

Results: Results demonstrated that multiparametric MRI can play a role in diagnosing MASLD stages, providing an alternative non-invasive diagnostic method to liver biopsies.

Impact: This research enables non-invasive diagnosis of Metabolic-Dysfunction-Associated Steatotic Liver Disease by combining cT1, MRE stiffness, and blood marker AST. This provides an alternative to liver biopsy, allowing assessment of the entire liver, which could significantly impact clinical practice and trials.



Cervical Cancer and Paracancerous Tissue ATPw combined with DWI to predict Parametrial infiltration: An Preliminary Study

Lianze Du¹, Qinghe Han¹, Qinghai Yuan¹, and Mengdi Zhang¹

¹The Second Hospital of Jilin University, Changchun, China

Keywords: fMRI Analysis, fMRI

Motivation: Cervical cancer(CC) is one of the most common gynecological malignancies. Parametrial infiltration (PMI) is considered a decisive factor in the treatment of patients with CC.

Goal(s): This study aimed to investigate the potential of Amide proton transfer-weighted (APT_w) in predicting PMI of CC, and to further evaluate whether the APT_w parameters of paracancerous tissue can add diagnostic value to diffusion-weighted MRI of CC.

Approach: 81 participants underwent pelvic MRI , including APT_w MRI ,and takes measurements.

Results: The results showed that the APT_w values ,especially in paracancerous tissues, could be used to efficiently distinguish PMI of cervical cancer.

Impact: APT_w values ,especially in paracancerous tissues, could be used to efficiently distinguish PMI of cervical cancer. which can provide additional information to improve the results of diffusion-weighted MRI, thereby assisting further clinical decision-making and improving patient prognosis.



Evaluation of kidney injury using ASL and BOLD MRI: an experimental study in rats with CCl₄-induced liver cirrhosis

Jiaming Qin¹, Shuangshuang Xie², Yongquan Yu³, Yumeng Zhao⁴, Jiaqi Yang⁵, Caixin Qiu⁶, Xiaotian Li⁷, Cheng Zhang⁵, Zhandong Hu⁶, Jinxia Zhu⁸, Bernd Kuehn⁹, and Wen Shen⁶

¹The School of Medicine, Nankai University, Tianjin, China, ²Department of Radiology, Tianjin First Central Hospital, Tianjin, China, ³Weihai Central Hospital, Weihai, China, ⁴Department of Radiology, Nankai University, Tianjin, China, ⁵Tianjin Medical University, Tianjin, China, ⁶Tianjin First Central Hospital, Tianjin, China, ⁷Nankai University, Tianjin, China, ⁸Siemens Healthineers, Beijing, China, ⁹Siemens Healthineers AG, Erlangen, Germany

Keywords: fMRI Analysis, Animals

Motivation: Noninvasive and sensitive methods for assessing chronic liver disease-associated kidney injury are needed in clinics.

Goal(s): We investigated the potential of arterial spin labeling (ASL) and blood oxygenation level-dependent (BOLD) MRI for diagnosing and evaluating chronic liver disease-associated kidney injury progression.

Approach: We observed the renal blood flow (RBF) and T₂* changes in rats with CCl₄-induced chronic liver disease and compared imaging, pathological, and biochemical indicators at different time points.

Results: During chronic liver disease development in rats, RBF and T₂* gradually decreased, and ASL and BOLD MRI were more sensitive than serum creatinine in diagnosing renal injury.


Impact: Compared with serum creatinine, ASL and BOLD MRI exhibited more sensitive diagnostic value for liver cirrhosis-associated renal injury, providing a noninvasive and reliable method for monitoring kidney injury in patients with chronic liver disease.

Diffusion Acquisition & Reconstruction

Exhibition Hall (Hall 403)

Thursday 9:15 - 10:15

5096



Joint estimation of compartment-specific T₂ relaxation and tumor microstructure using multi-echo-time IMPULSED MRI

xiaoyu jiang¹, Kevin Harkins², zhongliang zu², jingping Xie², Jian Wang², John Gore², and Junzhong Xu²

¹Vanderbilt University Medical Center, Nashville, TN, United States, ²Vanderbilt University Medical Center, nashville, TN, United States

Keywords: Diffusion Modeling, Diffusion/other diffusion imaging techniques, cancer

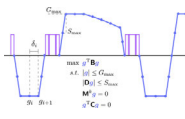
Motivation: The heterogeneity of T₂ in tumors and its influences on estimates of tissue microstructure using diffusion MRI are poorly understood.

Goal(s): Assessing how T₂ heterogeneity biases IMPULSED-derived metrics of tumor microstructure and evaluating the potential of estimating multi-compartmental T₂ and microstructural parameters simultaneously.

Approach: This study quantifies the impact of T₂ relaxation on IMPULSED-derived microstructural parameters using simulations and in vivo animal MRI in five tumor models, including brain, breast, prostate, melanoma, and colon cancer.

Results: TE has a negligible impact on IMPULSED-derived cell sizes, and the TE-dependence of IMPULSED-derived intracellular volume fractions can be used to estimate the compartmental T₂ values.

Impact: Findings in this study contribute to the ongoing development and refinement of practical, non-invasive MRI techniques for characterizing tissue microstructure.



Magnetic Resonance Fingerprinting for Simultaneous T1, T2 and ADC Mapping at 0.55T using Convex-optimized Diffusion Prepared Waveforms

Carlos Castillo-Passi^{1,2,3}, Carlos Velasco¹, Donovan Tripp¹, Karl P. Kunze^{1,4}, Radhouene Neji¹, Pablo Irarrazaval^{3,5,6}, René M. Botnar^{1,2,3,7,8}, and Claudia Prieto^{1,3,7}

¹King's College London, London, United Kingdom, ²Institute for Biological and Medical Engineering, Pontificia Universidad Católica de Chile, Santiago, Chile, ³Millennium Institute for Intelligent Healthcare Engineering, Pontificia Universidad Católica de Chile, Santiago, Chile, ⁴MR Research Collaborations, Siemens Healthcare Limited, Camberley, United Kingdom, ⁵Institute for Biological and Medical Engineering, Pontificia Universidad Católica de Chile, Santiago, Chile, ⁶Electrical Engineering Department, Pontificia Universidad Católica de Chile, Santiago, Chile, ⁷School of Engineering, Pontificia Universidad Católica de Chile, Santiago, Chile, ⁸Hans Fischer Senior Fellow Award, Institute for Advanced Study at Technical University of Munich, Munich, Germany

Keywords: Diffusion Acquisition, Data Acquisition

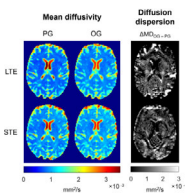
Motivation: Single breath-hold simultaneous T1, T2, and ADC MRF allows comprehensive tissue characterization in a single scan. However, this technique has not been demonstrated at 0.55T.

Goal(s): Investigate the feasibility of T1, T2, and ADC MRF sequence for simultaneous T1, T2, and ADC mapping at 0.55T taking full advantage of the low-field scanner hardware.

Approach: The proposed approach uses a bSSFP radial sequence with varying IR, T2-preparation, and optimized ADC-preparation pulses over 16 heartbeats. Experiments were performed on phantoms and compared with spin-echo references.

Results: T1, T2, and ADC MRF at 0.55T was tested in a phantom, showing excellent agreement with reference values.

Impact: Simultaneous quantification of T1, T2, and ADC is feasible with the proposed MRF sequence in a single breathhold, allowing for a more comprehensive tissue characterization through co-registered multiparametric imaging at 0.55T with a low-performance gradient system.



Spherical tensor diffusion encoding with spectral specificity and isotropy.

Eric S. Michael¹, Runpu Hao¹, Franciszek Hennel¹, and Klaas P. Pruessmann¹

¹Institute for Biomedical Engineering, ETH Zurich and University of Zurich, Zurich, Switzerland

Keywords: Diffusion Acquisition, New Signal Preparation Schemes, Spherical b-tensor encoding, oscillating gradient diffusion encoding


Motivation: Lack of spectral selectivity in spherical tensor diffusion encoding impairs the specificity of the measurement.

Goal(s): The goal of this work was to design diffusion gradient waveforms yielding a spherical b-tensor with frequency-specific and isotropic spectral projections.

Approach: Gradient waveform designs derived from oscillating gradient diffusion methodology were conceived by shifting and overlapping cosine-modulated trapezoidal oscillations along the three coordinate axes to achieve orthonormality of the b-tensor.

Results: The proposed gradient waveforms achieved frequency-specific and isotropic diffusion encoding, permitting frequency-dependent diffusion measurements in the in vivo human brain in the same manner as is conventionally performed using multidirectional linear tensor diffusion encoding.

Impact: The proposed diffusion gradient waveforms for spectrally specific and isotropic spherical tensor encoding offer selective frequency measurements that can isolate the signatures of time-dependent diffusion, thereby enabling the study of diffusion dispersion in the framework of tensor-valued encoding.



Time-dependent DW-MRS to probe lactate compartmentation in Huntington's disease mouse model

Eloïse Mougel¹, Marco Palombo^{2,3}, and Julien Valette¹

¹Université Paris-Saclay, CEA, CNRS, MIRCen, Laboratoire des Maladies Neurodégénératives, Fontenay-aux-Roses, France,

²Cardiff University Brain Research Imaging Centre (CUBRIC), School of Psychology, Cardiff University, Cardiff, United

Kingdom, ³School of Computer Science and Informatics, Cardiff University, Cardiff, United Kingdom

Keywords: Microstructure, Rare disease

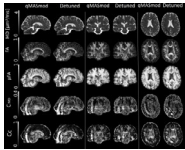
Motivation: In the healthy brain, lactate compartmentation and exchange are crucial for neurotransmission. In Huntington's disease (HD), lactate metabolism appears to be impaired, but lactate compartmentation is unknown.

Goal(s): To assess lactate compartmentation between intracellular and extracellular spaces under pathological conditions *in vivo*.

Approach: Using time-dependent DW-MRS, which may probe lactate exchange and compartmentation, we measured diffusivity and kurtosis in a cohort of zQ175 mice, a model of HD, versus control mice at 3, 6 and 12 months.

Results: Results suggest a larger extracellular fraction in zQ175 mice at 12 months, while no other microstructural changes would be measurable using DW-MRS.

Impact: DW-MRS allows probing brain lactate compartmentation, thus unravelling some crucial aspect of lactate metabolism. Results suggest that, while no microstructural alteration can be observed in the zQ175 mouse model of Huntington's disease, impaired lactate compartmentation is detected with DW-MRS.



Tensor-valued encoded diffusion MRI with spiral readout for whole-brain mapping of microscopic fractional anisotropy

Svenja Niesen¹, Marten Veldmann¹, and Tony Stöcker^{1,2}

¹MR Physics, Deutsches Zentrum für Neurodegenerative Erkrankungen e.V., Bonn, Germany, ²Department of Physics & Astronomy, University of Bonn, Bonn, Germany

Keywords: Microstructure, Diffusion/other diffusion imaging techniques, Tensor-valued encoding, Spiral imaging

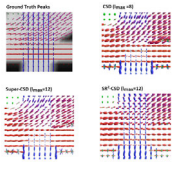
Motivation: Improvement of the quantification of the microstructure in the human brain with tensor-valued encoded diffusion MRI.

Goal(s): Obtain whole-brain macro- and microscopic diffusion tensor distribution metrics using spiral k-space trajectories at 7T.

Approach: Two diffusion-weighted sequences realizing the QTI approach were designed with Pulseseq. They were compared to each other and to an additionally acquired DTI sequence including a ROI analysis.

Results: Accurate metric maps were obtained which are in accordance with the literature and DTI values.

Impact: Combining a multiband spiral sequence with advanced diffusion weighting enables fast whole-brain mapping of microscopic fractional anisotropy in 11-12 minutes.



Spatially Regularized Super-Resolved Constrained Spherical Deconvolution (SR2-CSD) of diffusion MRI data

Ekin Taskin¹, Juan Luis Villarreal Haro¹, Gabriel Girard^{1,2}, Eleftherios Garyfallidis³, Jean-Philippe Thiran^{1,4,5}, and Erick Jorge Canales-Rodriguez¹

¹Signal Processing Laboratory 5 (LTS5), École Polytechnique Fédérale de Lausanne (EPFL), Lausanne, Switzerland,

²Department of Computer Science, Université de Sherbrooke, Sherbrooke, QC, Canada, ³Intelligent Systems Engineering, Indiana University Bloomington, Bloomington, IN, United States, ⁴CIBM, Center for Biomedical Imaging, Lausanne, Switzerland, ⁵Radiology Department, Centre Hospitalier Universitaire Vaudois and University of Lausanne, Lausanne, Switzerland

Keywords: Microstructure, White Matter, Spherical Deconvolution, Spatial Regularization

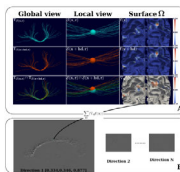
Motivation: Constrained Spherical Deconvolution (CSD) is a state-of-the-art method for estimating the fiber orientation distribution function (fODF) in white matter from diffusion MRI data. However, CSD faces limitations in resolving fiber crossings with small inter-fiber angles when using low spherical harmonic order and produces noisy fODFs when using high order.

Goal(s): This study aims to improve the stability and angular resolution of fODFs from CSD.

Approach: We extend the CSD estimation framework by including a spatial regularization term that promotes fiber continuity, using a J-invariant auto-calibrated total variation denoiser.

Results: The proposed method enhances fiber crossing estimation and reduces spurious fibers.

Impact: The improved stability of the proposed method enables the utilization of higher spherical harmonic orders, with a superior ability to solve complex fiber crossings. This work has the potential to increase the accuracy of fiber-tracking algorithms and brain connectivity estimations.



Studying topographic organization of the brain with directional derivatives of connectivity.

Simona Leseri^{1,2} and Dogu Baran Aydogan^{1,3}

¹University of Eastern Finland, Kuopio, Finland, ²University of Helsinki, Helsinki, Finland, ³Aalto University, Espoo, Finland

Keywords: Tractography, Tractography & Fibre Modelling

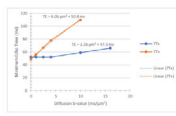
Motivation: The currently available tools to describe changes in structural connectivity preclude an in-depth topography study of the brain's white matter. We sought to quantify the degree of change in structural connectivity through the mathematical notion of directional derivatives.

Goal(s): To define and compute the directional derivatives of tractograms.

Approach: We defined a measure of connectivity at a point in the brain, that is expressed on the brain's surface. By using numerical differentiation, we computed directional derivatives of connectivity.

Results: Our directional derivative method allows a comprehensive topographic study of the brain and highlights potential topographic patterns in structural organization.

Impact: Directional derivatives quantify connectivity changes, enabling systematic topographic study of the brain. The computational neuroimaging tool developed may aid in neurosurgical planning, precise brain stimulation, and biomarkers identification. This versatility may contribute significantly to both neuroscience research and clinical practice.



High b-value in vivo Whole-brain Diffusion MRI at 7T with a High-performance Gradient System

Yi-Hang Tung¹, Hendrik Mattern^{1,2,3}, and Oliver Speck^{1,2,3,4}

¹Department of Biomedical Magnetic Resonance, Institute for Physics, Otto von Guericke University Magdeburg, Magdeburg, Germany, ²German Center for Neurodegenerative Diseases (DZNE), Magdeburg, Germany, ³Center for Behavioral Brain Sciences (CBBS), Magdeburg, Germany, ⁴Leibniz Institute for Neurobiology (LIN), Magdeburg, Germany

Keywords: Diffusion Acquisition, Challenges

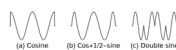
Motivation: Probing brain microstructure with high-b-value brain diffusion imaging was mainly performed at 3T. At higher field strength, the long echo times prohibited a significant SNR boost over 3T. At 7T, a high-performance gradient allows much shorter echo times and harvesting of the field-related signal gain.

Goal(s): Determine SNR and explore feasibility of high b-value DWI.

Approach: The SNR was measured in high b-value DWI at whole-body and high-performance 7T scanners.

Results: The SNR improvement on the high-performance 7T is 2.76 ± 0.12 and 1.73 ± 0.05 compared to the whole-body 7T and high-performance Connectome 3T respectively, allowing even higher spatial resolution and higher b-value imaging.

Impact: The shortcoming of 7T for high b-value diffusion MRI can be overcome when leveraging a high-performance gradient system, effectively reducing scan time 7.6-fold compared to a whole-body 7T scanner. This enables the next generation of diffusion imaging.



High-frequency asymptotic behaviour of the apparent diffusion coefficient measured with approximate cosinusoidal gradient waveforms

Jeff Kershaw¹ and Takayuki Obata¹

¹Applied MRI Research, National Institute of Radiological Sciences, QST, Chiba, Japan

Keywords: Diffusion Acquisition, Diffusion/other diffusion imaging techniques, oscillating gradient, OGSE, universality, asymptotic limit, high frequency

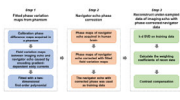
Motivation: Existing theory for OGSE-DWI has been developed under the assumption of an ideal cosinusoidal gradient waveform, but it is impossible to implement such a waveform in practice.

Goal(s): The purpose of this work was to investigate how the high-frequency asymptotic behaviour of the ADC is affected when an approximate cosinusoidal waveform is used for OGSE-DWI measurements.

Approach: A theoretical study was performed that derived the asymptotic behaviour of the ADC from first principles for three MPG waveforms.

Results: The difference in predicted behaviour between an approximate cosinusoidal waveform and an ideal waveform may be important when making precise measurements of the surface-to-volume ratio.

Impact: The microstructure of a complex medium can be characterised by measuring the high-frequency limit of the ADC with OGSE-DWI. However, it is important to understand how the limitations of the gradient hardware affect the interpretation of the data.



Correction of Eddy Current Induced Phase Variations between Imaging and Navigator Echoes in High Angular Resolution Diffusion Imaging

Shihui Chen¹, Liyuan Liang^{1,2}, Chenglang Yuan¹, and Hing-Chiu Chang^{1,2}

¹The Department of Biomedical Engineering, The Chinese University of Hong Kong, Hong Kong, Hong Kong, ²Multi-scale Medical Robotics Center, Hong Kong, Hong Kong

Keywords: Diffusion Reconstruction, Diffusion Tensor Imaging, 2D navigator, eddy current, phase correction, High Angular Resolution Diffusion Imaging

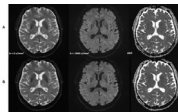
Motivation: The time-varying eddy current caused by diffusion gradient can induce additional phase difference between imaging and navigator echoes. These inaccurate measurements may cause residual artifacts in the subsequently reconstructed data.

Goal(s): This study aims to verify the presence of the eddy-current-induced phase differences in navigator echoes and the phase correction can improve reconstruction performance on in-vivo DTI and HARDI.

Approach: We proposed a procedure to calibrate eddy-current-induced phase difference from a phantom and considered the additional phase difference when using k-d SVD method for reconstruction.

Results: The robust reconstruction performance can be achieved by using phase-corrected navigator data to recover highly-undersampled data.

Impact: This study demonstrates that the eddy-current-induced phase differences between imaging and navigator echoes can be calibrated in advance, and then corrected during the k-d SVD reconstruction method to enable highly-accelerated multi-shot high angular resolution diffusion imaging (HARDI).



Improved readout-segmented EPI using deep learning reconstruction

Wei Liu¹, Omar Darwish¹, Thomas Benkert¹, Elisabeth Weiland¹, and Marcel Dominik Nickel¹

¹Siemens Healthineers AG, Erlangen, Germany

Keywords: Diffusion Reconstruction, Image Reconstruction, Diffusion

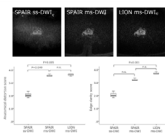
Motivation: We explore the potential of deep learning reconstruction (DLR) to overcome challenges for readout-segmented EPI (rs-EPI), ultimately leading to more efficient and high-quality diffusion-weighted imaging (DWI).

Goal(s): We evaluate DLR's applicability for rs-EPI, aiming to improve image quality, reduce scan durations, and expand rs-EPI's clinical utility.

Approach: We adapted the successful DLR method used in single-shot EPI (ss-EPI) to rs-EPI, conducting experiments for head and prostate diffusion imaging.

Results: Our study demonstrates that DLR can improve image quality and reduce scan times in rs-EPI DWI, promising more efficient clinical imaging and potential applications in diverse diffusion imaging scenarios.

Impact: The successful implementation of DLR in readout-segmented EPI DWI promises accelerated, high-quality diagnostics, directly benefiting clinicians and patients. Furthermore, DLR's potential for diverse diffusion imaging applications opens new research horizons, enhancing the field of MR imaging.



Improved visualization of high b-value prostate diffusion weighted imaging using LIPO-only multi-shot EPI with 2D navigator (LION-IRIS)

Daichi Murayama¹, Masami Yoneyama², Takayuki Sakai³, Iain Ball⁴, and Shigehiro Ochi³

¹Radiology, Eastern Chiba Medical Center, Chiba, Japan, ²Philips Japan, Tokyo, Japan, ³Eastern Chiba Medical Center, Chiba, Japan, ⁴Philips Australia & New Zealand, North Ryde, Australia

Keywords: Diffusion Acquisition, Diffusion/other diffusion imaging techniques, fat suppression

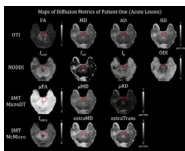
Motivation: One of the drawbacks of IRIS is its low SNR compared with ss-DWI. High b-value DWI improves the ability of prostate cancer detection by increased cancer conspicuity. However, such high b value images may also suffer from decreased SNR.

Goal(s): We hypothesized that using only slice selection gradient reversal (SSGR, LIPO) technique without fat suppression pre-pulse (LIPO-ONLY :LION) could improve the SNR of high b-value IRIS DWI.

Approach: SNR,CR and ADC values were calculated with ROIs placed in internal obturator muscle and prostate region in peripheral zone.

Results: LION IRIS-DWI could provide high quality distortion-free high b-value prostate DWI sufficient SNR.

Impact: The present findings suggest that LION IRISs-DWI sequence demonstrated improved image distortion and blurring compared to ss-DWI, with having sufficient SNR and CR.It may help to further assess the prostate cancer pathology.



Accelerating high-resolution microstructure mapping based on multi-shell diffusion MRI for acute ischemic stroke

Tanxin Dong^{1,2,3}, Jingguo Yan^{1,2,3}, Yutong Cao^{1,2,3}, Quanzhi Feng⁴, Qiyuan Tian⁵, Tong Han⁴, and Qiuyun Fan^{1,2,3}

¹Academy of Medical Engineering and Translational Medicine, Tianjin University, Tianjin, China, ²Tianjin Key Laboratory of Brain Science and Neuroengineering, Tianjin, China, ³Haihe Laboratory of Brain-Computer Interaction and Human-Machine Inteptration, Tianjin, China, ⁴Department of Medical Imaging, Tianjin Huanhu Hospital, Tianjin University, Tianjin, China, ⁵Department of Biomedical Engineering, Tsinghua University, Beijing, China

Keywords: Microstructure, Stroke

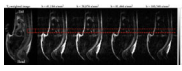
Motivation: The long scanning time of multi-shell diffusion MRI precludes many promising microstructural models to be applied in acute diseases.

Goal(s): To achieve high-resolution microstructural mapping in acute ischemic stroke.

Approach: We fine-tuned the previously proposed DeepHIBRID method with a multi-shell protocol of 5-minute constraint.

Results: 14 maps from 4 diffusion models were obtained, with whole brain coverage and 1.3mm isotropic voxel size. Preliminary results showed decent contrasts to reveal lesions, and the microstructural information indicated was in agreement with the expected pathologies for both chronic and acute cases.

Impact: High-resolution microstructural mapping based on multi-shell diffusion MRI should be now feasible for acute diseases, which is rarely possible either with compromised spatial resolution or brain coverage.



A Novel Ultra-High b-Value Diffusion-Weighted MRI Technique for ALS Diagnosis and Disease Tracking in Mouse Spinal Cords In vivo

Jin Gao¹, Richard Magin², Danilo Erricolo^{2,3}, and Weiguo Li^{2,4}

¹Department of Radiology and Imaging Sciences, Emory University, Atlanta, GA, United States, ²Department of Biomedical Engineering, University of Illinois Chicago, Chicago, IL, United States, ³Department of Electrical and Computer Engineering, University of Illinois Chicago, Chicago, IL, United States, ⁴Research Resources Center, University of Illinois Chicago, Chicago, IL, United States

Keywords: Microstructure, Diffusion/other diffusion imaging techniques


Motivation: Amyotrophic Lateral Sclerosis (ALS) significantly impacts global human health, but its etiology remains unclear.

Goal(s): To develop a novel diffusion-weighted MRI technique to detect early changes in ALS-affected spinal cord *in vivo*.

Approach: We applied ultra-high b-values by using long diffusion time to examine the restricted diffusion in spinal white matter tracts in SOD1^{G93A} mice at ages of 75 and 90 days.

Results: Significant differences were found in diffusion of ventral roots between SOD1^{G93A} mice and control at ages of 75 and 90 days. A shift of diffusion distribution was observed in SOD1^{G93A} mice between 75 and 90 days.

Impact: This *in vivo* study potentially presents a novel view in non-invasive evaluating alterations in spinal cord tissue associated with ALS pathology, thus benefiting investigations related to drug delivery and therapeutic response monitoring of ALS.



Diffusion imaging of the brain at 3T and 7T: a comparison of metrics and reproducibility using a matched acquisition scheme

Thomas Veale¹, Ian B Malone¹, David M Cash¹, Martina F Callaghan², and David L Thomas¹

¹UCL Queen Square Institute of Neurology, University College London, London, United Kingdom, ²Imaging Neuroscience, UCL Queen Square Institute of Neurology, University College London, London, United Kingdom

Keywords: Diffusion Acquisition, High-Field MRI

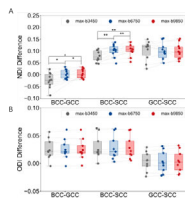
Motivation: The SNR benefits of diffusion weighted imaging (DWI) at 7T are unclear. Previous studies comparing across field strengths involved varying scanner hardware and acquisition protocols.

Goal(s): To characterise the spatial SNR differences of brain DWI at 3T and 7T.

Approach: Participants were scanned back-to-back on 3T and 7T scanners with well-matched hardware and acquisition protocols. SNR and DTI metrics were compared between field strengths in white and grey matter regions.

Results: SNR is higher at 7T in WM but comparable or lower in GM. DTI metrics also vary between field strengths, and fitting error is lower at 7T.

Impact: This study indicates that there is tangible SNR benefit to studying white matter using diffusion-weighted imaging at 7T in humans. However, we caution researchers when studying grey matter structures, especially in the pallidum and close to the air-tissue interfaces.



Exploring Brain Microstructure with Ultra-high b-values Diffusion MRI: A NODDI Model Comparison

Paween Wongkornchaovalit^{1,2}, Junye Yao^{1,2}, Bo Dong^{1,2}, Jianhui Zhong³, Hui Zhang⁴, and Hongjian He^{1,5,6}

¹Center for Brain Imaging Science and Technology, Zhejiang University, Hangzhou, China, ²College of Biomedical Engineering and Instrument Science, Zhejiang University, Hangzhou, China, ³Department of Imaging Sciences, University of Rochester, Rochester, NY, United States, ⁴Department of Computer Science & Centre for Medical Image Computing, University College London, London, United Kingdom, ⁵School of Physics, Zhejiang University, Hangzhou, China, ⁶State Key Laboratory of Brain-Machine Intelligence, Zhejiang University, Hangzhou, China

Keywords: Microstructure, Data Analysis, Ultra-high b-values, NODDI


Motivation: The benefits of using ultra-high b-values diffusion MRI ($b > 6000 \text{ s/mm}^2$) on characterizing and resolving brain microstructure are still unclear.

Goal(s): To determine if the NODDI metrics computed from ultra-high b-values can help characterizing and providing more biological information related to brain microstructure.

Approach: NODDI metrics are compared between different b-schemes, and between the corpus callosum and hippocampal subfields.

Results: NODDI metrics computed with ultra-high b-value data can help characterize different subfields. Higher NDI and ODI differences in the corpus callosum and hippocampal subfields are observed with larger b-values.

Impact: We show that NODDI models can work with ultra-high b-values and help characterizing and providing more biological information related to brain microstructure.



Echo-time dependence of microscopic fractional anisotropy using single-shot spiral encoding and free water elimination

Farah Mushtaha^{1,2}, Paul Dubovan^{1,2}, Ali Khan^{1,2,3,4,5}, and Corey Baron^{1,2,3,4,5}

¹Medical Biophysics, Schulich School of Medicine and Dentistry, Western University, London, ON, Canada, ²Centre for Functional and Metabolic Mapping, Robarts Research Institute, Western University, London, ON, Canada, ³The Brain and Mind Institute, Western University, London, ON, Canada, ⁴School of Biomedical Engineering, Western University, London, ON, Canada, ⁵Imaging Research Laboratories, Robarts Research Institute, Western University, London, ON, Canada

Keywords: Microstructure, Diffusion/other diffusion imaging techniques

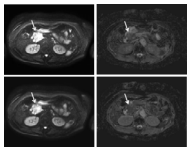
Motivation: Understand echo time (TE) dependence of microscopic fractional anisotropy (μFA) in white matter (WM), cortical grey matter (GM), and deep GM.

Goal(s): Measure μFA at varying TEs and observe the trends in WM, cortical GM, and deep GM.

Approach: Healthy volunteers were scanned with dMRI at 3T using a spiral imaging sequence with linear tensor encoding and spherical tensor encoding. μFA was calculated with and without free water elimination (FWE).

Results: Linear regression fitting showed a downward trend in μFA in cortical GM and deep GM with increasing TE, both with and without FWE.

Impact: We observed reducing μFA with increasing TE in grey matter for the first time, which was enabled by a spiral readout that greatly reduced the minimum TE ($\sim 20 \text{ ms}$). This TE-dependence can potentially be exploited for improved microstructural modelling.



Diffusion-Weighted Imaging Using Echo Planar Imaging with Compressed SENSE (EPICS) for Pancreatic Protocol MRI: A Multicenter Study

Tetsuro Kaga¹, Yoshifumi Noda¹, Masashi Asano¹, Nobuyuki Kawai¹, Kimihiro Kajita², Yukiko Takai¹, Fumitaka Ejima³, Akio Ito¹, Fuminori Hyodo^{1,4}, Hiroki Kato¹, Yoshihiko Fukukura⁵, and Masayuki Matsuo¹

¹Department of Radiology, Gifu University, Gifu, Japan, ²Department of Radiology Services, Gifu University Hospital, Gifu, Japan, ³Department of Radiology, Kagoshima University Graduate School of Medical and Dental Sciences, Kagoshima, Japan, ⁴Center for One Medicine Innovative Translational Research, Institute for Advanced Study, Gifu University, Gifu, Japan, ⁵Department of Radiology, Kawasaki Medical School, Kurashiki, Japan

Keywords: Diffusion Reconstruction, Pancreas

Motivation: To prove the feasibility of DWI using echo planar imaging with Compressed SENSE (EPICS-DWI).

Goal(s): Are the images and values obtained by EPICS-DWI reliable?

Approach: Taking both conventional DWI using parallel imaging (PI-DWI) and EPICS-DWI images for the same patient with untreated PDAC within the same examination and compare them.

Results: The ADC value of PDAC did not differ between PI-DWI and EPICS-DWI. EPICS-DWI can improve the qualitative overall image quality and PDAC-to-pancreas CNR compared to PI-DWI. The qualitative PDAC conspicuity was comparable between PI-DWI and EPICS-DWI.

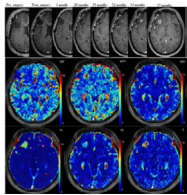
Impact: EPICS could improve image quality of high-b value DWI images without any worries about significant changing of ADC values of PDAC.

Glioma

Exhibition Hall (Hall 403)

Thursday 13:45 - 14:45

5116



Differential Diagnosis between Tumor Recurrence and Treatment Response using Advanced Tracer Kinetic Model in Glioblastoma

Jianan Zhou¹, Zujun Hou², Zhengyang Zhu¹, Chuanshuai Tian¹, Bing Zhang¹, and Xin Zhang¹

¹Department of Radiology, The Affiliated Drum Tower Hospital of Nanjing University Medical School, Nanjing, China, ²Jiangsu Key Laboratory of Medical Optics, Suzhou Institute of Biomedical Engineering and Technology, Chinese Academy of Sciences, Suzhou, China., Suzhou, China

Keywords: Tumors (Post-Treatment), Tumor, Glioblastoma, Tumor recurrent, Treatment-related response, Distributed parameter model, Dynamic contrast-enhanced

Motivation: It is challenging to differentiate recurrent tumor from treatment response in glioblastoma.

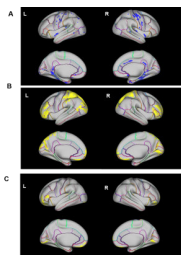
Goal(s): This study explored the issue using an advanced tracer kinetic model.

Approach: Glioblastoma patients were examined using dynamic contrast-enhanced MRI and stratified into recurrent and treatment-related group based on histopathological results. Imaging data were analyzed using distributed parameter model.

Results: Blood flow in lesion was significantly higher and permeability in peritumoral edema was significantly smaller in recurrent than in treatment-related group ($p=0.002$, 0.023). Combining two parameters together, diagnostic performance was attained at AUC (area under ROC curve) 0.93. AUC of extended-Tofts model was 0.89.

Impact: With separate account of blood flow and vessel-wall permeability, advanced tracer kinetic model allowed more precise modeling the feature of tissue microenvironment, which could shed light on the difference between recurrent tumor and treatment-related response in glioblastoma.

5117



Cortical mapping provide insights into whole-brain tumor burden in diffuse midline glioma

Simin Zhang¹, Qiang Yue¹, and Qiyong Gong¹

¹Huaxi MR Research Center (HMRRC), Department of Radiology, West China Hospital of Sichuan University, Chengdu, China, Chengdu, China

Keywords: Tumors (Pre-Treatment), Neuro, diffuse midline glioma; H3K27M altered; whole-brain tumor burden; cortical myelin content; cortical thickness;

Motivation: Diffuse midline glioma (DMG) represents a systemic disease due to its ability to disseminate tumor cells throughout the whole brain. Current imaging techniques, however, provide information only about the main tumor and its immediate surroundings.

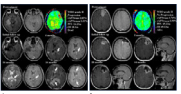
Goal(s): We employed comprehensive cortical mapping to gain insights into the individual tumor burden across whole-brain using structural MRI.

Approach: Cortical thickness and myelin content was calculated from participants using Human Connectome Project pipeline.

Results: DMG has the capacity to induce cortical thickness compensation while concurrently leading to cortical demyelination in numerous non-lesional regions. Notably, DMG harboring H3K27M altered exhibited specific cortical myelin and thickness reorganization patterns.

Impact: These findings may open up the possibility of tailoring treatment strategies to the individual disease severity and distribution within the patient's brain, potentially enhancing the effectiveness of both current and future treatment approaches.

5118



Imaging phenotypes-based quantification of intratumor heterogeneity using APTw for predicting progression in lower grade glioma.

Yaoming Qu¹, Xiaochan Ou², Andong Ma¹, and Zhibo Wen¹

¹Zhujiang Hospital of Southern Medical University, Guangzhou, China, ²The first people's hospital of Foshan, Foshan, China

Keywords: Tumors (Pre-Treatment), CEST & MT

Motivation: In the setting of lower grade glioma follow heterogeneity of prognosis, it is currently necessitating risk stratification.

Goal(s): To determine the predictive ability of amide proton transfer-weighted (APTw) imaging phenotypes in lower grade glioma.

Approach: The ability of APTw phenotypes to PFS was evaluated using biomarker threshold model, The predictive model was trained on 67%, and tested on the remainder.

Results: APTw imaging phenotypes can predict the progression free survival of lower grade gliomas.

Impact: The independent and additional prognostic value of imaging phenotypes in APTw suggests that APTw imaging phenotypes can provide a noninvasive characterization of tumor cellular, proliferation and invasiveness to augment personalized prognosis and treatment in patients with lower grade glioma.

Model	Performance
Extofts	Best performance in predicting IDH mutation
ATH	Best performance in predicting P53 mutation
DP	Best performance in predicting CDKN2A/B homozygous deletion

Different Tracer Kinetic Models in predicting key molecular marker in adult diffuse Gliomas

Zhengyang Zhu¹, Zujun Hou², Jianan Zhou¹, Huiquan Yang¹, Chuanshuai Tian¹, Xin Zhang¹, and Bing Zhang¹

¹Department of Radiology, The Affiliated Drum Tower Hospital of Nanjing University Medical School, Nanjing, China, ²Jiangsu Key Laboratory of Medical Optics, Suzhou Institute of Biomedical Engineering and Technology, Chinese Academy of Sciences, Suzhou, China

Keywords: Tumors (Pre-Treatment), Tumor, DCE-MRI, IDH, Glioma, P53, CDKN2A/B

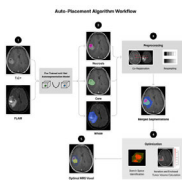
Motivation: IDH, P53 and CDKN2A/2B are key molecular markers for adult diffuse gliomas.

Goal(s): This study aimed to compare values of conventional and advanced tracer kinetic models based on dynamic contrast enhanced (DCE)-MRI in predicting IDH, P53 and CDKN2A/B status in glioma patients.

Approach: Patients diagnosed as adult diffuse gliomas were examined using dynamic contrast-enhanced MRI. Imaging data were analyzed using tracer kinetic models.

Results: Extofts model attained best performance in predicting IDH mutation. ATH model attained best performance in predicting P53 mutation. DP model attained best performance in predicting CDKN2A/B homozygous deletion.

Impact: Different Tracer Kinetic Models have illustrated excellent performance in predicting different molecular markers in glioma patients.



Automated MR Spectroscopy single-voxel placement in suspected diffuse glioma based on tumor biology

Saahil Chadha^{1,2,3}, Sarah M Jacobs^{1,4}, Tal Zeevi¹, Niklas Tillmanns¹, Sara Merkaçj^{1,5}, Jan Lost¹, MingDe Lin^{1,6}, Khaled Bousabarah⁶, Wolfgang Holler⁶, Fatima Memon¹, Sanjay Aneja^{2,3}, and Mariam S Aboian¹

¹Department of Radiology and Biomedical Imaging, Yale School of Medicine, New Haven, CT, United States, ²Department of Therapeutic Radiology, Yale School of Medicine, New Haven, CT, United States, ³Center for Outcomes Research and Evaluation (CORE), Yale School of Medicine, New Haven, CT, United States, ⁴Center for Image Sciences, University Medical Center Utrecht, Utrecht, Netherlands, ⁵University of Ulm, Ulm, Germany, ⁶Visage Imaging GmbH, Berlin, Germany

Keywords: Tumors (Pre-Treatment), Software Tools, AI/ML Software; Brain; Machine Learning/Artificial Intelligence; Neuro; Spectroscopy; Tumors

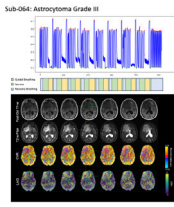
Motivation: Acquiring single-voxel Magnetic Resonance Spectroscopy (MRS) data in clinic currently involves manual voxel placement by technicians without the time capacity to review tumor biology in detail, leading to poor-quality spectra.

Goal(s): To achieve consistent and accurate single-voxel placement to minimize variability in metabolite quantification.

Approach: We developed an auto-placement algorithm that identifies an optimized MRS single-voxel position and rotation based on tumor biology (tumor core, necrosis, and edema) and outputs this voxel as a mask on MR Imaging.

Results: Performance of the automated MRS single-voxel placement rivals clinical placement and integrates with an existing clinically implemented automated brain tumor segmentation workflow.

Impact: Our new algorithm will assist radiology technicians in reliably placing MR Spectroscopy single-voxels with accuracy that rivals clinical placement. This is a primary need for non-invasive diagnosis and management of diffuse gliomas.



Mapping cerebrovascular reactivity and vascular lag in gliomas with multi-echo BOLD fMRI and breath-holding
Cristina Comella-Luengo¹, Ileana Quiñones¹, Santiago Gil-Robles², Iñigo Pomposo², Manuel Carreiras¹, and César Caballero-Gaudes¹

¹Basque Center of Cognition, Brain and Language, San Sebastian, Spain, ²BioCruces Research Institute, Bilbao, Spain

Keywords: Tumors (Pre-Treatment), Tumor, fMRI, Cerebrovascular reactivity, Multi-echo, Glioma

Motivation: Cerebrovascular reactivity (CVR) with BOLD fMRI during breath-holding offers a feasible technique for examining neurovascular alterations in tumor-affected regions. However, this examination may have reduced accuracy due to breath-hold-induced artifacts.

Goal(s): This study explores the use of multi-echo fMRI techniques to improve the accuracy and reliability of CVR mapping and vascular lag estimation in glioma patients.

Approach: We employed optimized ME-fMRI procedures in 21 patients with diverse glioma characteristics, including lagged regression analysis, nuisance modeling with ME-ICA.

Results: Our protocol robustly mapped reductions in CVR in all patients, and showed the vascular lag provides differential clinically valuable insights into tumor and peritumoral areas.

Impact: This work presents a robust and feasible multi-echo fMRI protocol with breath-holds that enhances cerebrovascular reactivity (CVR) mapping by obtaining complementary vascular lag maps, which offer critical insights into vascular delay and vasodilatory dynamics in glioma patients
